

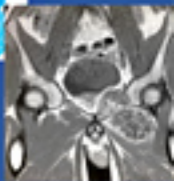A-Z of

**Musculoskeletal and
Trauma Radiology**



**James R. D. Murray
Erskine J. Holmes
Rakesh R. Misra**



CAMBRIDGE

Medicine

CAMBRIDGE

www.cambridge.org/9780521700139

This page intentionally left blank

A-Z of Musculoskeletal and Trauma Radiology

A–Z of Musculoskeletal and Trauma Radiology

James R. D. Murray, MA, FRCS (Orth & Tr)

Consultant Orthopaedic Surgeon, Avon Orthopaedic Centre
North Bristol NHS Trust, Bristol and Senior Clinical Lecturer
University of Bristol

Erskine J. Holmes, MRCS, FCEM

Consultant in Emergency Medicine, Heatherwood and Wexham
Park Hospitals NHS Foundation Trust

Rakesh R. Misra, BSc (Hons), FRCS (Eng.), FRCR

Consultant Radiologist, Wycombe Hospital
Buckinghamshire Hospitals NHS Trust

Editor

R. R. Misra



CAMBRIDGE
UNIVERSITY PRESS

CAMBRIDGE UNIVERSITY PRESS

Cambridge, New York, Melbourne, Madrid, Cape Town, Singapore, São Paulo

Cambridge University Press

The Edinburgh Building, Cambridge CB2 8RU, UK

Published in the United States of America by Cambridge University Press, New York

www.cambridge.org

Information on this title: www.cambridge.org/9780521700139

© J. Murray, E. J. Holmes and R. R. Misra 2008

This publication is in copyright. Subject to statutory exception and to the provision of relevant collective licensing agreements, no reproduction of any part may take place without the written permission of Cambridge University Press.

First published in print format 2008

ISBN-13 978-0-511-40886-1 eBook (EBL)

ISBN-13 978-0-521-70013-9 paperback

Cambridge University Press has no responsibility for the persistence or accuracy of urls for external or third-party internet websites referred to in this publication, and does not guarantee that any content on such websites is, or will remain, accurate or appropriate.

Every effort has been made in preparing this publication to provide accurate and up-to-date information which is in accord with accepted standards and practice at the time of publication. Although case histories are drawn from actual cases, every effort has been made to disguise the identities of the individuals involved. Nevertheless, the authors, editors and publishers can make no warranties that the information contained herein is totally free from error, not least because clinical standards are constantly changing through research and regulation. The authors, editors and publishers therefore disclaim all liability for direct or consequential damages resulting from the use of material contained in this publication. Readers are strongly advised to pay careful attention to information provided by the manufacturer of any drugs or equipment that they plan to use.

With all my love to my wife, Gemma, and my children,
Tom and Emily, for allowing me the time to write this
book. **J. R. D. M**

Dedicated to my wonderful son Alex. **E. J. H**

Dedicated to my four inspirational children, Rohan,
Ela, Krishan and Maya. **R. R. M**

CONTENTS

<i>Acknowledgements</i>	page xi
<i>Preface</i>	xiii
<i>List of abbreviations</i>	xiv
Section I Musculoskeletal radiology	1
Achilles tendonopathy/rupture	3
Aneurysmal bone cysts	7
Ankylosing spondylitis	10
Avascular necrosis – osteonecrosis	13
Femoral-head osteonecrosis	17
Kienböck’s disease	19
Back pain – including spondylolisthesis/spondylolysis	21
Bone cysts	27
Bone infarcts (medullary)	29
Bone islands	29
Charcot joint (neuropathic joint)	34
Complex regional-pain syndrome	36
Crystal deposition disorders	38
Developmental dysplasia of the hip (DDH)	41
Discitis and vertebral osteomyelitis	45
Disc prolapse – PID – ‘slipped discs’ and sciatica	49
Diffuse idiopathic skeletal hyperostosis (DISH)	53
Dysplasia – developmental disorders	55
Enthesopathy	60
Gout	62
Haemophilia	65
Hyperparathyroidism	68
Hypertrophic pulmonary osteoarthropathy	71
Irritable hip/transient synovitis	74
Juvenile idiopathic arthritis	76

Langerhans-cell histiocytosis	78
Lymphoma of bone	81
Metastases to bone	83
Multiple myeloma	87
Myositis ossificans	89
Non-accidental injury	92
Osteoarthrosis – osteoarthritis	96
Osteochondroses	99
Osteomyelitis (acute)	102
Osteoporosis	105
Paget's disease	108
Perthes disease	113
Pigmented villonodular synovitis (PVNS)	115
Psoriatic arthropathy	119
Renal osteodystrophy (including osteomalacia)	122
Rheumatoid arthritis	124
Rickets	127
Rotator-cuff disease	129
Scoliosis	133
Scheuermann's disease	137
Septic arthritis – native and prosthetic joints	139
Sickle-cell anaemia	143
Slipped upper femoral epiphysis (SUFE)	149
Tendinopathy – tendonitis	151
Tuberculosis	154
Tumours of bone (benign and malignant)	159
Section II Trauma radiology	177
General trauma/spine	179
ATLS – Advanced Trauma Life Support	179
Acetabular fractures	181
Aortic rupture	184
Cervical spine injury	186
Flail chest	195
Haemothorax	197

Open fractures	199
Pelvic fracture	202
Peri-physeal injury	205
Pneumothorax	207
Rib/sternal fracture	210
Skull fracture	212
Thoraco-lumbar spine fractures	215
Upper limb	221
Acromioclavicular joint injury	221
Carpal dislocation and instability	223
Clavicular fractures	228
Elbow injuries and distal humeral fractures	230
Hand injuries – general principles	234
Hand injuries – specific examples	237
Thumb metacarpal fractures	248
Humerus fracture – proximal fractures	251
Humerus fracture – shaft fractures	254
Humerus fracture – supracondylar fractures – paediatric	256
Radius fracture – head of radius fractures	258
Radius fracture – shaft fractures	262
Galeazzi fracture dislocation	264
Radius fracture – distal radial fractures	266
Colles' fracture	266
Related wrist fractures	269
Smith's fracture	269
Barton's fracture	269
Chauffeur's (Hutchinson) fracture	269
Greenstick fracture	269
SH-II epiphyseal injury	269
Scaphoid fracture	272
Scapular fracture	275
Shoulder dislocation	278
Ulna fracture – proximal and olecranon fractures	282
Ulna fracture – shaft fractures	284
Monteggia fracture dislocation	286

Lower limb	289
Accessory ossicles of the foot	289
Ankle fractures	292
Bone bruising	297
Calcaneal (Os calcis) fractures	301
Femoral neck fracture	303
Femoral shaft fracture	307
Femoral supracondylar fracture	309
Hip dislocation – traumatic	312
Knee soft-tissue injury	316
Metatarsal fractures – commonly fifth MT base	321
Lisfranc injury	323
Patella fracture	326
Tibial-plateau fracture	329
Tibial-shaft fractures	332
Tibial-plafond (Pilon) fractures	335
Talus fractures/dislocations	338
Tarsal fractures and toe phalangeal injury	341

ACKNOWLEDGEMENTS

Dr Tom Cross, Consultant Sports Medicine Physician, North Sydney Orthopaedic Sports Medicine Centre, Crows Nest, Sydney, Australia

Tom has read and edited the final manuscript from a sports medicine perspective. We are most grateful for his contribution.

The authors would like to thank Dr Richard Hughes, Consultant Radiologist, Buckinghamshire Hospitals NHS Trust, for providing several key images.

A special thank you to the Department of Radiology, Nuffield Orthopaedic Centre NHS Trust, for sourcing several important images in Section 1.

PREFACE

Musculoskeletal radiology is a well-recognised sub-specialty and imaging is fundamental to the practice of modern-day 'musculoskeletal medicine'. The musculoskeletal umbrella includes the disciplines of Orthopaedics, Trauma, Physiotherapy, Rheumatology and Rehabilitation, Emergency Medicine and Sports Medicine and applies to a significant part of the work-load of a primary care physician.

The aim of this book is to link the key facts of a topic with appropriate high-quality imaging; this will aid learning for that particular clinical scenario, prior to clinical examination. It will be valuable for both specialists' teaching, and day-to-day routine clinical practice in the relevant fields.

Emphasis has been placed upon clarity of fundamental points, rather than inclusion of over-expansive detail, and the format of the other titles in the *A to Z* series has been maintained throughout, that is 'Characteristics, Clinical Features, Radiology and Management (where appropriate)'. By keeping to this standard, the reader can turn to the topic required and immediately select 'radiology', for example. The trauma section has been separated for ease of reference.

Readers familiar with the *A to Z of Radiology* series will note that several of the images within the trauma section are duplicated from *A to Z of Emergency Radiology*. The authors do not make apologies for this, as a huge emphasis is placed on providing high-quality reference images, and consequently such images are transcribed across the *A to Z* series.

This book will be a useful aid to medical students, radiographers, radiology trainees, surgeons in training and general and emergency physicians who wish to gain a greater understanding of musculoskeletal and trauma imaging and how it can improve their clinical practice.

J. R. D. M

E. J. H

R. R. M

ABBREVIATIONS

3D	3 dimensional
ABC	Aneurysmal bone cyst
ACI	Autogenous chondrocyte implantation
ACJ	Acromioclavicular joint
ACL	Anterior cruciate ligament
AP	Anteroposterior
ATLS	Advanced trauma life support
AVN	Avascular necrosis
BCP	Basic calcium phosphate
CDH	Congenital dislocation of the hip
CES	Cauda-equina syndrome
CMC	Carpometacarpal
CPPD	Calcium pyrophosphate dihydrate deposition
CRP	C reactive protein
CRPS	Complex regional pain syndrome
CXR	Chest X-ray
DCS	Dynamic condylar screw
DDH	Developmental dysplasia of the hip
DEXA	Dual energy X-ray absorptiometry
DHS	Dynamic hip screw
DIP	Distal interphalangeal
DIPJ	Distal interphalangeal joint
DISH	Diffuse idiopathic skeletal hyperostosis
DISI	Dorsal intercalated segmental instability
DIY	Do it yourself
DRUJ	Distal radioulnar joint
DVT	Deep-vein thrombosis
ECG	Electrocardiogram
ESR	Erythrocyte sedimentation rate
F	Female
GA	General anaesthetic
GHJ	Glenohumeral joint
GT	Greater trochanter
HA	Calcium hydroxyapatite
HIV	Human immunodeficiency virus
HLA	Human leukocyte antigen
HPOA	Hypertrophic pulmonary osteoarthropathy
HPT	Hyperparathyroidism
IMN	Intramedullary nail
IMTJ	Intermetatarsal joint

JBJS	<i>Journal of Bone and Joint Surgery</i>
JCA	Juvenile chronic arthritis
LCL	Lateral collateral ligament
LISS [®]	Less invasive stabilisation system
LT	Lesser trochanter
M	Male
MCL	Medial collateral ligament
MCP	Metacarpophalangeal
MR	Magnetic resonance
MRI	Magnetic-resonance imaging
MT	Metatarsal
MTP	Metatarsophalangeal
MTPJ	Metatarsophalangeal joint
MUA	Manipulation under anaesthesia
NGT	Nasogastric tube
NSAID	Non-steroidal anti-inflammatory drugs
OA	Osteoarthritis
OO	Osteoid osteoma
ORIF	Open reduction and internal fixation
PCL	Posterior cruciate ligament
PID	Prolapsed intervertebral disc
PIP	Proximal interphalangeal
POP	Plaster of Paris
PA	Posteroanterior
PRIF	Percutaneous reduction and internal fixation
PVNS	Pigmented villonodular synovitis
RDA	Radial digital artery
ROM	Range of movement
RSD	Reflex sympathetic dystrophy
RTA	Road traffic accident
SCFE	Slipped capital femoral epiphysis
SIJ	Sacroiliac joint
SLE	Systemic lupus erythematosus
SOMI	Sterno-occipito-mandibular immobilisation
SONK	Spontaneous osteonecrosis of the knee
STIR	Short tau inversion recovery
SUFE	Slipped upper femoral epiphysis
T1WI	T1 weighted images
T2WI	T2 weighted images
TB	Tuberculosis
TIP	Terminal interphalangeal
TLSO	Thoraco-lumbo-sacral orthosis
TMTJ	Tarsometatarsal joint
TNF	Tumour necrosis factor
UCL	Ulnar collateral ligament
UDA	Ulnar digital artery

Abbreviations

UK	United Kingdom
USS	Ultrasound scan
VISI	Volar intercalated segmental instability
WBC	White blood cell
WCC	White-cell count

**MUSCULOSKELETAL
RADIOLOGY**

SECTION

I

Achilles tendonopathy/rupture

Characteristics

- Describes pathology of the combined tendon of the gastro-soleus complex, which inserts onto the calcaneum.
- Three stages of injury:
 - 1 Paratenonitis.
 - 2 Tendonosis with or without paratenonitis.
 - 3 Rupture – partial or full. A complete tear may be acute or chronic, sometimes with no prior symptoms.

Clinical features

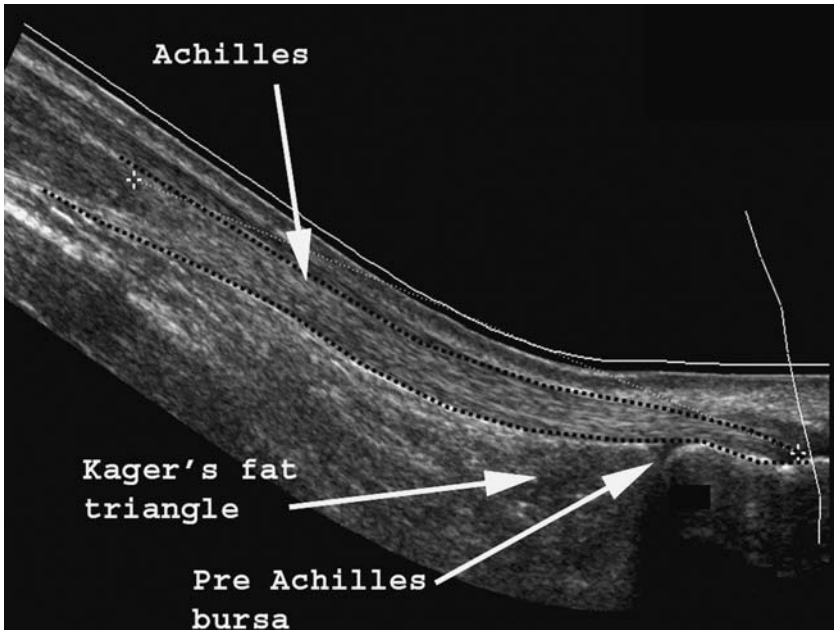
- Relate to the stage of the injury:
 - 1 Localised tenderness proximal to the insertion, and crepitus on ankle movement.
 - 2 Tendonosis \pm paratenonitis. Nodular thickening and degenerative change within the tendon presents as focal thickening within the tendon, which is only tender in the presence of paratenonitis.
 - 3 Rupture – classically a middle-aged patient (M > F) who undergoes a sudden, forceful contraction of gastro-soleus during infrequently performed sporting activity – ‘I thought I was kicked in the back of the leg’. The classic gap may not be palpable, but Simmonds Test will be abnormal in the vast majority of ruptures (>95%).

Radiological features

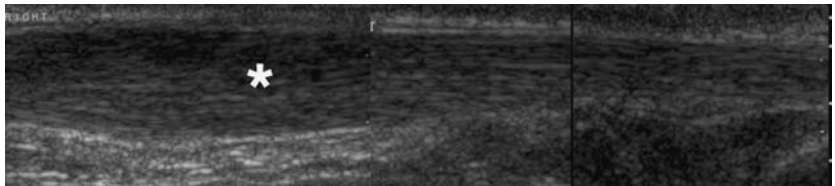
- USS and MRI can be used in the diagnosis of all three stages of Achilles tendonopathy.
 - USS:
 - *Normal tendon*
 - uniform thickness <7 mm.
 - *Tendonosis*
 - fusiform swelling.
 - heterogeneous echo pattern.
 - hypoechoic foci (mucoïd degeneration).
 - In an acute full-thickness tear, in the presence of good clinical signs there is no need for imaging; if there is doubt over partial continuity, then both USS and MRI are diagnostic.

Management

- Stage 1 – NSAIDs, identify/eliminate triggers, stretching (eccentric loading), orthoses to correct any hindfoot malalignment (varo-valgus) and ‘offload’ the tendon by a heel raise.
 - Controversial role for local anaesthetics \pm steroid injection into the paratenon.
 - Operative treatment in the form of tenosynovectomy is only required if the above fails.

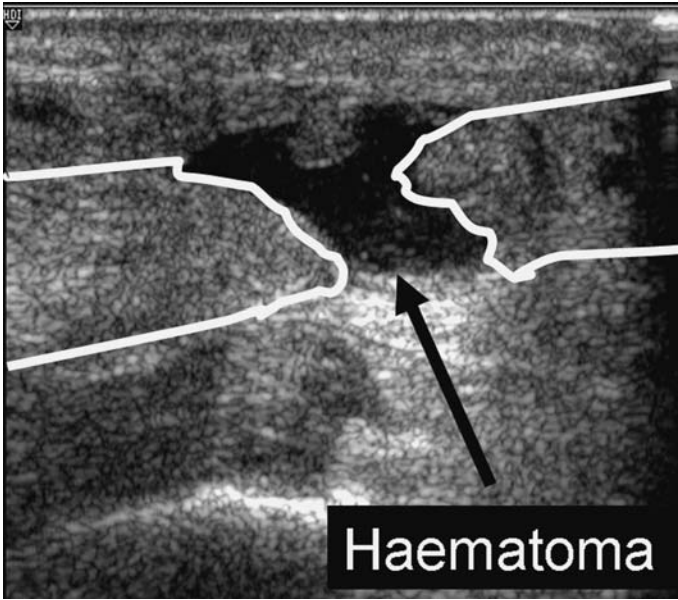


Ultrasound of a normal Achilles tendon.

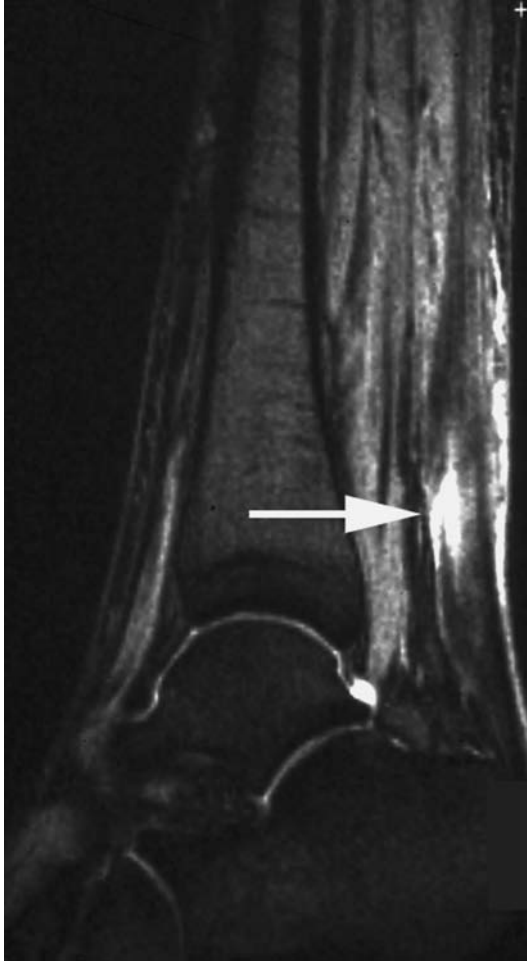


Achilles tendonopathy. Note the fusiform swelling within the proximal tendon (asterisk).

- Stage 2 – In addition to the above, longitudinal tendon opening and excision of central necrotic tissue is performed, to promote healing within the degenerate area.
- Stage 3 – Chronic rupture needs surgical reconstruction. Acute tears can be managed operatively (open or percutaneous repair) or non-operatively by functional bracing or traditional serial casting.



Ultrasound of ruptured Achilles tendon. Note the echo-poor haematoma between the two ends of the ruptured tendon.



Sagittal STIR MRI: High signal within the substance of the Achilles tendon, secondary to a partial rupture (arrow).

Aneurysmal bone cysts

Characteristics

- Can occur at any age. Commonest in 10–30 year olds with the majority arising prior to epiphyseal fusion.
- Any bone may be affected but most commonly occur in long-bone metaphyses, especially the lower limb.
- Aetiology unknown.

Clinical features

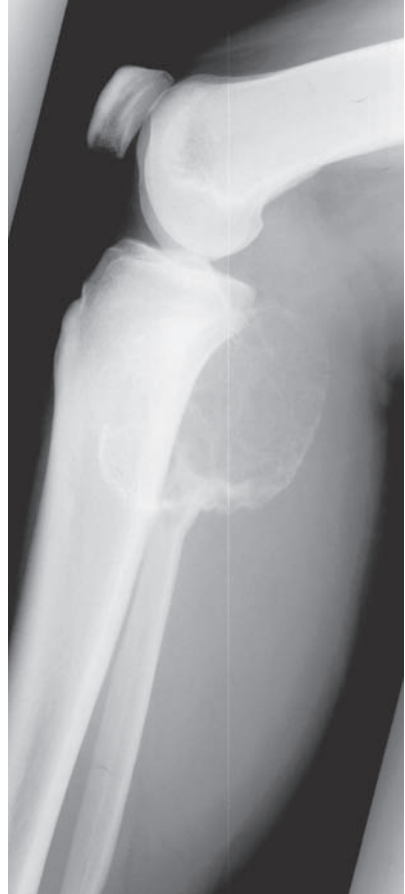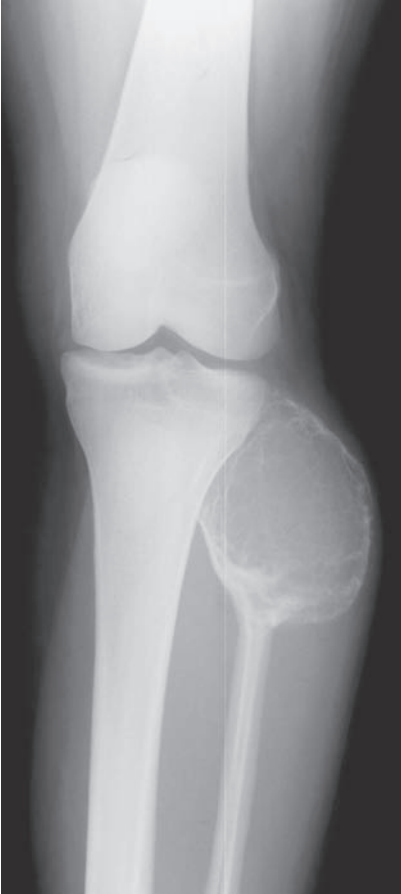- Pain associated with expansile lesions.
- Pathological fractures may occur.
- May be visible or palpable if sufficiently large.

Radiological features

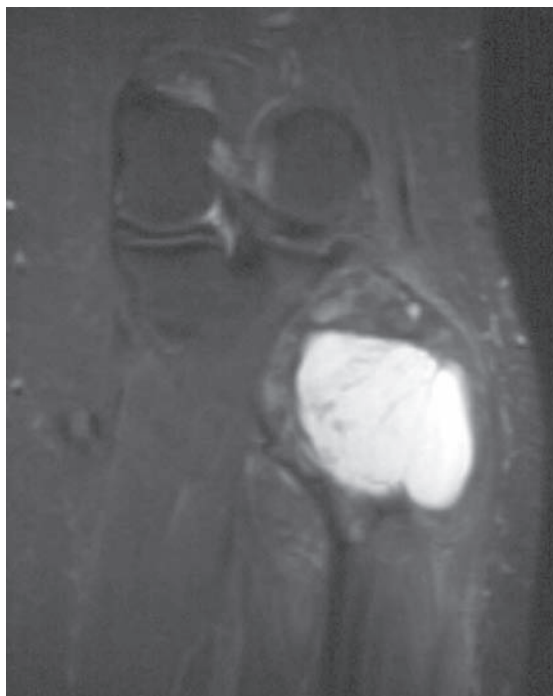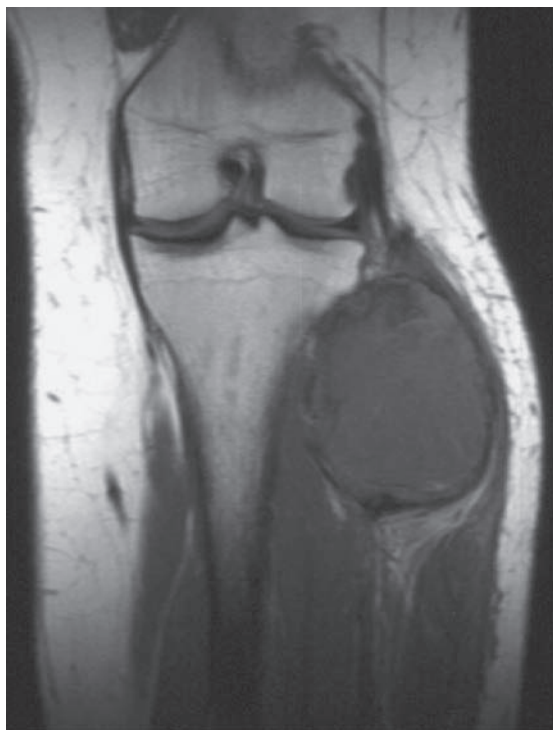- Well-defined radiolucent cyst, often eccentric within bone. Marked ‘soap-bubble’ expansion may be seen.
- Usually trabeculated with a thin intact cortex (narrow transition zone).
- No periosteal reaction (except when fractured).
- Within the spine, posterior elements are more commonly involved.
- May be mistaken for other cyst-like lesions – *see* Bone cysts.
- MRI/CT – fluid levels within cyst due to blood sedimentation (in up to 35%).

Management

- Curettage and bone grafting, or substitute grafting.
- If the ABC recurs, then consider bone cement rather than bone graft in the revision procedure.



Aneurysmal bone cyst: well-defined cyst seen expanding the head of the fibula.



Aneurysmal bone cyst: coronal T1 and STIR MRI. The lesion is isointense on T1 and hyperintense on STIR with a narrow zone of transition.

Ankylosing spondylitis

Characteristics

- Spondyloarthropathy affecting 5/1000 of the Caucasian population – only 10% develop significant symptoms.
- Predominantly a genetic aetiology (>90%) with HLA B27 conferring a relative risk increase of 120, although this is not the only genetic inheritance factor in ankylosing spondylitis.
- Young adults, M : F = 3 : 1.

Clinical features

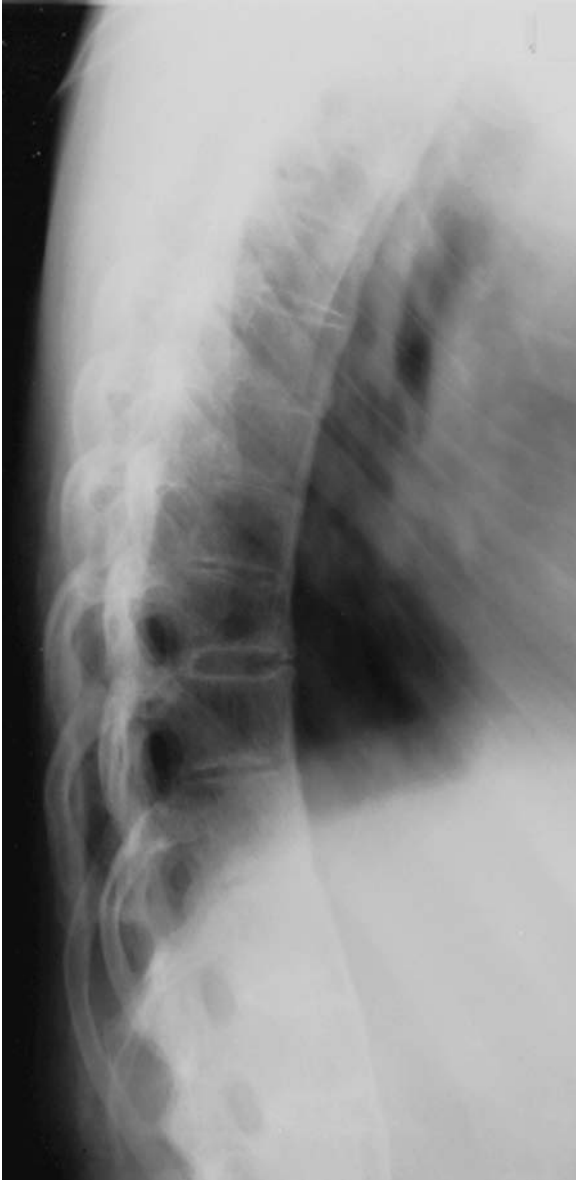- Thoracolumbar and lower back pain with stiffness. Buttock pain with radiation down the posterior thigh but not below the knee.
- Morning stiffness and night pain are common.
- Costochondral/costovertebral pain, sometimes causing respiratory disease.
- Coexistent plantar fasciitis, iritis (30%), Achilles tendonopathy, inflammatory bowel disease (10%), psoriasis (10%) and major-joint involvement (20%). Cardiac problems occur in 1%.
- Progressive lumbar flattening and thoracic kyphosis, in conjunction with soft-tissue flexion contractures of the hip produce the characteristic ‘question mark’ posture.
- Further exacerbation of the thoracic kyphosis may be due to osteoporotic wedge fractures, which are not uncommon.

Radiological features

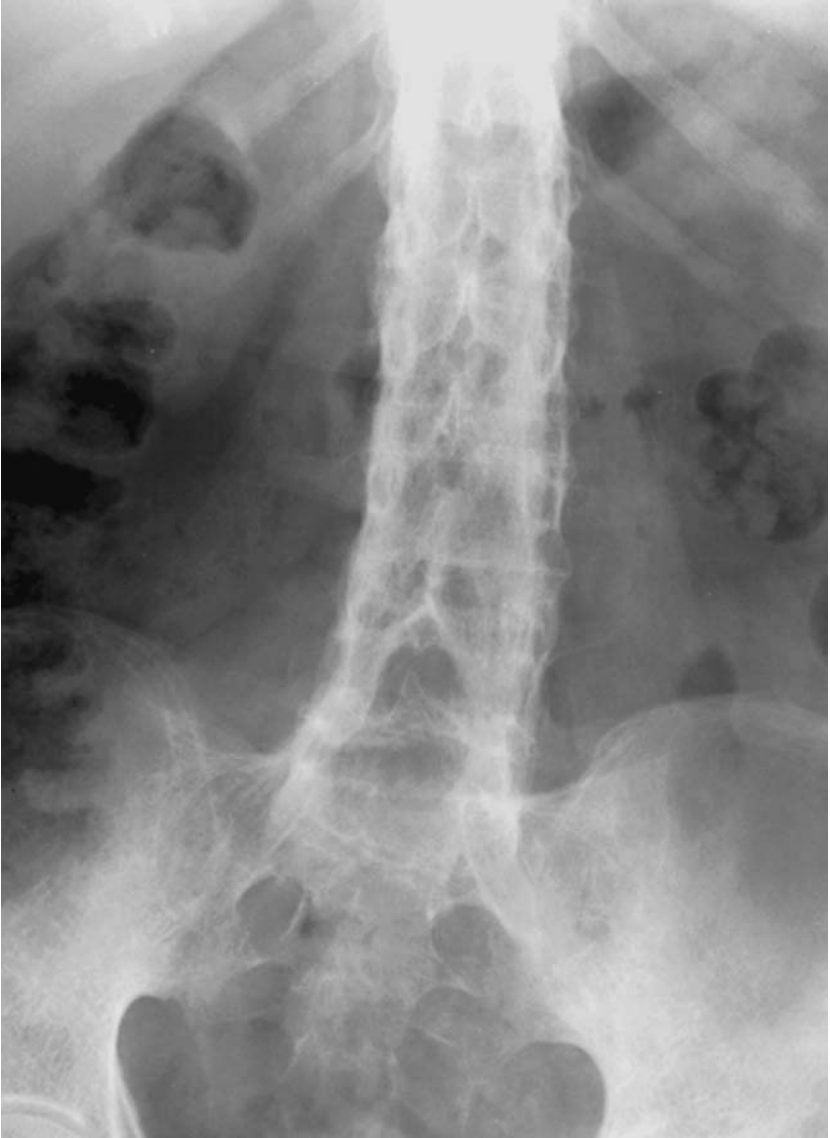- Sacroiliitis is a pre-requisite for diagnosis. Look for early marginal sclerosis on the iliac side of the sacroiliac joint (SIJ), usually starting in the inferior 1/3 (synovial part) of the SIJ. Complete SIJ ankylosis is a late sign.
- Osteitis results in squaring of vertebral bodies. The earliest signs of spondylitis are manifest as small erosions at the corners of the vertebral bodies – the so-called Romanus lesion. Syndesmophyte formation eventually lead to classical ‘bamboo spine’.
- Osteoporosis and kyphosis occur with long-standing disease.
- Extra-axial skeletal involvement mimics mild rheumatoid arthritis.

Management

- NSAIDs and physiotherapy form the bulk of treatment.



Ankylosing spondylitis: 'squaring-off' of the vertebral bodies with anterior syndesmophyte formation.



Ankylosing spondylitis: sacro-ileitis and a 'bamboo spine'.

Avascular necrosis – osteonecrosis

Characteristics

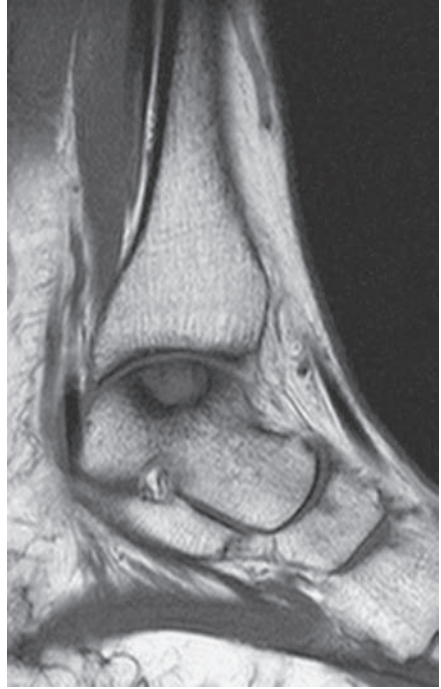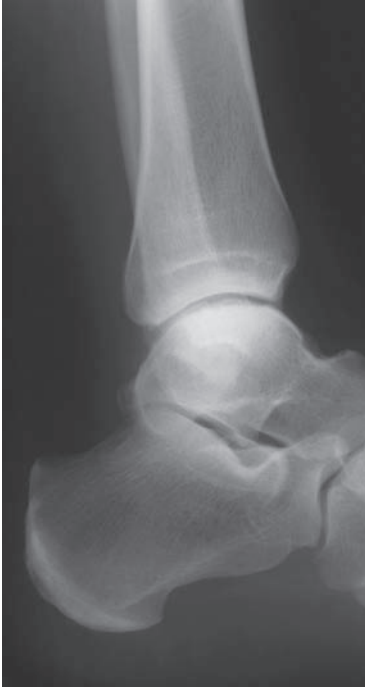- ‘Death’ of a (bony) structure secondary to insufficient blood supply.
- Primary pathology is of unknown aetiology, but secondary AVN is linked with a variety of pathologies – see below.
- Idiopathic avascular necrosis occurs in childhood in the proximal femoral epiphysis (‘Perthes’ = Legg–Calve–Perthes Disease); See Perthes’ disease. AVN is also seen in childhood hips following SCFE (or SUFE)
- Associated with steroid use, alcohol abuse, metabolic disease (e.g. Gaucher’s disease), vasculitis (SLE), sickle cell disease, malaria, occupational causes (e.g. deep-sea divers – caisson disease), venous thromboembolism and bone-marrow transplants.
- Certain bones in adulthood are particularly associated with AVN; the eponyms below are for idiopathic AVN.
 - (a) Femoral head – see separate section.
 - (b) Distal femur – usually medial femoral condyle – SONK (spontaneous osteonecrosis of the knee).
 - (c) Proximal humerus – idiopathic and post-traumatic.
 - (d) Talus.
 - (e) Lunate – Kienböck’s disease – see separate section.
 - (f) Metatarsal head – Freiburg’s disease for second MT head.
 - (g) Navicular – Köhler’s disease.
 - (h) Scaphoid – Preiser’s disease.
 - (i) Capitellum – Panner’s disease – associated with osteochondritis.

Clinical features

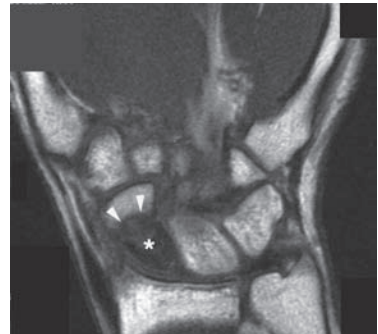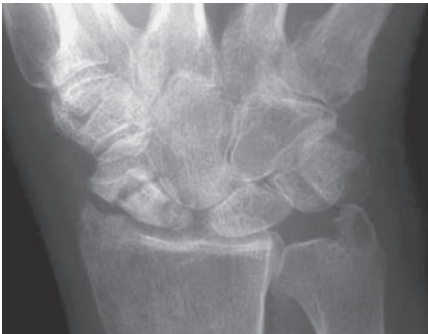- Classically present with pain of insidious onset.
- Pain often worse at night.
- Pain is usually severe and often becomes more bearable after several weeks.
- Joint locking with loose bodies – separated osteochondral fragments.
- Reduced function of adjacent joints.

Radiological features

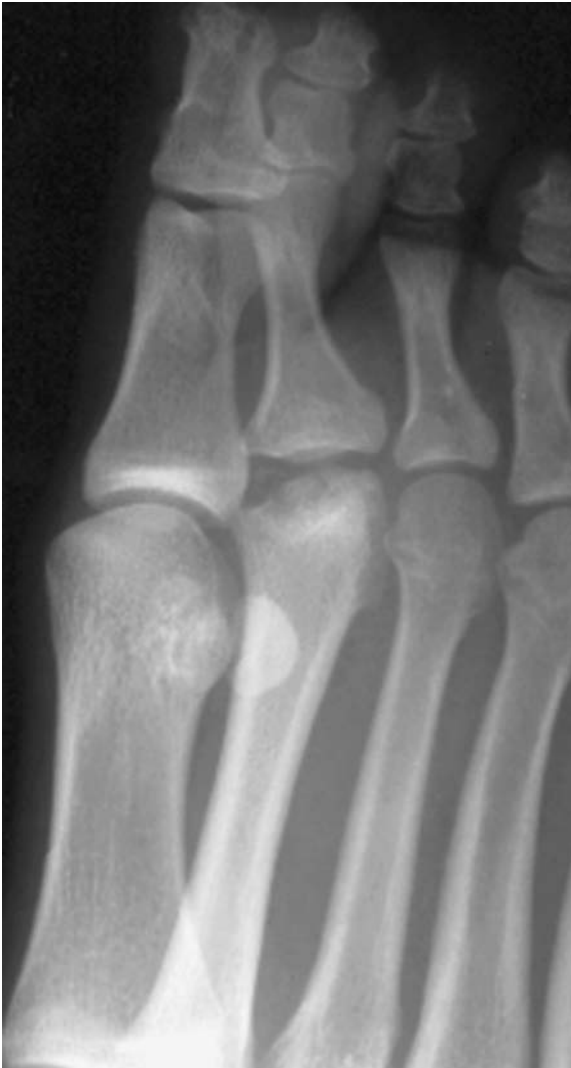- The initial radiograph if taken early may be normal.
- The affected bone becomes sclerotic with later collapse and remodelling.
- Degenerative change within adjacent joints.
- MR – 90–100% sensitivity for symptomatic disease.
 - Changes reflect the death of fatty marrow cells.
 - Bone-marrow oedema is manifest as reduced signal on T1 weighted and increased signal on T2 weighted images.
 - Early subchondral collapse is seen as crescentic low signal.
 - In later disease, fibrosis results in low signal on both T1 and T2 weighted images.



Avascular necrosis of the talus. Note the increased subchondral sclerosis of the talar dome. The sagittal T1 MRI clearly defines the extent of the osteonecrosis.



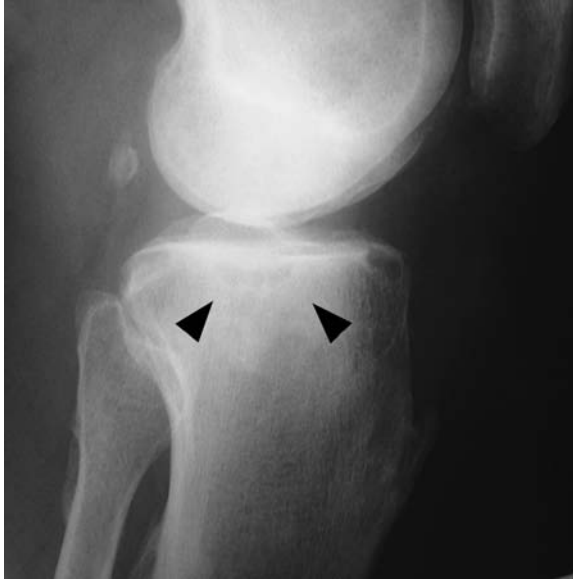Avascular necrosis of the scaphoid: fracture of the waist of scaphoid with increased sclerosis and early collapse of the proximal pole. Coronal T1 MRI demonstrates the loss of normal marrow signal, secondary to AVN, within the proximal pole (asterisk). Idiopathic scaphoid AVN is rare.



Freiberg's osteonecrosis of the second metatarsal head.

Management

- Pain relief with analgesics and immobilisation.
- Remove any precipitating factors, e.g. drugs, alcohol, occupation.
- Surgery, if indicated, is generally reparative or reconstructive in nature.
- Core decompression and vascularised bone graft aims to restore vascularity and prevent further collapse.
- In severe collapse, reconstructive surgery should be considered.



Lateral view of a 55-year-old male with medial tibial plateau SONK. Note the sclerosis and early collapse (arrowheads).

Femoral-head osteonecrosis

Characteristics

- Occurs most commonly in the 20–50 age group.
- Bilateral: 50% of idiopathic cases, or 80% in steroid-induced cases.
- Commonly seen following intracapsular fractures of the femoral neck. Increased risk if displaced (up to 80%).
- Risk factors: steroid use, alcohol abuse, metabolic disease (e.g. Gaucher's disease), vasculitis (SLE), sickle cell disease, occupational causes (e.g. deep sea divers – caisson disease), venous thromboembolism and bone-marrow transplant.

Clinical features

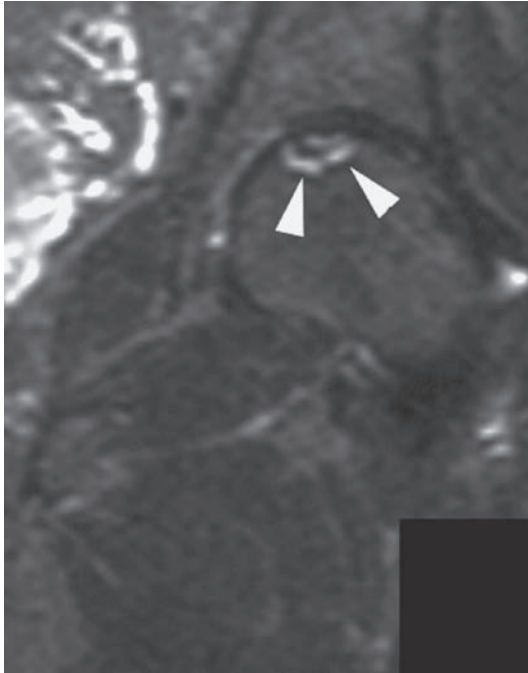
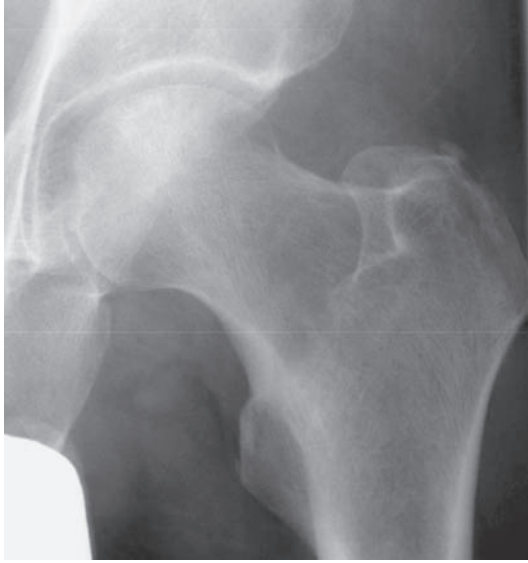- Classically present with pain of insidious onset.
- Pain often worse at night.
- Pain is usually severe but may become more bearable after several weeks.

Radiological features

- The initial radiograph if taken early may be normal.
- The affected bone becomes sclerotic with later collapse and remodelling.
- Ficat staging (1968 Ficat and Arlet).
 - 0 – pre-clinical – not included in original classification – normal X-ray and MRI.
 - 1 – pre-radiological – pain, normal X-ray, early MR changes.
 - 2 – sclerosis on X-ray but congruent head.
 - 3 – flattened head with crescent sign.
 - 4 – secondary degenerative changes.

Management

- Remove any causative factors.
- Management is targeted towards preservation/restoration of vascularity where possible, or reconstruction in late disease.
- Techniques used in each disease stage include:
 - 1 – core decompression.
 - 2 – core decompression and strut graft (free or vascularised).
 - 3 – strut graft/total hip replacement.
 - 4 – total hip replacement.



Early avascular necrosis of the femoral head. Patchy sclerosis seen within the superior aspect of the femoral head. Corresponding signal abnormality seen on the coronal STIR MRI (arrowheads).

Kienböck's disease

Characteristics

- Collapse of the lunate due to vascular insufficiency.
- Tends to affect young adults.
- May be associated with a single or repetitive trauma.
- Commonly described in manual labourers.

Clinical features

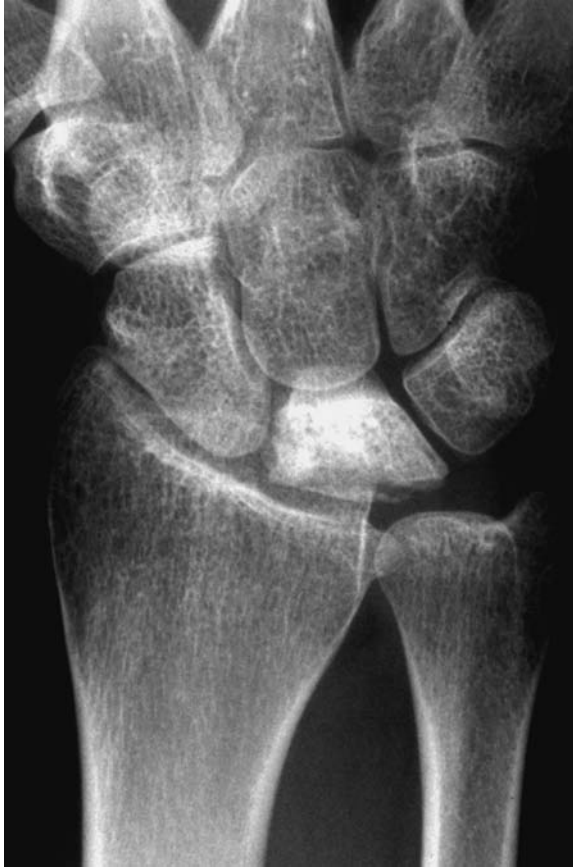- Wrist pain radiating up the forearm with an associated stiff wrist and weak grip.
- Lunate is tender on dorsal surface.
- Disability may be minimal.

Radiological features

- The initial radiograph, if taken early, may be normal.
- The lunate becomes sclerotic with later collapse.
- Litchman stage:
 - 1 Normal X-ray. Abnormal MRI.
 - 2 Sclerosis of the lunate. No lunate collapse.
 - 3(a) Lunate collapse. No carpal collapse.
 - 3(b) Lunate collapse with carpal collapse.
 - 4 Osteoarthritis.
- MRI/bone scan – more sensitive in the early stages.

Management

- **R**est (splint), **R**educe pain (analgesia), **R**eassure.
- If non-operative treatment fails:–
 - Stages 1 and 2 – aim to prevent lunate collapse by restoring joint level (radial shortening or ulnar lengthening) or revascularising the lunate.
 - Stage 3 – limited carpal fusion, wrist denervation, proximal row carpectomy, wrist arthrodesis, lunate replacement.
 - Stage 4 – wrist denervation or arthrodesis.



Kienböck's disease. Note the sclerosis and early collapse of the lunate, secondary to avascular necrosis.

Back pain – including spondylolisthesis/ spondylolysis

Characteristics

- Incidence of 10%–35%.
- Lifetime prevalence of 50%–80%.
- Accounts for 13% of total sickness absences in the UK, with the perceived disability apparently rising.
- Risk factors include lower socio-economic class, static posture (sitting), manual handling (particularly twisting/bending), vibration, smoking, driving and poor core-muscle tone.
- Classified by Fairbank and Hall into five types:
 1. Simple non-specific back pain.
 2. Chronic.
 3. Root pain (see prolapsed discs).
 4. Neurogenic ('spinal') claudication.
 5. Unclassifiable (e.g. tumours, infections and psychosomatic).

Clinical features

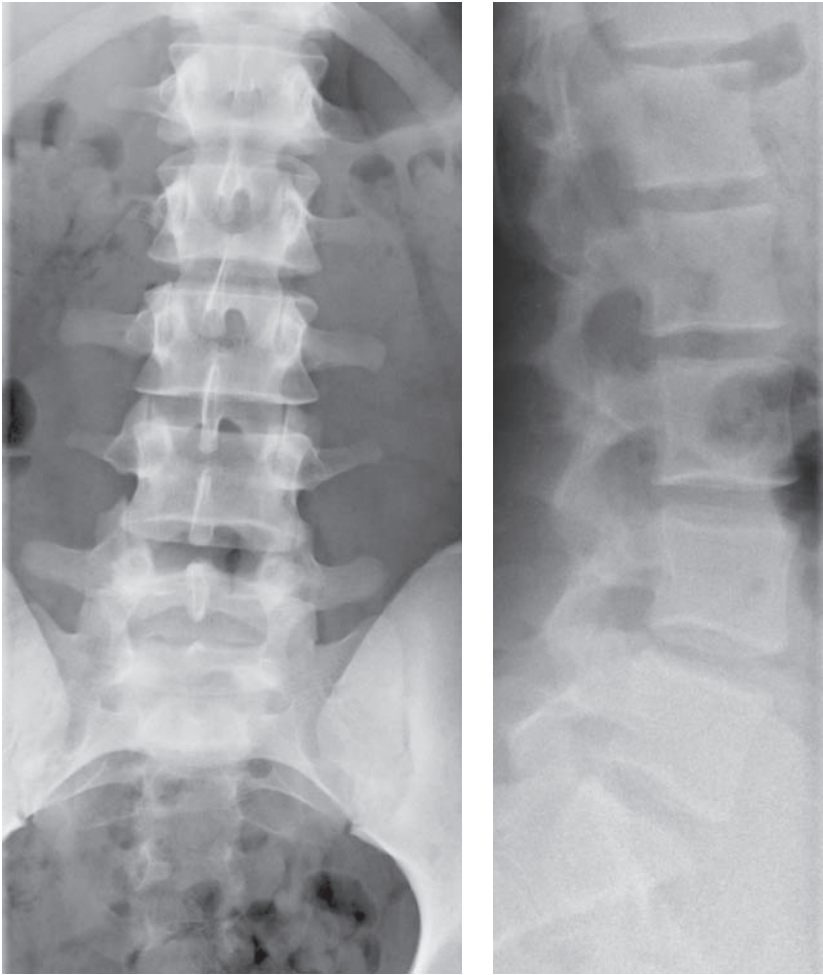
- Usually lower lumbar vertebrae affected.
- Never forget the sacro-iliac joint – 15%–20% lower back pain.
- May have 'sciatic' component (pain from the buttock down the posterior aspect of the thigh and leg) which is exacerbated by stretching of the sciatic nerve.
- Middle-aged disease.
- Worsens with lack of movement (e.g. lying in hospital beds!).
- Generally improves over time.
- Look for 'red flags':
 - bilateral leg pain.
 - difficulty with sensation or control of urinary (or bowel) function.
 - saddle anaesthesia.
 - unremitting pain – particularly night pain.

Radiological features

- Depends on the condition causing the back pain.
- Plain radiographs are classically normal and therefore only indicated in specific cases.
- Conversely perceived abnormalities on radiological investigation may not fit the clinical picture.

Management

- Limited reduction in activity, i.e. rest with ice and use NSAID.
- Mobilisation with either physiotherapy/chiropractor/self-physiotherapy.
 - 'Graded lumbo-pelvic core stability programme'.
- Act appropriately if 'red flags' present.

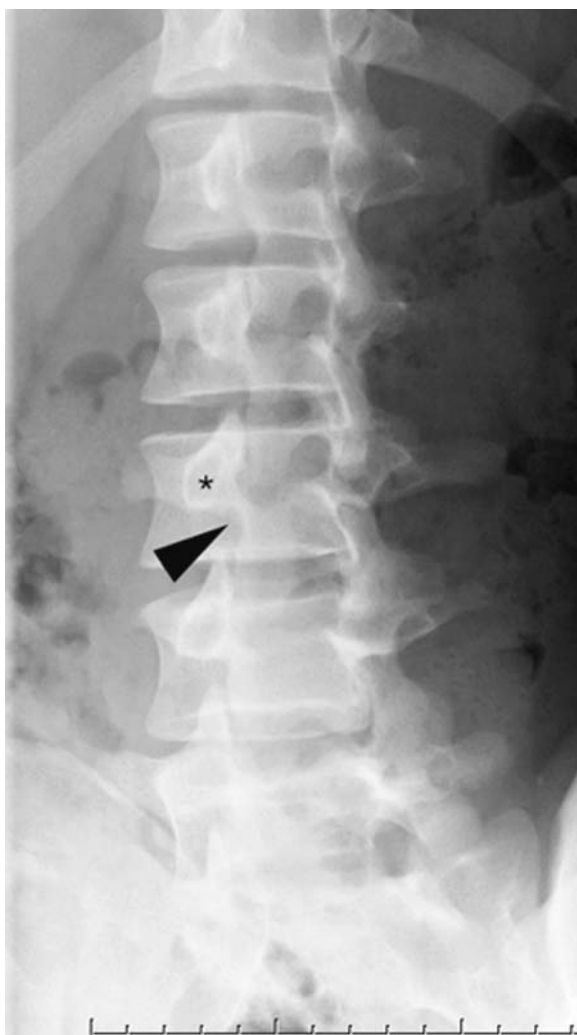

Normal frontal and lateral views of the lumbar spine. A normal X-ray does not exclude a disc protrusion.

Spondylolisthesis/spondylolysis

Characteristics

- This is forward slip of one spinal vertebra on another.
- Most commonly L4 on L5, or L5 on S1.
- Six types:
 - Lytic or isthmic – 50% cases – the pars interarticularis, most commonly of L4 vertebra is ‘lysed’ in two pieces, i.e ‘spondylolysis’. The elements posterior to this defect (spinous process, laminae and inferior articular facets) remain as an isolated segment which becomes left behind as the anterior elements sublux forward.
 - Degenerative – 25% cases. Usually L4–5.



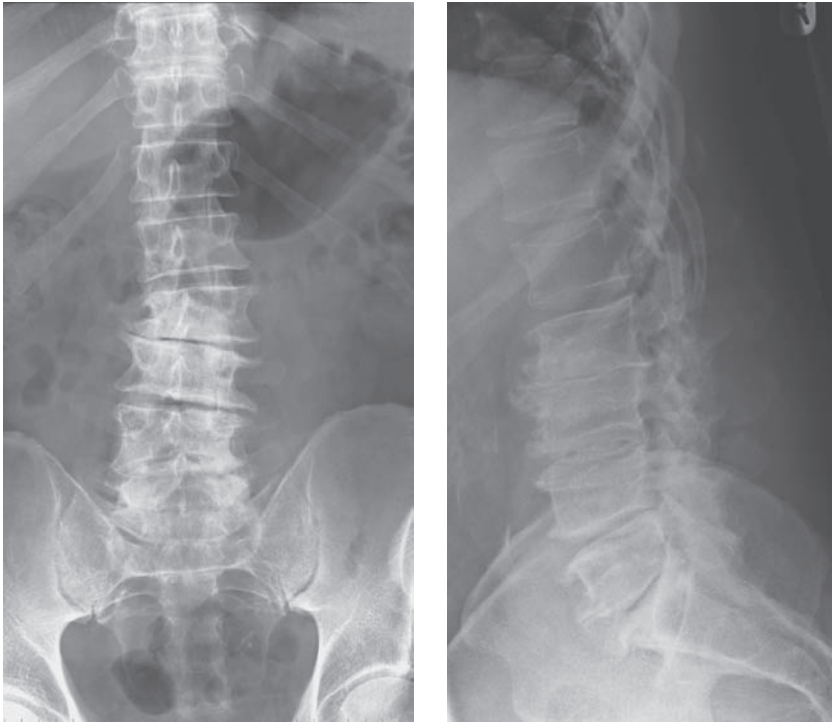
Left lateral oblique view of the lumbar spine. The pars inter-articularis ('neck of Scottie dog': arrowhead) and intervertebral foraminae are clearly seen.

* = pedicle.

- Dysplastic – 20% cases – developmental anomaly of the superior articular facets producing severe anterior subluxation. Associated with other spinal malformations such as spina bifida occulta.
- Post-traumatic.
- Pathological, e.g. tumour or TB.
- Iatrogenic – post-operative secondary to extensive spinal decompression.

Clinical features

- May be asymptomatic.
- Children – abnormal posture with protruberant abdomen.

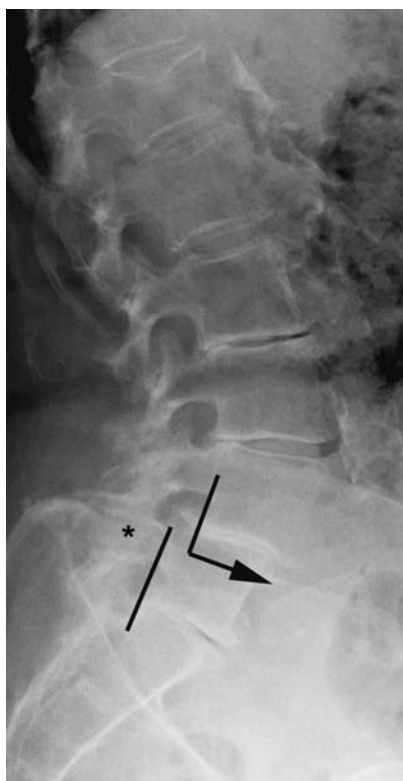

Advanced degenerative change seen at the lower four lumbar levels, with marginal osteophyte formation, disc-space narrowing, end-plate sclerosis, and facet-joint diseases.

- Adolescents/young adults – back pain – often post-exercise. Possible sciatica.
- Over 50s – M \gg F – back pain, sciatica and possible spinal claudication.
- Examination – flattened buttocks, transverse loin crease, apparently high sacrum, possible scoliosis, and possible palpable vertebral step.

Radiological features

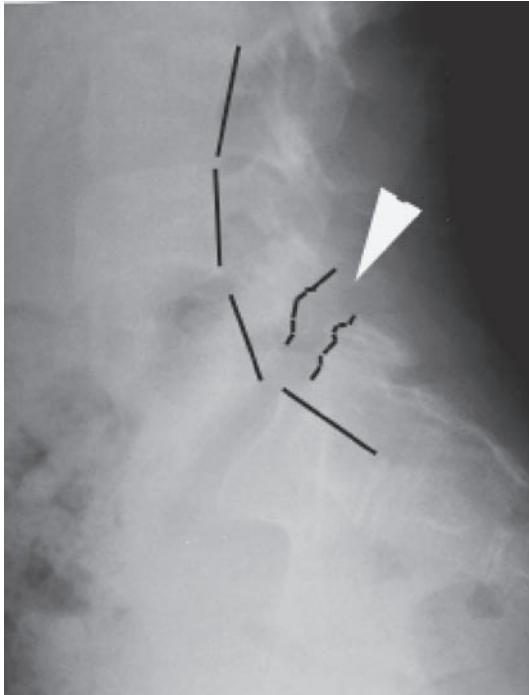
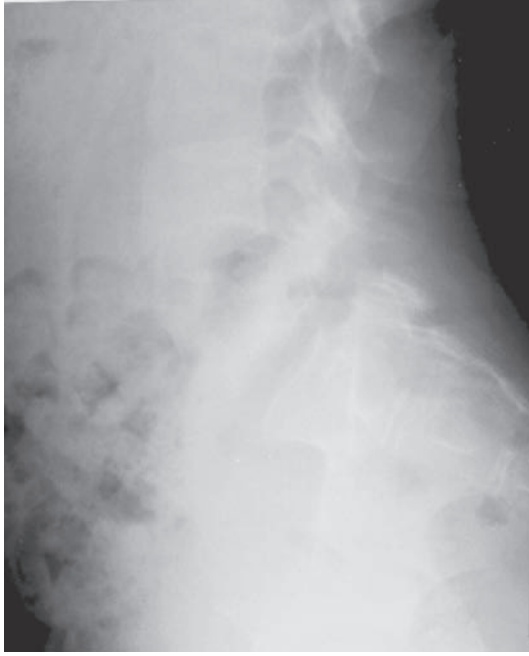- Lateral X-ray – forward shift of the unstable vertebra on the one below.
- Graded by the percentage body width subluxation: – Grade 1 = $<25\%$ (most common), Grade 2 = $25\%–50\%$, Grade 3 = $50\%–75\%$, Grade 4 = $>75\%$.
- Pars interarticularis defect may be seen – look for the ‘collar’ on the neck of the ‘Scottie dog’! Oblique views may be helpful to see the pars defect.
- Reverse-angle gantry CT is most reliable to assess and grade the degree of slip.
- MRI in cases of neurological symptoms or signs.



Degenerative spondylolisthesis of L4 on L5, secondary to facet joint disease (asterisk).

Management

- Non-operative – core-stabilisation exercises.
- Operative:
 - Disabling symptoms.
 - >50% slip.
 - Progressive slip – careful monitoring during adolescent growth.
 - Significant neurological compression.
- Children – *in situ* posterior intervertebral fusion.
- Adults – anterior or posterior interbody fusion.
- Pure degenerative spondylolisthesis with claudication – spinal decompression alone may suffice.



Spondylolysis of L5: the pars defect is clearly visible (arrowhead). Note the alignment of the posterior vertebral bodies is maintained.

Bone cysts

Characteristics

- Solitary or unicameral bone cysts occur in childhood, typically affecting the metaphysis of a long bone, most commonly the proximal humerus and femur.
- Simple cysts are not tumours and often heal spontaneously.
- Contain straw-coloured fluid and are surrounded by a flimsy fibrous tissue membrane which contain giant cells.
- In actively growing cysts there will be a zone of bone resorption 'behind' the cyst.
- M : F = 3 : 1.

Clinical features

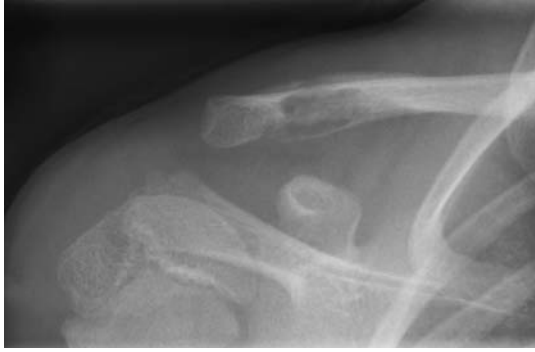- Often present with fracture through a cyst.
- Otherwise asymptomatic.

Radiological features

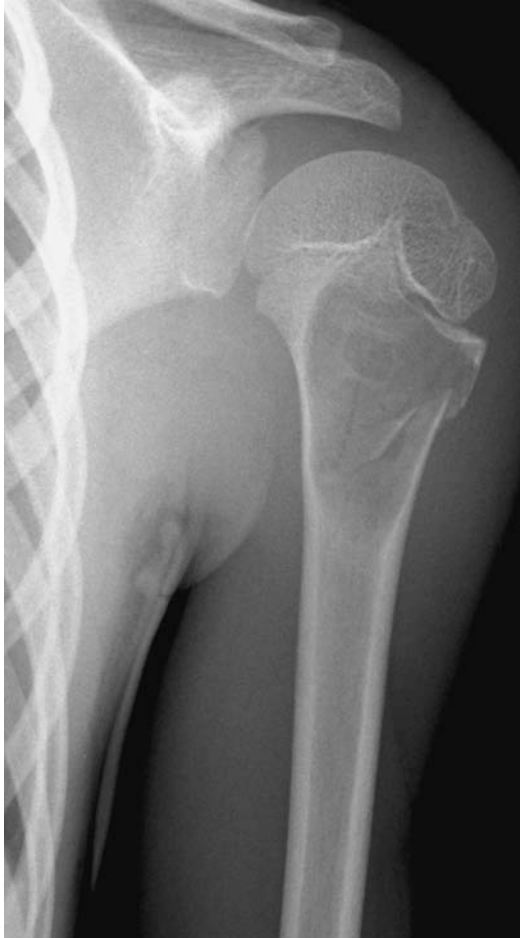- Well-circumscribed (metaphyseal) radio-lucency, with a fine sclerotic border (narrow zone of transition), and long axis parallel to long axis of host bone.
- Often extends to the physis, associated cortical thinning and expansion of the metaphysis.
- A gravity-dependent fragment may be seen within the cyst after fracture (fallen fragment sign).

Management

- If asymptomatic (incidental diagnosis), observe with repeat X-rays. Reassure parents and warn about fractures – avoid contact sports.
- Actively growing cysts – aspiration and steroid injection. If the cyst still enlarges or fractures, then curettage and bone (or substitute) grafting.
- Fracture – treat the fracture non-operatively and the cyst is likely to fill in as the fracture heals.
- For recurrent fractures, curettage, grafting +/- stabilisation is the treatment of choice.



Pathological fracture through a unicameral bone cyst within the distal clavicle. Note the callus formation superiorly as the fracture starts to consolidate.



Unicameral bone cyst within the proximal humeral metaphysis, with an associated pathological fracture.

Bone infarcts (medullary)

Characteristics

- Idiopathic bone infarcts characteristically occur in long-bone metaphyses.
- Histological testing reveals mineralisation of necrotic marrow.
- Aetiology is likely to be related to intrinsic/extrinsic vascular compromise such as thrombosis, arteritis, atherosclerosis or external compression (fractures, oedema, tumour, etc).

Clinical features

- Classically asymptomatic and discovered as an incidental diagnosis.

Radiological features

- Early rarefaction followed by sclerosis, calcification, and ossification parallel to the cortex in the healing phase.
- Bone scan – ‘cold spot’ or no increased uptake in the early stages; becomes ‘hot’ as revascularisation occurs.

Management

- No treatment is required; however, malignant fibrous histiocytoma has been reported developing in previous bone infarcts.

Bone islands

Characteristics

- Histologically these are markedly thickened bony trabeculae.
- Seen in all ages.
- Unknown aetiology but may represent a developmental anomaly.
- Usually solitary, commonest in the proximal femur and ilium.

Clinical features

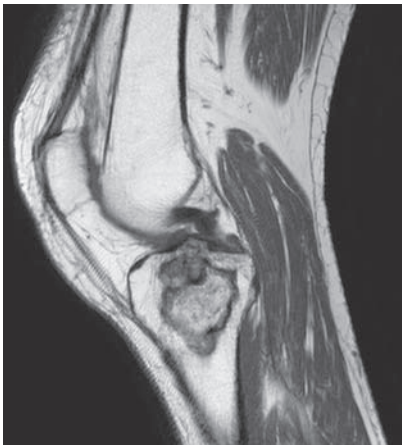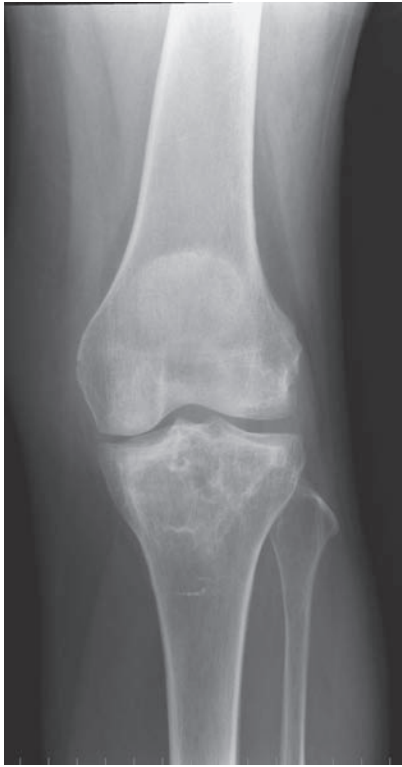- Asymptomatic – incidental diagnosis, but these are important in the differential diagnosis of more sinister lesions.

Radiological features

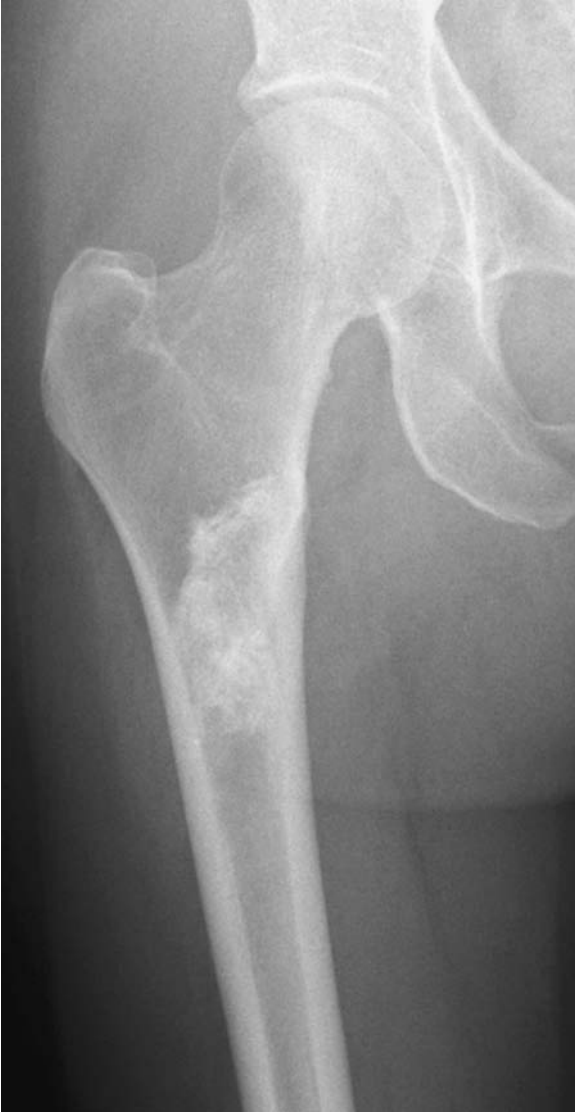- Sclerotic areas within bone which are well demarcated from surrounding normal bone (narrow zone transition). Classically the margin appears feathery.
- No cortical involvement or periosteal reaction.
- Often oval with the long axis parallel to the bone.
- Bone scan – if large may show increased uptake.

Management

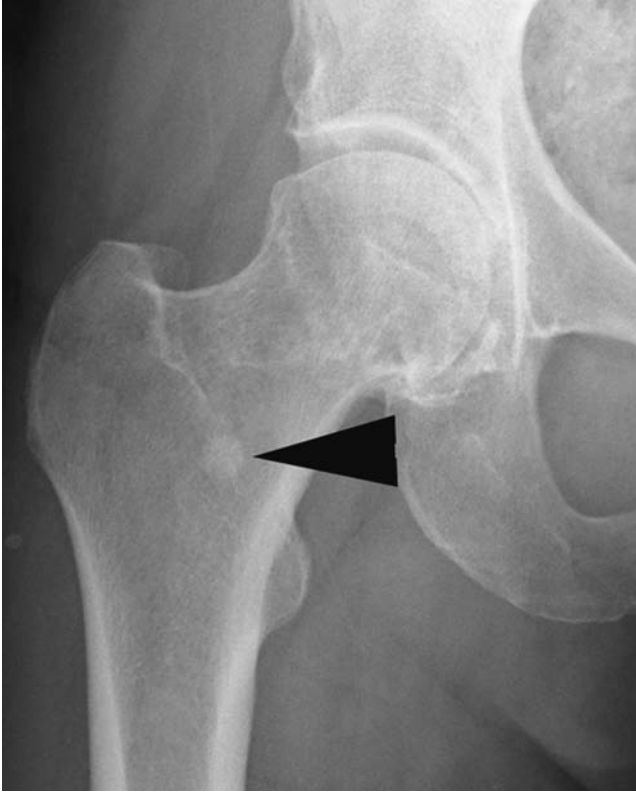- Exclude more sinister pathology, but no particular treatment is required.



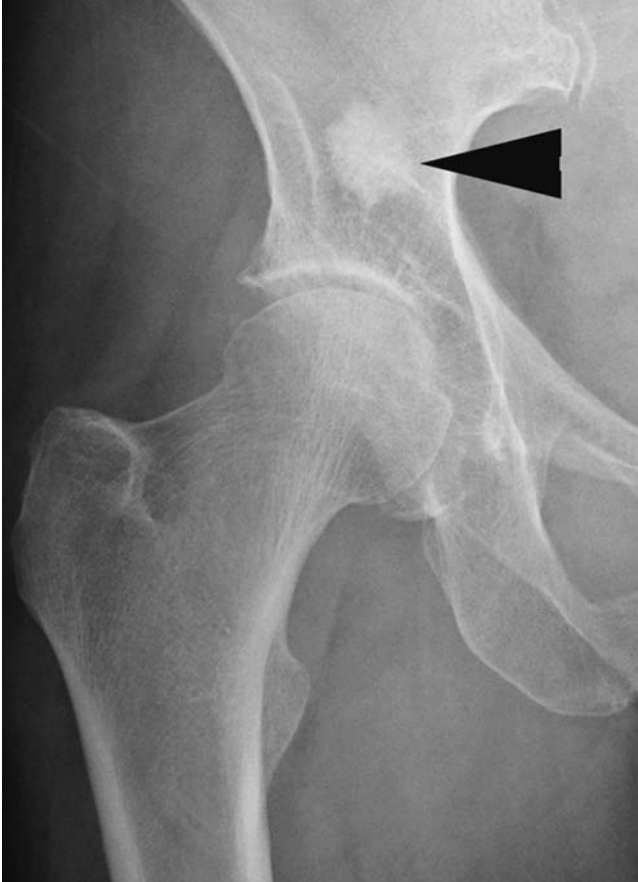Medullary infarct within the proximal tibial metaphysis: plain radiograph and T1 W MRI. Well-defined lesion with sclerotic margins and patchy central calcification. On MRI this corresponds to a hyperintense lesion (marrow fat) with a well-defined peripheral low intensity (sclerotic) margin containing punctate central low intensity (calcification).



Large well-defined sclerotic infarct within the proximal femoral metaphysis.



Bone island at the base of the right femoral neck.



Bone island above the right acetabulum.

Charcot joint (neuropathic joint)

Characteristics

- Progressive condition characterised by joint destruction, pathological fractures, dislocation and deformity.
- Likely secondary to sensory, motor and autonomic neuropathy resulting in:
 - Increase in blood flow leading to osteopenia.
 - Muscle imbalance with resulting abnormal loading.
 - Minor repetitive trauma masked by sensory loss.
- Associated with diabetes, tertiary syphilis, syringomyelia and myelomeningocele amongst others.

Clinical features

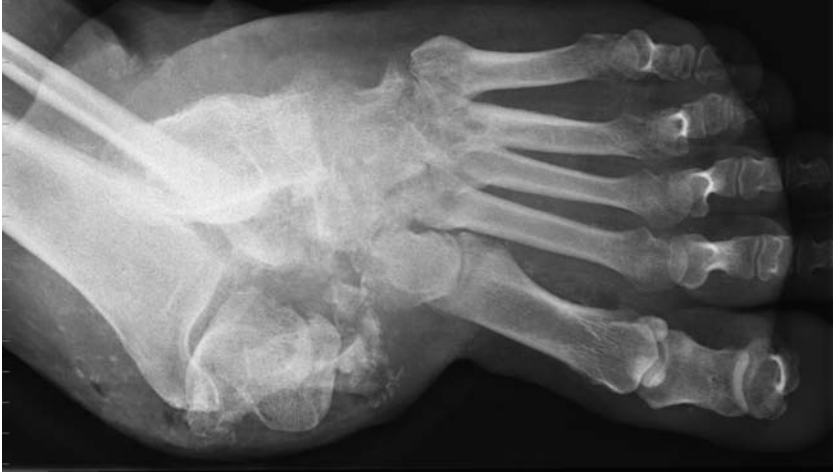- Classically a swollen joint with skin erythema and an effusion associated with sensory loss.
- Although thought to be insensate, pain is not an uncommon feature.
- Often co-existing ulceration can cloud the clinical picture.

Radiological features

- Four **D**s.
- Joint instability, effusion and normal or increased bone density can be seen in all stages. (**D**isorganisation and **D**ensity increase.)
- Fragmentation of articular bone can result in loose bodies. Osteophytic fractures may occur especially in the spine. (**D**ebris.)
- Articular bone destruction often resembles amputation due to sharp edges. (**D**estruction.)

Management

- Acute – aim to reduce stresses and immobilise. Mobility can be maintained by a contact cast. Aim to return to appropriate normal footwear by 6 months.
- Long term – well-chosen footwear and careful follow-up surveillance.
- Consider surgery for deformities predisposing to recurrent ulceration.
- Excision of exostoses and arthrodesis may be useful. Aim for a stable ambulant joint.



Neuropathic left foot: grossly disorganised joint, with associated joint destruction and considerable debris. Appearances are typical of a chronic neuropathic arthropathy.

Complex regional-pain syndrome

Characteristics

- Also known as RSD (reflex sympathetic dystrophy), causalgia, Sudek's algodystrophy/atrophy.
- An abnormal reaction to injury characterised by pain, stiffness, swelling, local osteoporosis and vasomotor changes in the affected region.
- Classified as Type I (no associated nerve injury) or Type II in which there is an associated peripheral nerve injury ('causalgia').
- Associated aetiological factors include:
 - Injury including surgical trauma – a prerequisite for diagnosis.
 - Spinal lesion – particularly in the cervical spine.
 - Peripheral nerve lesion.
 - Myocardial ischaemic disease.
 - Cerebral damage.
 - Infection.
 - Cumulative injury, e.g. overuse syndromes.

Clinical features

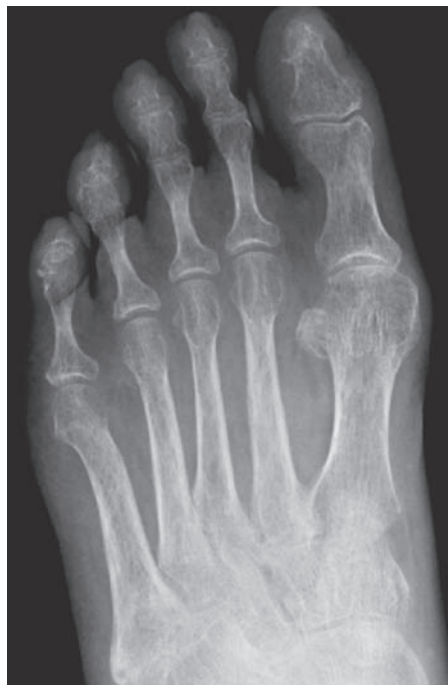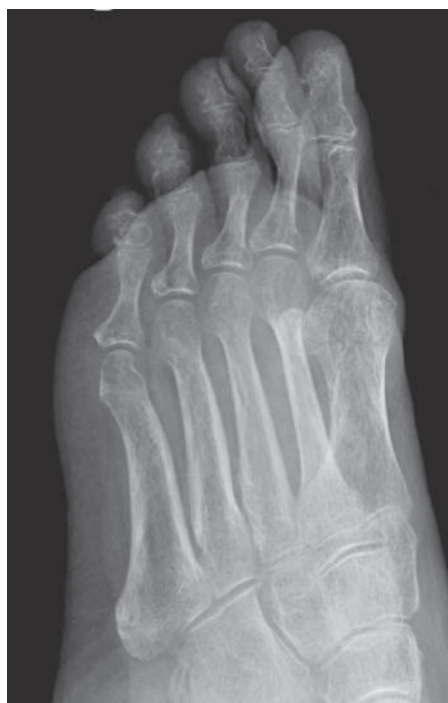- The diagnosis hinges on pain that is diSproportionate to the injury and one additional 'S' from this list:
 - Swelling.
 - Stiffness.
 - Sympathetic dysfunction.
 - Shiny skin or other growth disturbance – atrophy/dystrophy.
- Also look for spreading symptoms which may be:
 - Continuity type – local spread, e.g. nail overgrowth.
 - Mirror-image type – contralateral mimicry.
 - Independent type – different and remote regional involvement.
- Length of symptoms is variable from a few weeks to permanent.

Radiological features

- Periarticular soft-tissue swelling.
- Local osteopenia on X-ray.
- Bone scan often shows segmental differential (high or low) uptake.

Management

- Difficult; however identifying and removing, or treating, the aetiological factor is of vital importance.
- Analgesia/pain team referral and intensive physiotherapy.
- Neuromodulation with tricyclic drugs or gabapentin.
- Sympathetic ganglion blockade can be diagnostic and of therapeutic use.
- Treat complications such as skin infections secondary to breakdown.
- Amputation has been used in rare cases for resistant CRPS.



Reflex sympathetic dystrophy of the right foot following 'minor' trauma. Note the local osteopaenia and soft tissue swelling around several of the proximal phalanges.

Crystal deposition disorders

Characteristics

- Characterised by crystal deposition in or around joints.
- Divided into gout and pseudo-gout – see ‘Gout’.
- Predominantly females over 60 years of age.
- Pseudo-gout is subdivided, according to the crystal type, into calcium pyrophosphate dihydrate deposition disease (CPPD) and calcium hydroxyapatite (HA) otherwise known as basic calcium phosphate (BCP) deposition.
- In contrast to gout, CPPD and BCP are usually found around large joints, most commonly the knee and the shoulder. CPPD occurs in certain metabolic anomalies (e.g. hyperparathyroidism, haemochromatosis) in which there is a critical change in calcium equilibrium in cartilage.

Clinical features

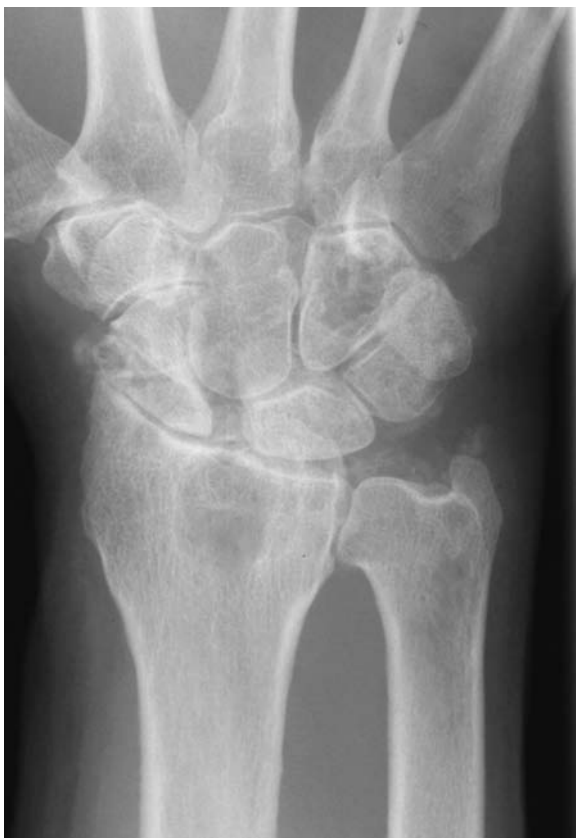- Predominantly females over 60 years of age. Three clinical situations:
 - (i) *Apparently inert and asymptomatic* – incidental diagnosis usually with chondrocalcinosis found on a knee radiograph.
 - (ii) *Acute inflammatory synovitis* – true ‘pseudogout’ with an acute large-joint monoarthritis; usually the knee.
 - (iii) *Chronic arthropathy* – very often polyarticular, including shoulder, ankle and elbow. Severe joint destruction, sometimes with acute flare-ups alternating with chronic destruction, mimicking rheumatoid arthritis.

Radiological features

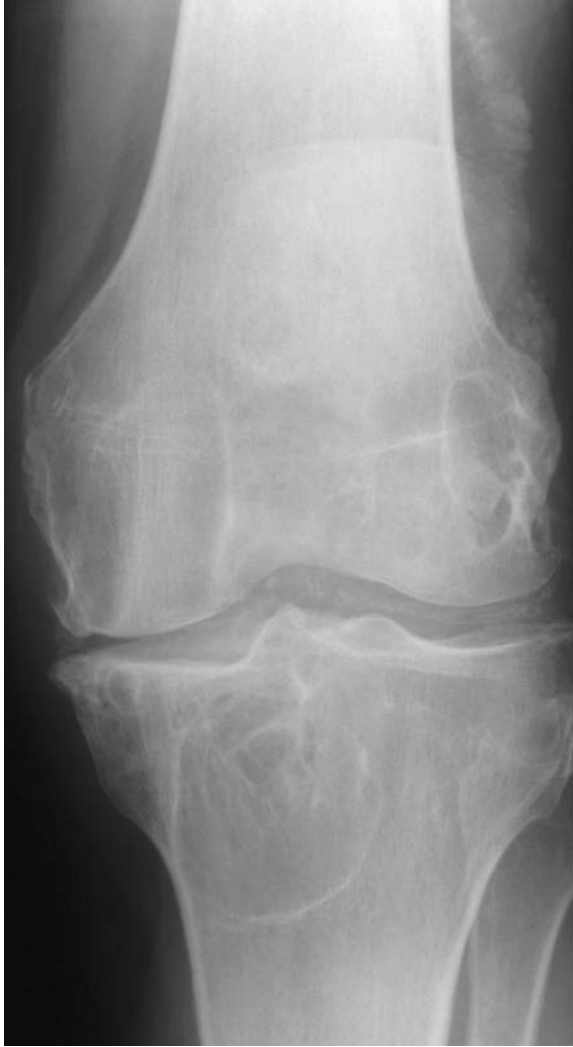- *Calcification* – in and around knee, wrist, shoulder, hip, pubic symphysis and intervertebral discs. In articular cartilage a parallel line is seen adjacent to the joint where calcium is deposited. In fibrocartilage (menisci and intervertebral discs) cloudy irregular opacities are seen. Calcium may be found in any juxta-articular structure.
- *Degeneration* – Similar features to OA (see OA) but predilection for knee, particularly patellofemoral joint, mid-foot (talonavicular joint), shoulder and wrist.

Management

- Diagnosis is by aspiration and microscopy with polarised light. Imperative to exclude septic arthritis on first presentation.
- Symptomatic relief with NSAIDs is the mainstay of treatment. In recurrent attacks and particularly in the elderly consider intra-articular steroid injection.
- Arthroscopic retrieval of loose bodies (if causing mechanical symptoms) and lavage of the joint have also been described with some success.



Calcium pyrophosphate dihydrate deposition: advanced degenerative changes seen at the radiocarpal and distal radioulnar joints, with scapholunate separation and a large degenerative geode within the adjacent radial metaphysis. Note the calcification within the TFCC secondary to CPPD.



Meniscal chondrocalcinosis secondary to CPPD. Degenerative changes seen within the medial tibiofemoral compartment, with prominent associated degenerative cysts.

Developmental dysplasia of the hip (DDH)

Characteristics

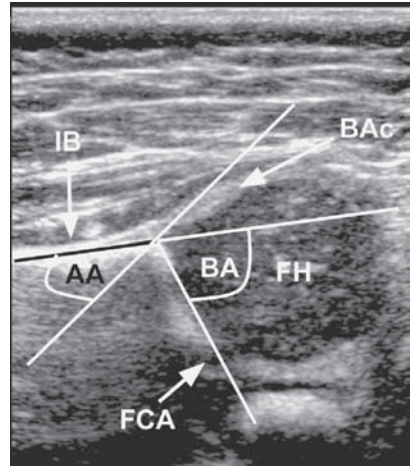
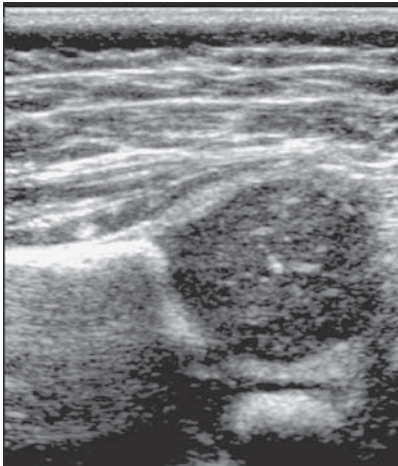
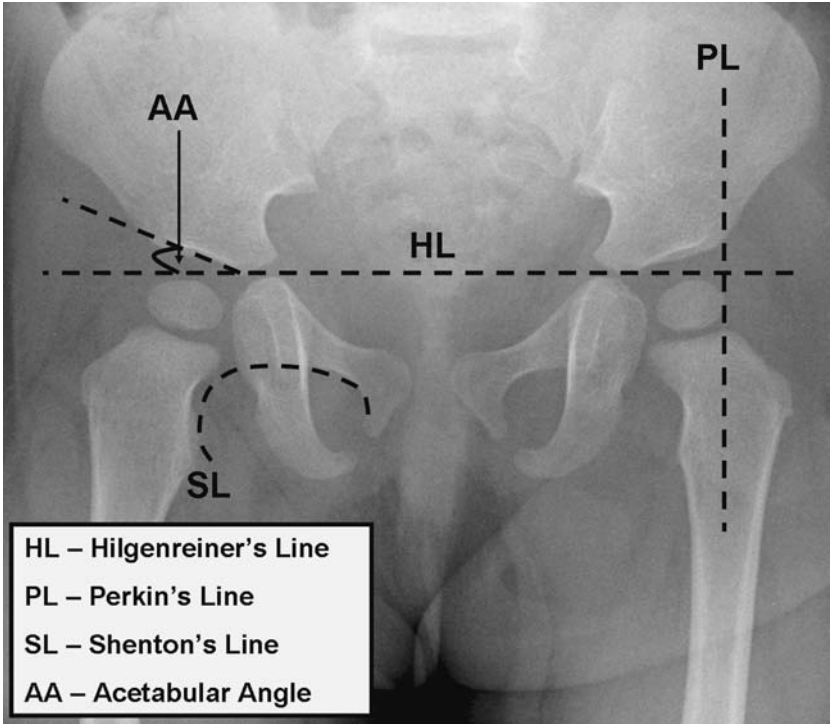
- Previously known as congenital dislocation of the hip (CDH), but now recognised as a developmental failure of the acetabulum around the femoral head.
- A dysplastic acetabulum is shallow and ‘vertical’ rather than concentrically covering the femoral head. This allows an increased degree of instability in the hip joint which, in extreme cases, presents as frank dislocation of the hip. However, this is a spectrum of disease and DDH often has a bearing on the aetiology of early adult hip OA.
- Female : male ratio of 7 : 1. Left hip more commonly affected than right; bilateral in 20% cases.
- The reported incidence of neonatal hip instability is 5–20/1000 live births, but following re-examination 6 weeks later, the incidence falls to 1–2/1000 infants.
- Risk factors include family history (including maternal/sibling DDH, joint laxity and shallow acetabulae), breech presentation, oligohydramnios, other developmental anomalies, high levels of oestrogen, progesterone and relaxin in the last few weeks of pregnancy, and cultural post-natal factors (swaddling increases the risk, e.g. North American Indians, whereas encouraging legs to be widely abducted to allow sitting astride the back, as in southern Chinese and certain African peoples, decreases the risk of DDH).

Clinical features

- Neonatal diagnosis is the gold standard. Look for decreased abduction in flexion, unequal gluteal and groin folds (only a ‘soft sign’ though) and an apparently short femur (Galleazzi test), but beware bilateral DDH.
- *Ortolani test* – the dislocated or subluxed hip (out) is relocated (in flexion and abduction) by ‘lifting up’ with pressure on the greater trochanter.
- *Barlow’s test* looks for instability by pushing back (i.e. posterior) in the flexed hip.
- Later presentation usually relies on parents noticing pain when applying a nappy (Diaper/napkin), or spotting uneven skin creases, clicking on walking or moving the hip. Examination would then reveal reduced abduction in flexion.
- DDH patients do not show delayed ambulation.

Radiological features

- Ultrasound – definitive test in neonatal DDH as the femoral head does not ossify until 3 months of age.
 - This consists of measuring the α angle and β angle (Graf classification) on a static coronal USS of the hip.

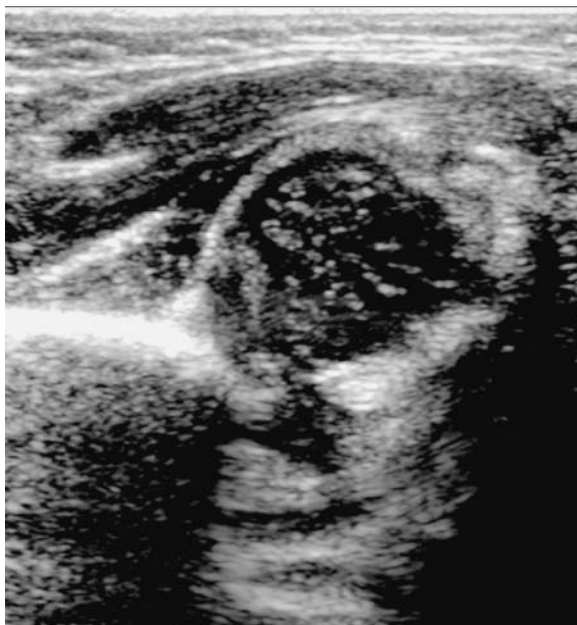


Normal neonatal hip US (coronal view). AA = alpha angle, BA = beta angle, BAc = bony acetabulum, FCA = fibrocartilagenous acetabulum, FH = femoral head, IB = iliac bone.

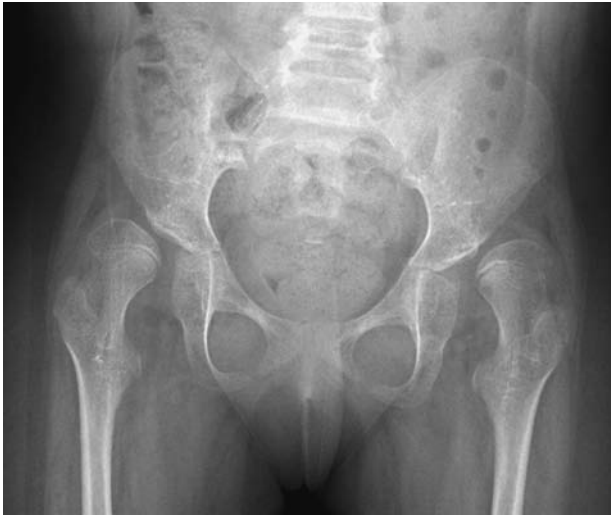- The α angle is the angle between straight lateral edge of acetabulum and bony acetabular margin. The β angle is the angle between straight lateral edge of acetabulum and the fibrocartilaginous acetabulum.
- A mature hip has an α angle $>60^\circ$.
- Dynamic assessment of hip stability is also well assessed by USS.
- Radiographs are therefore difficult to interpret; this can be helped by constructing the following lines on a pelvic radiograph.
 - **Perkins' line** is a vertical line from the lateral edge of the acetabulum – the femoral epiphysis should lie medial to this line.
 - **Hilgenreiner's line** is a horizontal line passing through the tri-radiate cartilage – the femoral head should lie below this.
 - **Acetabular index angle** should be less than 30 degrees.
 - **Van Rosen's line** is drawn up the femoral shafts, with the hips abducted at 45 degrees, and this should point into the acetabulum.

Management

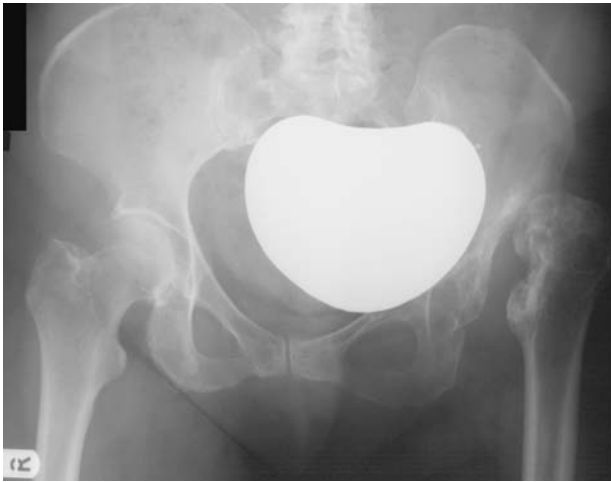- The key to management is early diagnosis; this can be achieved by diagnostic vigilance, screening examination and targeted USS (sometimes prenatal).
- In the newborn child, with a clinically or ultrasound-proven unstable hip, reduction by a Pavlik harness will be successful in approximately 95% of children, but this must be confirmed by USS at 1–2 weeks.
- For persistent dislocated hips, closed and/or open reduction (with or without soft tissue releases or osteotomy) and casting (hip spica) are required.



Dislocated (Graf III) neonatal hip.



Bilateral DDH.



'Missed' DDH of the left hip. The left acetabulum is severely dysplastic, with chronic dislocation, and a resultant pseudarthrosis.

- Once a child is crawling, the success of a Pavlik harness is greatly reduced and operative reduction is more likely. Casting is usually required for 3 to 4 months with radiological assessment of maintained reduction with X-ray, CT or MRI.

Discitis and vertebral osteomyelitis

Characteristics

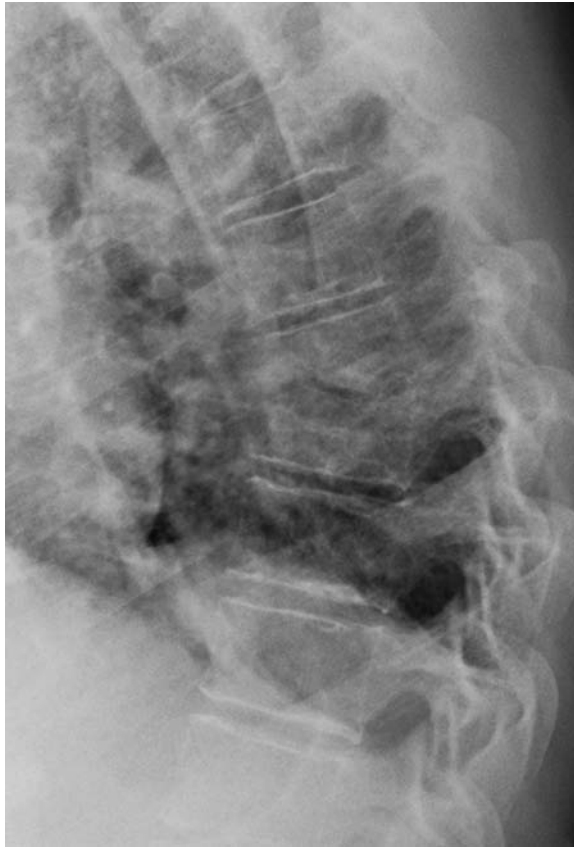- Pure discitis (infection limited to the intervertebral disc) is rare. More commonly, the infection is within the adjacent vertebrae (osteomyelitis) and spreads into the disc rather than vice versa; however, the end-plates of the adjacent vertebrae are rapidly attacked in cases of primary discitis.
- Most cases of discitis are iatrogenic, following disc injection (discography or chemonucleolysis) or surgical excision (discectomy). Discitis is rarely secondary to haematogenous spread.
- With osteomyelitis, the source of infection is either from spinal procedures (including spinal or epidural injection) or systemic infection, most commonly pelvic infection.
- The commonest organism is *Staphylococcus aureus* (50%–60%), although Gram-negative organisms, particularly *E coli*, *Proteus* and *Pseudomonas*, are increasingly pathogenic.
- In immunocompromised patients expect opportunistic pathogens. Tuberculosis must be considered in spinal infection, particularly with no history of recent spinal procedure, and in immunocompromised hosts.

Clinical features

- History of an antecedent invasive procedure or, with secondary discitis/osteomyelitis, a recent systemic infection.
- Pain localised to the particular spinal segment, but do not forget that spinal infection can track down muscle planes to present as groin or buttock abscesses. Spinal muscle spasm may also be present.
- Examination may reveal mild temperature or tachycardia. The relevant spinal segment is usually tender to palpation.
- CRP, ESR and white-cell count should be raised.

Radiological features

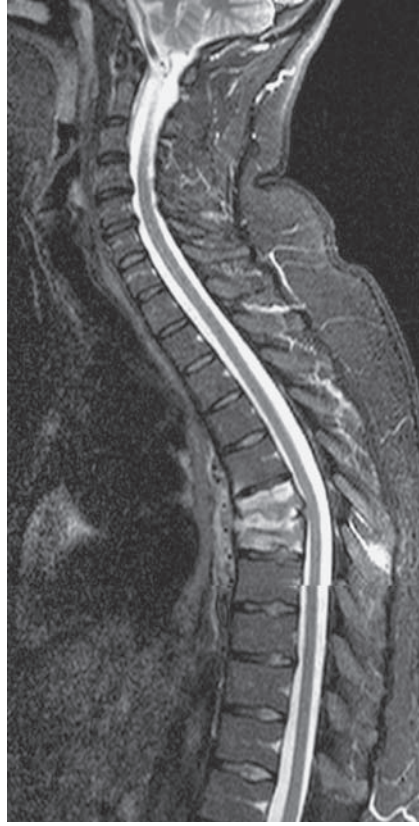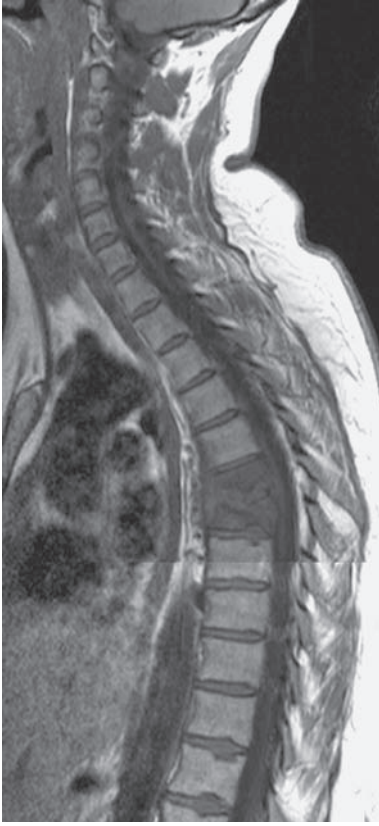- Location: L3/4 and L4/5; unusual above T9 and usually involvement is limited to one disc space.
- *Radiographs* – plain films are usually positive 2–4 weeks after onset of symptoms – decrease in disc height, indistinct end plates with destructive end plate sclerosis.
- *CT* – paravertebral inflammatory mass and extension into the epidural space.
- *Nuclear medicine* – positive before radiographic change, with increased uptake in the disc and adjacent vertebrae; however suffers from poor sensitivity (40%).
- *MRI* is the imaging modality of choice with 95% accuracy. Decreased marrow signal on T1 W imaging in two contiguous vertebrae with (usual) increased T2 W signal in the intervening disc.



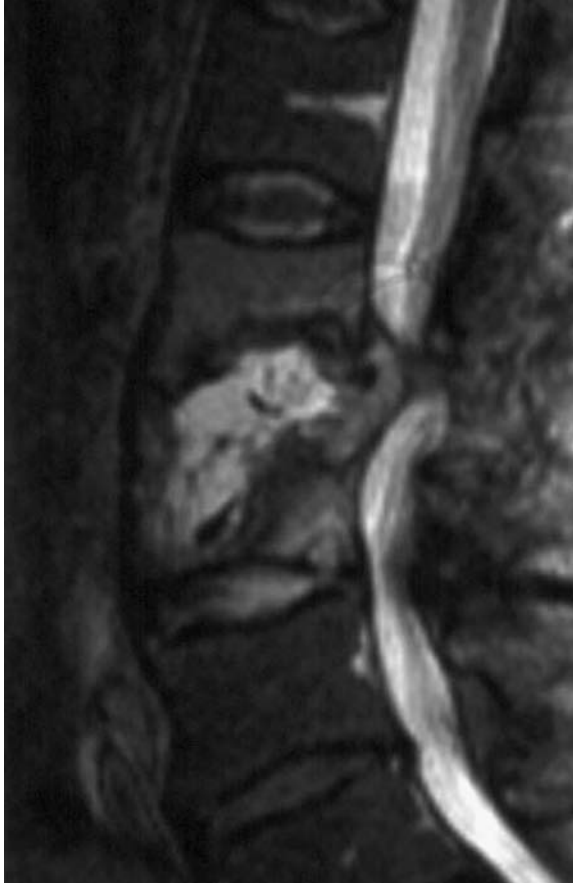Discitis T6/7 disc: ill-defined end-plate destruction across the T6/7 disc with associated loss of height in the adjacent vertebral bodies.

Management

- Once the diagnosis is made, a biopsy is essential for accurate microbiological isolation of the pathogen. This is usually performed under radiological guidance.
- Intravenous antibiotics (broad spectrum) should then be started and adjusted once the sensitivities are known.
- Treatment is monitored by CRP, ESR and WBC, and intravenous antibiotics are switched to oral between 2 and 6 weeks, depending on local policy. Three months of antibiotic therapy is normally required.



Discitis T6/7 disc: corresponding MRI (sagittal T1 and STIR sequences). Abnormal signal seen across the T6/7 disc, and adjacent vertebral bodies, with evidence of vertebral collapse.



Vertebral osteomyelitis: sagittal T2 MRI demonstrating abnormal hyperintense signal within the L3 vertebral body, with involvement of the adjacent L2/3 disc and posterior extension in to the spinal canal.

Disc prolapse – PID – ‘slipped discs’ and sciatica

Characteristics

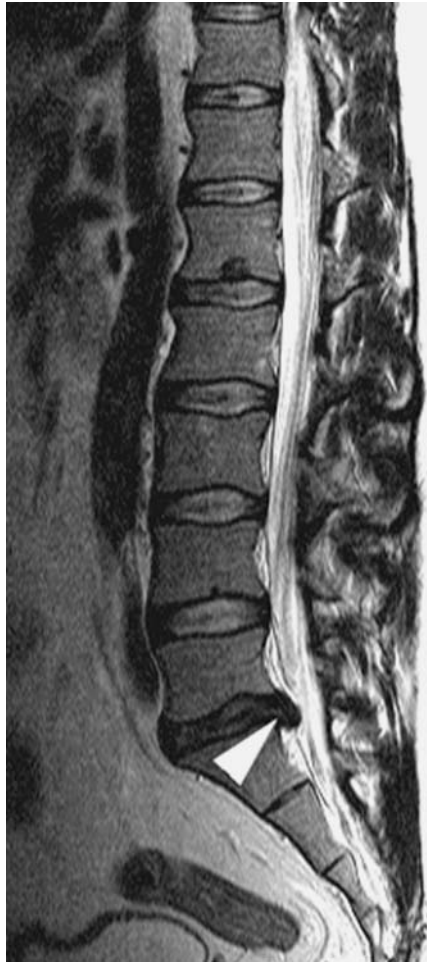- Discs can be the origin of back pain, as in discogenic lumbar back pain (believed to be due to degenerative change), or the central disc (nucleus) material can herniate through the posterior longitudinal ligament to irritate exiting nerve roots (a prolapsed intervertebral disc).
- Most commonly, this occurs in the lumbar spine in a posterolateral direction, irritating the nerve root named after the vertebra below i.e. in a L4–5 prolapsed disc, it is most commonly the fifth lumbar root which is compressed. If this nerve root is inflamed, then it can give rise to the clinical picture known as radicular pain or ‘sciatica’, to describe buttock, thigh and leg pain secondary to a spinal cause.
- Whilst the lifetime prevalence of back pain is between 50 and 80%, the prevalence of sciatica is only 4%–5%.
- Cauda equina syndrome (CES) describes central disc prolapse compressing the neural canal and giving bilateral leg symptoms, saddle anaesthesia, bladder and sometimes bowel symptoms. This is a surgical emergency and requires emergent MRI and surgical decompression.

Clinical features

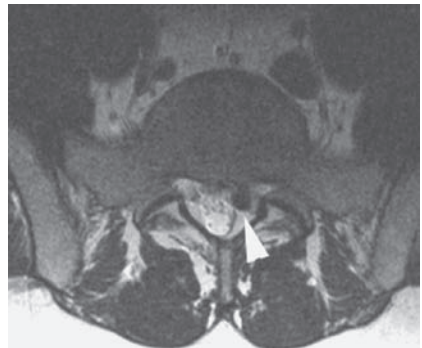
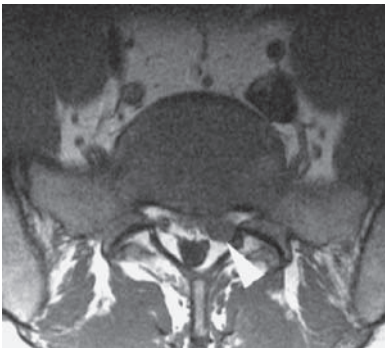
- Middle-aged patients, previously well, with periods of normal activity interspersed with incapacity, often triggered by an index event such as lifting, sport, etc. Present with back and leg pain (‘sciatica’), which is dermatomal in pattern.
 - L5 most commonly involved; produces pain posteriorly and sensory change in the lateral aspect of the leg.
 - S1 again produces posterior thigh and leg pain, but predominantly the major source of pain is in the foot with sensory disturbance on the lateral border and plantar surface.
 - L4 results in a considerable anterior thigh pain component, in addition to sensory changes on the medial border of the leg.
- A positive straight-leg raise (SLR) test indicates ‘sciatic’ pain resulting in side-to-side reduction in passive hip flexion with the knee extended. If the SLR is positive, then it can be described by the difference in degrees between the two sides. Foot dorsiflexion worsens sciatic pain – Lasegue’s test. SLR can be bilateral in central discs. The bow-string test is said to stretch the nerve roots (hip at 90°, knee at 90°) by pressing centrally in the popliteal fossa to delineate between tight hamstrings and neural inflammation/compression.

Radiological features

- Radiographs may be normal, or may demonstrate a range of changes from isolated reduced disc height to multilevel degenerative changes,



Sagittal T2 W MRI: left paracentral disc protrusion at L5/S1 (arrowhead).



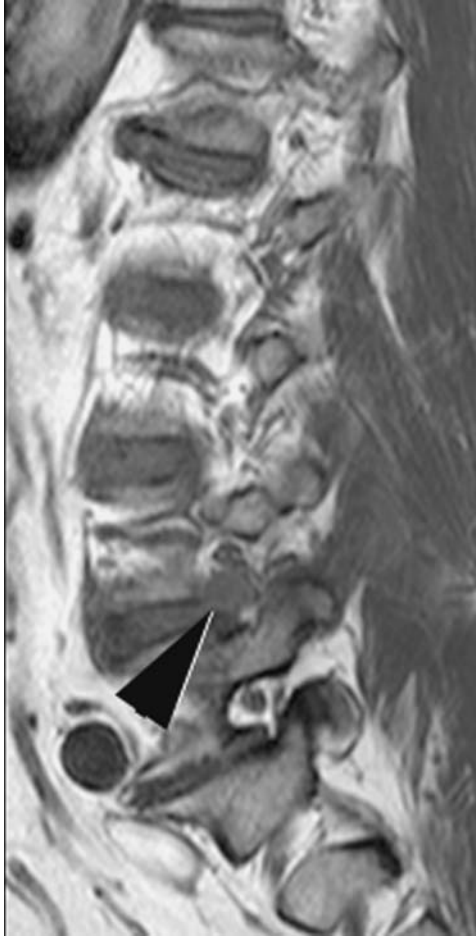
Axial T1W and T2W MRI: left paracentral disc protrusion at L5/S1 (arrowheads) compressing the left traversing S1 nerve root.

i.e. plain radiographs are a poorly sensitive investigation for identifying those at risk.

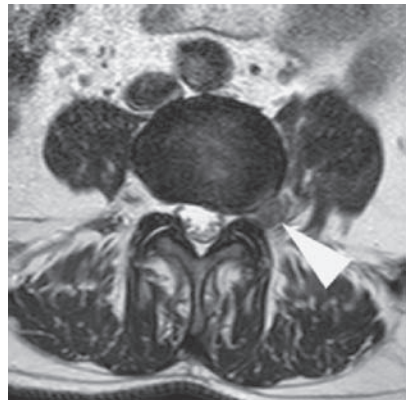
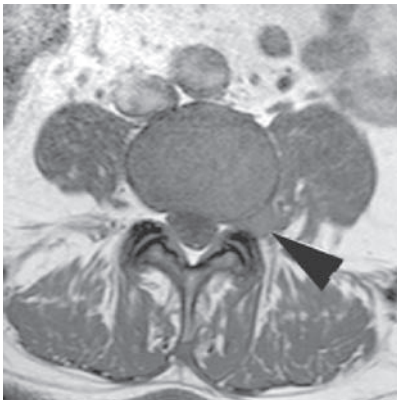
- MRI is the imaging modality of choice although, if contra-indicated, CT (myelography) can be helpful. Sagittal images demonstrate disc bulging into the spinal canal whilst the axial images reveal retropulsion of the disc material; this may be sequestered, lying free from its origin. Careful assessment of the degree of neural compression is made by the loss of demarcation around the nerve roots.

Management

- Analgesia, minimise bed-rest, mobilise and actively rehabilitate with physiotherapy – graded lumbo-pelvic core stability programme.
- Epidural steroid is still used, but this is not associated with any reduction in the rate of surgical decompression; its role is in analgesia during the natural history of a prolapsed disc. The majority of prolapsed discs do not require decompression.
- Absolute indications for surgery are progressive motor deficit and CES (emergency).
- Relative indications are failure of non-operative treatment; this can be in the early phase (lack of any response to analgesia) or after 6–12 weeks (assuming an initial improvement in symptoms with analgesia). Earlier decompression is also considered in recurrent radicular pain syndromes and those with significant acute motor disturbance.
- Surgical decompression is usually by mini open or micro-discectomy, with good relief of leg symptoms in 75%–95% (McCulloch, 1991).



Sagittal T2 W MRI: left lateral disc protrusion at L4/5 (arrowhead).



Axial T1 W and T2 W MRI: left lateral disc protrusion at L4/5 (arrowheads) displacing the exiting left L4 nerve root.

Diffuse idiopathic skeletal hyperostosis (DISH)

Characteristics

- Bone proliferation at the tendon–bone interfaces (entheses) around peripheral joints and the spine.
- Occurs relatively commonly in a middle-aged population, sometimes in conjunction with OA.
- Classically in the over 50s with a male preponderance (3 : 1).
- Association with diabetes mellitus.

Clinical features

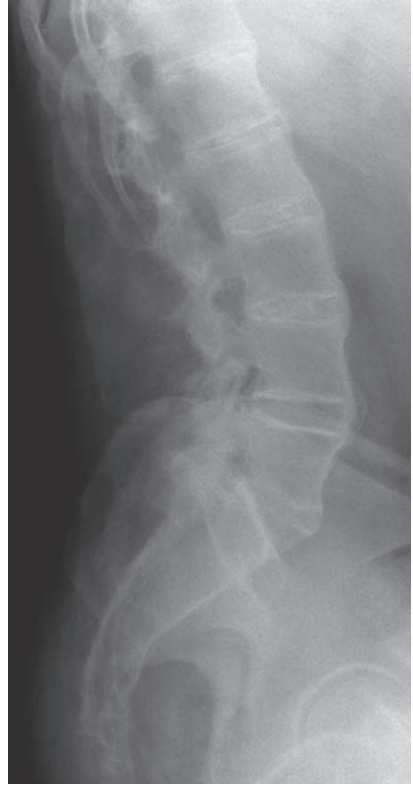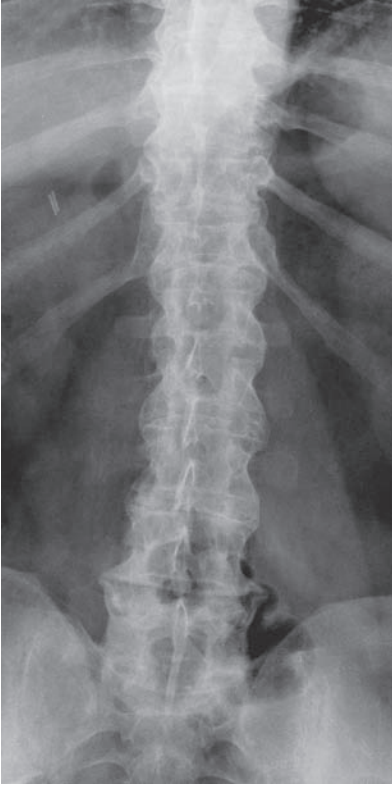- Pain and restricted movement.
- Isolated DISH is usually asymptomatic, but very often, presents alongside OA.

Radiological features

- Vertebral column – disc spaces are generally well preserved, no apophyseal ankylosis. Flowing ossification along the anterior/anterolateral aspect of at least four contiguous vertebral bodies.
- Calcaneal, olecranon and anterior patellar spurs.
- Broad osteophytes especially on the lateral aspect of the acetabulum, inferior aspect of the sacroiliac joints and superior aspect of symphysis pubis.
- Ossification of iliolumbar, sacrotuberous and sacroiliac ligaments.
- Ligamentous ossification – patellar ligament, coracoclavicular ligament and interosseous membranes.

Management

- Treat the associated osteoarthritis.



DISH: 'flowing' osteophytes along the anterior and lateral aspects of the lumbar vertebral bodies, with well-preserved disc spaces.

Dysplasia – developmental disorders

- The musculoskeletal system is commonly involved in congenital anomalies and developmental disease.
- For convenience, this diverse group of conditions can be amalgamated under the following classification (taken from *Apley's System of Orthopaedics and Fractures* – Solomon, Warwick and Nayagam – 8th edn. Arnold).
- The diversity of pathology is beyond the scope of this book and thus conditions are not discussed in detail, rather a framework is offered with chosen radiological examples.

- **Cartilage and bone growth**
 - Physeal/metaphyseal, e.g. achondroplasia, hypochondroplasia, enchondromatosis, Ollier's.
 - Epiphyseal, e.g. multiple epiphyseal dysplasia, spondyloepiphyseal dysplasia.
 - Metaphyseal/diaphyseal, e.g. metaphyseal dysplasia (Pyle's disease) with the 'Erlenmeyer flask' appearance' around the knee. Osteopetrosis = marble-bone disease.
 - Mixed, e.g. spondylometaphyseal dysplasia, nail-patella syndrome.

- **Connective tissue**
 - Generalised joint laxity.
 - Ehlers–Danlos syndrome.
 - Larsen's syndrome – marked multi-joint laxity, spinal anomalies and facial appearance.
 - Osteogenesis imperfecta.
 - Fibrodysplasia ossificans progressive.

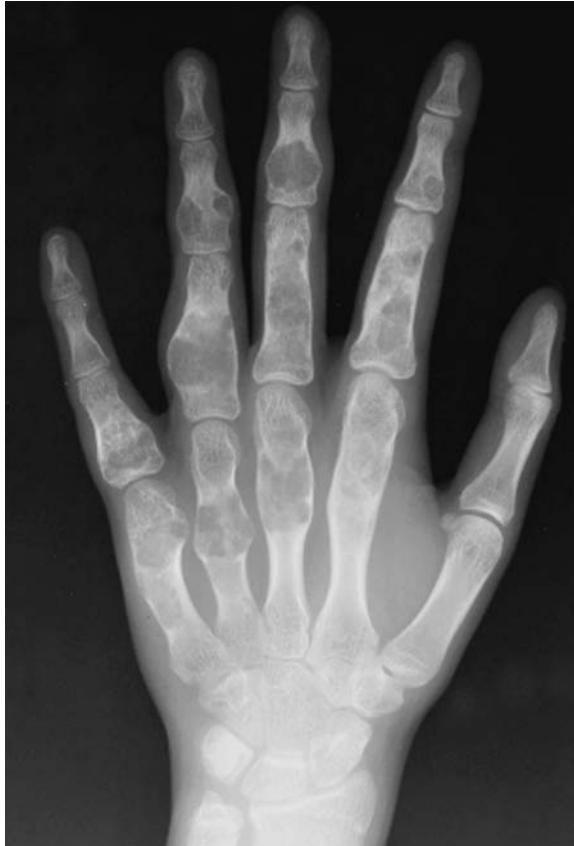- **Neurofibromatosis**
 - NF type 1 = von Recklinghausen's disease. Scoliosis is common.
 - NF type 2 – intra-cranial anomalies, rarely musculoskeletal.

- **Storage/metabolic disorder**
 - Mucopolysaccharidoses – Hurler's, Hunter's, Morquio–Brailsford syndrome.
 - Gaucher's disease – avascular necrosis, e.g. femoral head.
 - Homocystinuria.
 - Alkaptonuria.
 - Congenital hyperepruricaemia.

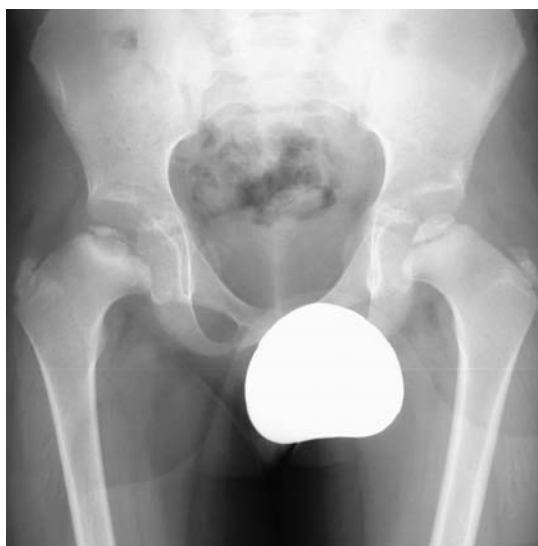- **Chromosomal disorder**
 - Down's syndrome – trisomy 21.
 - Turner's syndrome – XX0.
 - Klinefelter's syndrome – XXY.

• **Localised malformations**

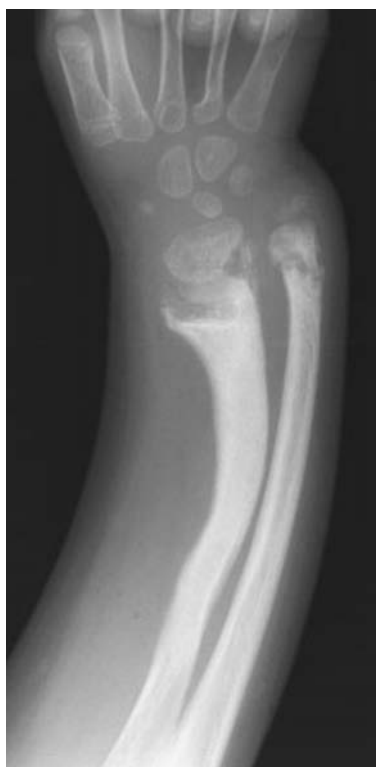- Vertebral anomalies – agenesis, dysgenesis, dysraphism.
- Klippel–Feil syndrome – congenital short neck – segmentation defect.
- Sprengel shoulder – elevation of the scapula.
- Limb anomalies, e.g. proximal femoral deficiency.



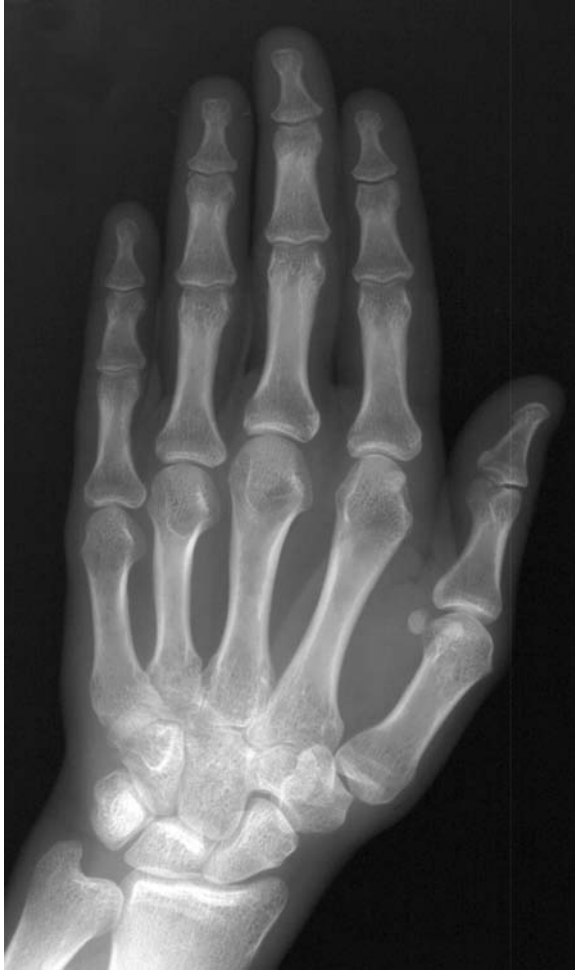Ollier's disease: multiple enchondromata within the tubular bones of the hand.



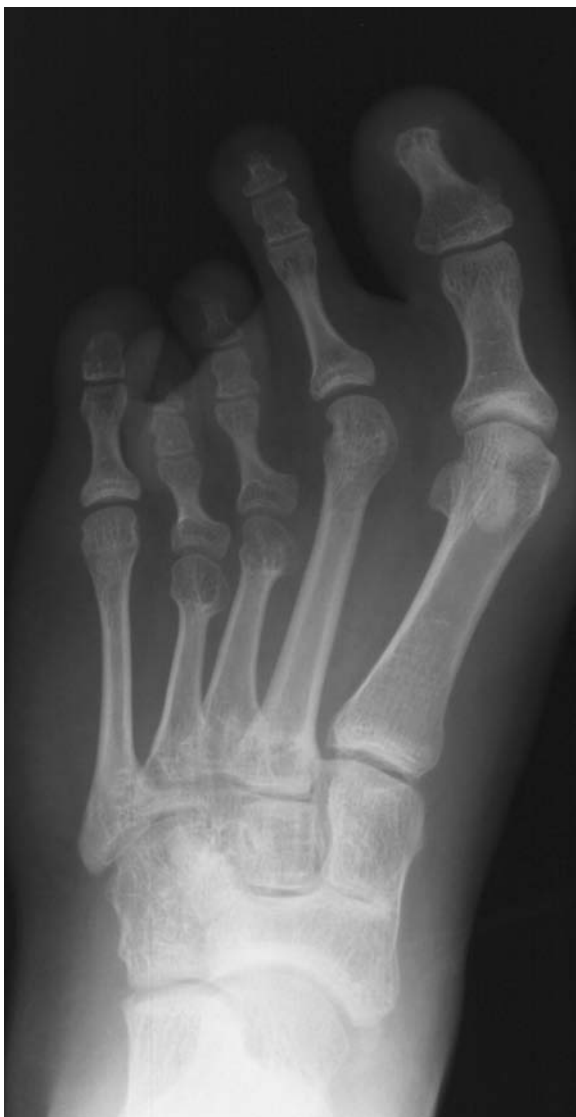Multiple epiphyseal dysplasia: irregular mottled calcification of the right femoral epiphysis, with further irregularity of the left.



Metaphyseal chondrodysplasia: shortened and bowed radius, with an irregular widened cupped metaphysis and widened epiphysis.



Turner's syndrome: 'drum-stick' distal phalanges.



Turner's syndrome: short third and fourth metatarsals.

Enthesopathy

Characteristics

- Refers to pathology at the tendon–bone interface, where the Sharpey fibres interdigitate.
- May be divided into overuse syndromes and inflammatory causes.
- Often part of a generalized inflammatory condition, e.g. rheumatoid arthritis or psoriatic arthritis.
- Often due to widespread calcification of tendon origins and insertions into bone. Particularly important in the spine where thickening of the ligamenta flava can cause cauda equina syndrome.
- Severely affected tendons may ossify.
- Associated with inherited hypophosphataemia (vitamin-D-resistant rickets), adult hypophosphataemic osteomalacia, fibrous dysplasia and Fanconi's syndrome (aminoaciduria).

Clinical features

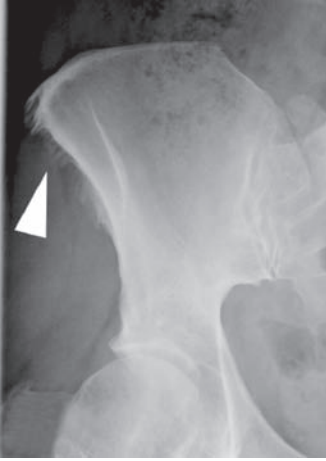- Can be painful; may be an incidental diagnosis.

Radiological features

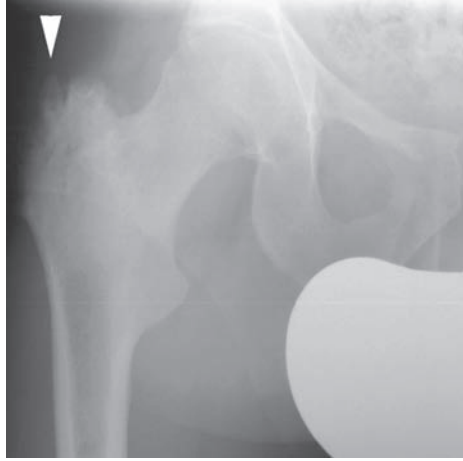
- Widespread calcification of tendon origins and insertions into bone.
- Erosions and bone proliferation (enthesophyte) may be seen.

Management

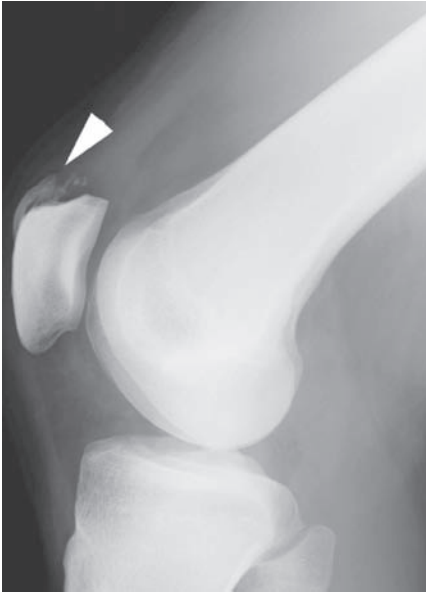- Treat any underlying metabolic condition, then symptomatic relief.



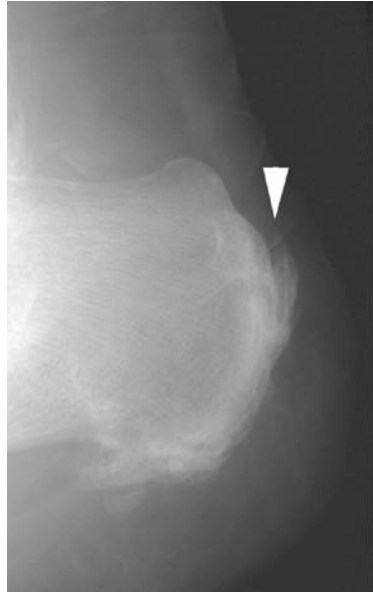
Iliac enthesopathy.



Trochanteric enthesopathy.



Patellar enthesopathy.



Calcaneal enthesopathy.

Gout

Characteristics

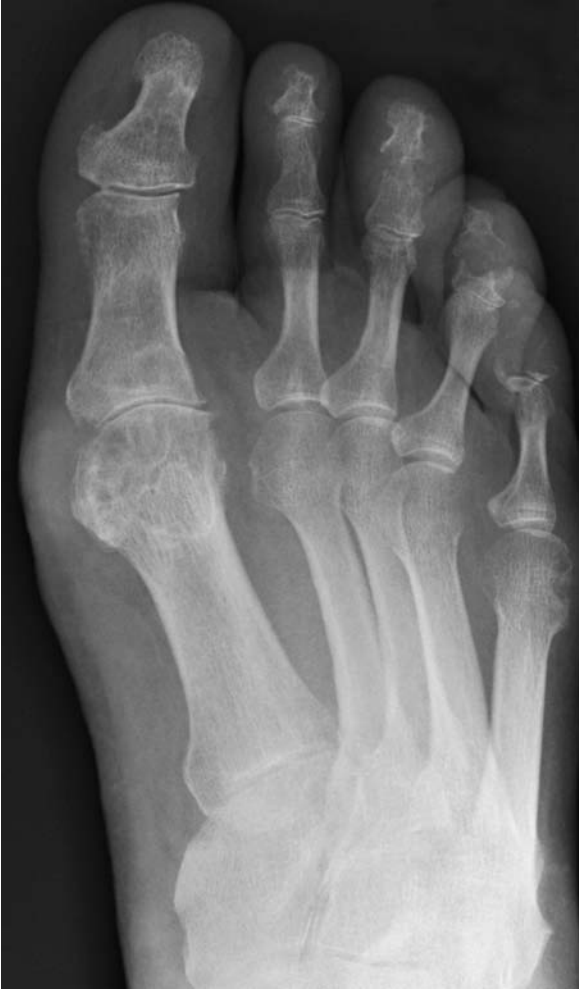- Occurs in approximately 1% of the population; male : female ratio of 20 : 1.
- Characterised by a pathological reaction to monosodium urate monohydrate crystals by the joint or periarticular tissues.
- Increases with age and serum uric acid levels, although only a fraction of patients with hyperuricaemia will develop gout.
- Primary gout – overproduction or under-secretion of uric acid. More frequently seen in men and is the commonest cause of inflammatory arthritis in men over 40 years of age.
- Secondary gout – Acquired conditions lead either to over-production (myeloproliferative disorders) or under-excretion of uric acid (renal failure). Drugs such as aspirin and diuretics can precipitate acute attacks.

Clinical features

- Characterised by severe pain, classically waking the patient from sleep.
- The joint is swollen and very sensitive to contact (patient may not even tolerate wearing a sock).
- Typically affects a single distal joint, with the first MTP joint affected in >50% of cases.
- Other affected joints include the ankle, knee, midfoot, small joints of the hand, wrist and the elbow. Gouty tophi tend to be a late sign.
- Fever, malaise and confusion can occur, particularly in the elderly, and if a large joint is affected.
- May be difficult to differentiate from sepsis; however, the onset of gout is typically hyperacute.
- Although polyarticular attacks are rare, acute attacks may be followed by involvement of other joints. This is thought to be secondary to an acute-phase response.
- Attacks tend to become more frequent and involve multiple sites over time.
- Diagnosis is confirmed by the presence of negatively birefringent crystals in synovial fluid.

Radiological features

- Radiological features usually not seen until 6–12 years after initial attack.
- In the acute attack radiographs are often normal or show soft-tissue swelling. An effusion may be apparent.
- Bilateral effusions of the olecranon bursae is pathognomonic of gout.
- Chronic gout is typified by eccentric peri-articular ‘punched out’ erosions, uniform joint-space narrowing and changes similar to osteoarthritis.
- Calcified tophi are seen around the distal phalanges.

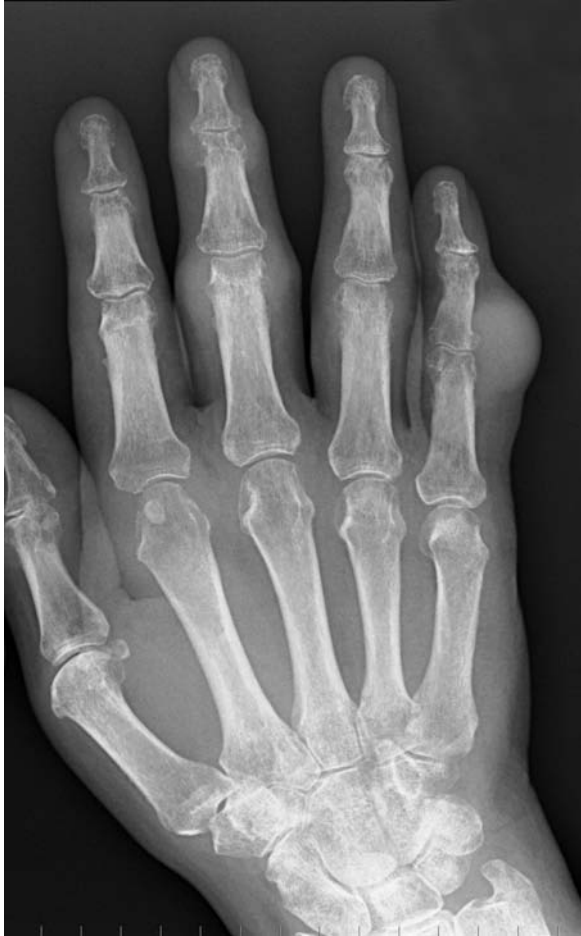

Juxta-articular erosions seen at the DIP Js of the third, fourth and fifth toes, and first MTPJ.

- Chondrocalcinosis (e.g. menisci) results in secondary osteoarthritis.
- Bone density tends to be normal unless there is severe joint restriction from pain.

Management

- Aspiration to confirm diagnosis with first presentation.
- Acutely manage with NSAIDs and rest. If a tense effusion is present, aspiration \pm steroid injection can be very effective; however, beware of sepsis.
- Oral colchicine is less well tolerated.
- Long-term management involves removal of precipitating/aggravating factors.
- Drug therapy such as allopurinol aims to reduce serum uric acid levels.



Gout. 'Punched out' juxta-articular erosions seen at the DIP J of the middle finger. Note the marked soft tissue swelling over the PIP J of the little and middle fingers, due to early tophi formation.

Haemophilia

Characteristics

- Congenital disorder of coagulation with a resulting reduction in factor VIII (haemophilia A) or factor IX.
- Haemophilia A is more common affecting 1 in 10 000.
- In haemophilia A the abnormal gene is located on the X-chromosome, making this a sex-linked disorder.

Clinical features

- Spectrum of disease. Severity depends on the amount of factor present.

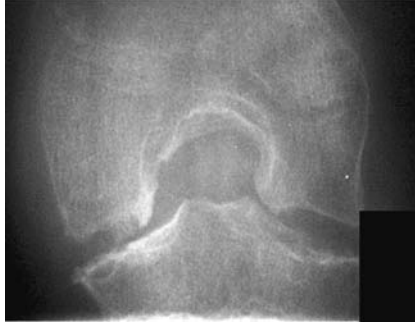
Severity	Factor VIII/IX level	Presentation
Mild	10%–50%	Bleeding from large insult (surgery)
Moderate	2%–10%	Bleeding from mild trauma
Severe	<2%	Spontaneous haemarthrosis and muscle haematomas

- Spontaneous haemarthrosis often without obvious trauma. Knees, elbows, hips and ankles are most commonly affected. Patients present with a hot swollen joint and can often pinpoint the onset of bleeding.
- Recurrent bleeds result in cartilage loss and osteoarthritic changes. Progressive loss of function.
- Muscle haematomas can occur in almost any muscle but are commonly seen in the calf. A compartment syndrome may occur acutely. With time, fibrosis and subsequent contractions can be problematic.
- Complications such as a mononeuropathy are not uncommon due to direct pressure upon a nerve.
- Remember bleeding can occur almost anywhere; beware of the unconscious haemophiliac patient with an intracerebral haemorrhage following relatively minor head trauma.

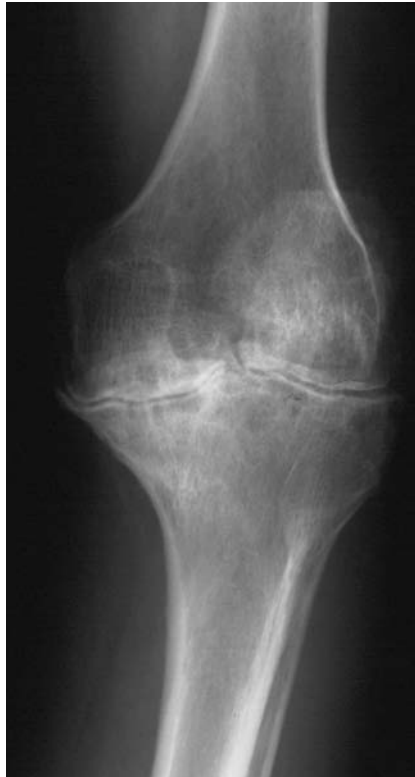
Radiological features

- Radiographically, five stages of severity are seen in haemophilia:
 - soft-tissue swelling.
 - osteoporosis.
 - osseous lesions.
 - cartilage destruction.
 - joint disorganisation.
- similar to osteoarthritis with loss of joint space, marginal osteophyte formation, subchondral cysts and subchondral sclerosis
- ‘squared-off’ joints, e.g. patellofemoral joints

- widened femoral notch
- periarticular erosions
- massive subperiosteal and intraosseous bleeding can lead to the formation of large expansile lesions, termed haemophilic pseudotumours.



Haemophilia: widened intercondylar notch.



Haemophilia: advanced degenerative changes, with complete loss of joint space, resulting from repeated haemarthrosis.

Management

- Early treatment involves intravenous factor replacement. Most patients will carry a card documenting their disease and treatment requirements.
- Simple measures such as ice, bed rest and splinting of the affected site or joint will help reduce further bleeding.
- Once bleeding has settled, priority should be given to mobilisation and optimising function. Physiotherapy is invaluable.
- Aim to avoid muscular atrophy if possible.
- In recurrent bleeds consider synovectomy.
- Long-term joint management similar to osteoarthritis.

Hyperparathyroidism

Characteristics

- Parathormone excess may be primary, secondary or tertiary.
- Primary Hyperparathyroidism (HPT) is most common, characteristically occurring in women (3 : 1) over 50. A single adenoma accounts for >90% of all cases; carcinoma is rare (1%). Parathyroid hyperplasia usually occurs in multiple endocrine neoplasia syndromes.
- Secondary HPT results secondary to prolonged hypocalcaemia. Calcium levels are normalised at the expense of bone turnover. Associated with chronic renal failure, osteomalacia and malabsorption states.
- Continuous stimulation of the parathyroid glands can result in adenoma formation and autonomous secretion of parathormone. This is known as tertiary hyperparathyroidism.

Clinical features

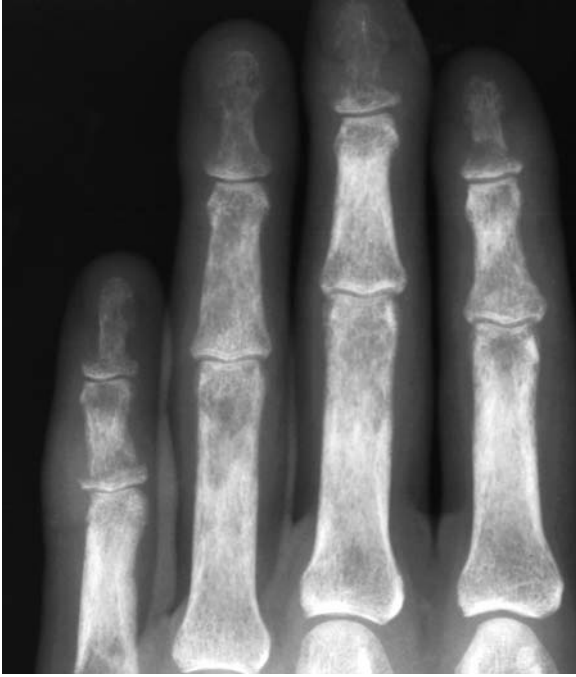- May be asymptomatic and only diagnosed from biochemical tests.
- Features tend to be related to hypercalcaemia. The adage of 'moans, bones, stones and abdominal groans' still applies.
- Polydipsia, polyuria, lethargy, somnolence, confusion and depression are common. Suspect in the patient presenting with renal colic as up to 20% of recurrent stone formers may have underlying HPT.
- Can cause anorexia, nausea, constipation and even peptic ulceration.

Radiological features

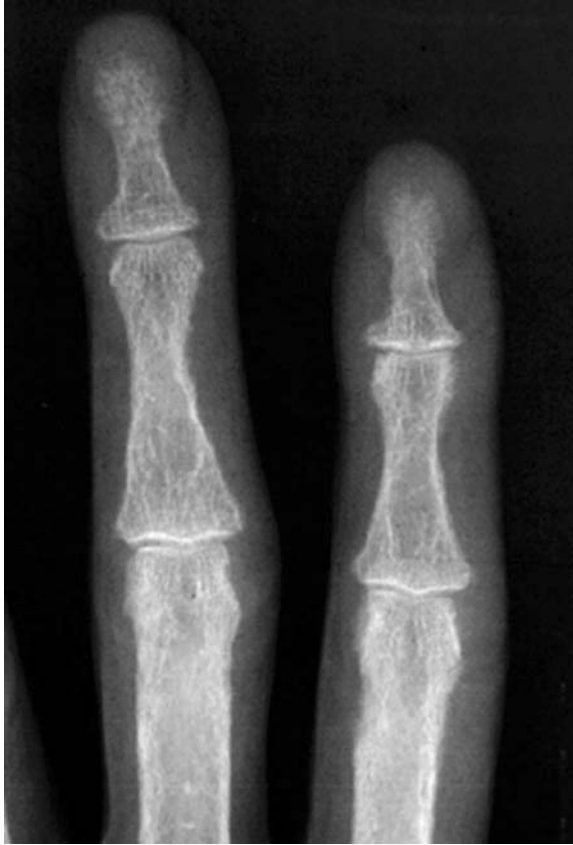- Subperiosteal bone resorption, seen as a lace-like pattern, occurs along the bony cortex. The earliest changes are seen at the phalangeal tufts and radial aspect of the middle phalanx of the index and middle fingers, clavicles and proximal humerus.
- Bone softening results in vertebral wedging and bowing of long bones.
- Brown tumours – localised replacement of bone by vascular fibrous tissue secondary to the action of osteoclasts. Commonest in the jaw, pelvis and rib.
- Soft tissue calcification – occurs more commonly with secondary HPT. May result in chondrocalcinosis of hyaline and fibrous cartilage (wrist, knee menisci, shoulder and hip).
- Osteosclerosis – again seen more commonly in secondary HPT. Predilection for the axial skeleton – 'rugger-jersey spine' due to vertebral endplate sclerosis.
- Periosteal new bone formation.

Management

- In the acute setting management is directed towards rehydration. In the very sick forced diuresis, steroids and haemodialysis have been used.
- Bisphosphonates require 2–3 days for onset of action.
- Treat the cause. Ultrasound and sestamibi isotope scans are used to locate the adenoma. Parathyroidectomy indicated after careful consideration.



Hyperparathyroidism: tuft resorption.



Hyperparathyroidism: subperiosteal resorption along the radial aspects of the middle phalanges of the ring and middle fingers. This is virtually pathognomonic hyperparathyroidism.

Hypertrophic pulmonary osteoarthropathy

Characteristics

- Rare condition occurring secondary to various pathological states such as bronchogenic carcinoma, chronic chest infections, inflammatory bowel and liver disease.
- Thought to occur due to release of vasoactive mediators not metabolised by lung.

Clinical features

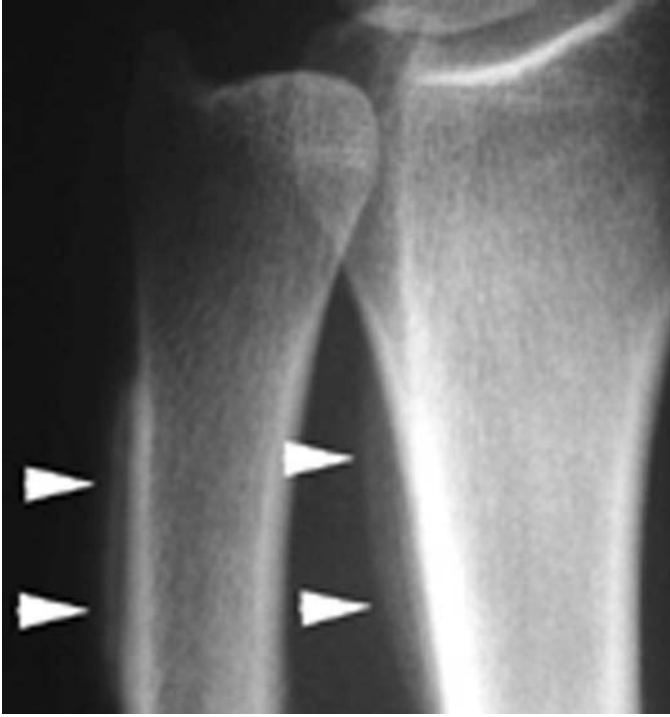- Patients present with a burning pain associated with soft-tissue swelling and joint stiffness.
- Ankles, wrists, knees and elbows are commonly affected.
- Clubbing of fingers and toes may be evident. Limb hypertrophy may occur secondary to soft-tissue swelling.
- Peripheral neurovascular effects include cyanosis, blanching, flushing, paraesthesia and hyperhidrosis.

Radiological features

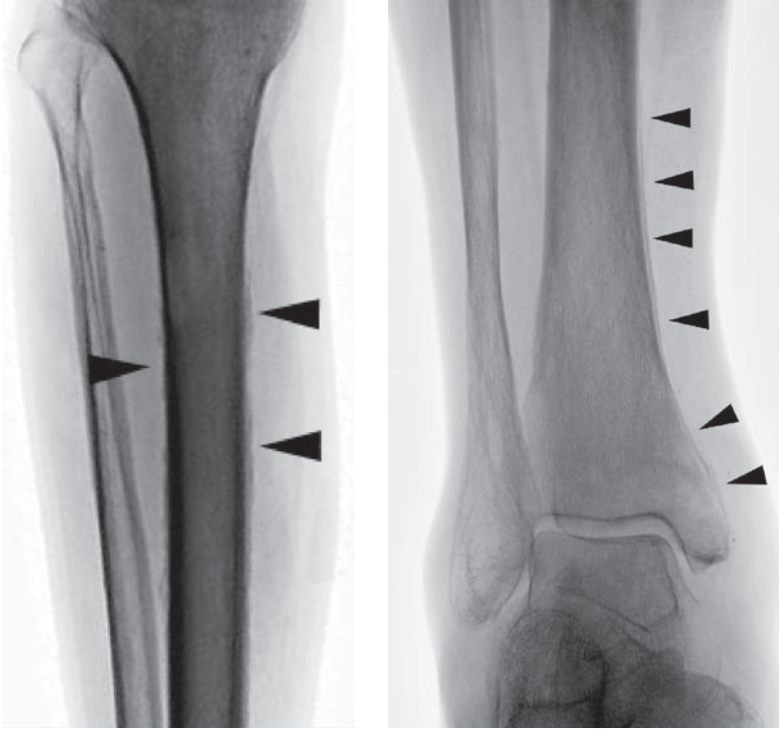
- Periosteal new bone formation at the diaphysis. Commonest in the tibia and fibula. Other common sites include radius and ulna, proximal phalanges, femur and pelvis.
- Soft tissue swelling around the distal phalanges.
- A bone scan demonstrates symmetrical periosteal uptake.
- Cross-sectional imaging is performed to identify the underlying cause.

Management

- Directed at treatment of the underlying cause.
- Regression of the periosteal reaction may be seen after treatment.



HPOA: periosteal new bone formation along the distal radius and ulna (arrowheads).



HPOA: periosteal new bone formation along the mid and distal tibia and fibula. Note the use of the inverted view.

Irritable hip / transient synovitis

Characteristics

- A transient synovitis.
- The commonest cause of non-traumatic hip pain.
- Usually unilateral with an unknown cause.
- Age range: 9 months to 18 years with a peak at 5 years.
- Many patients have an antecedent illness such as a respiratory-tract infection.
- Important to exclude septic arthritis.
- Consider tuberculosis of the hip in the appropriate clinical settings.

Clinical features

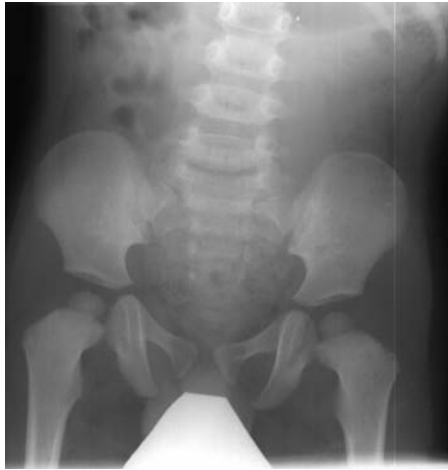- Presents in a variety of ways including inability to bear weight or a painful hip/thigh/knee.
- Spurious history of trauma.
- Onset may be sudden or gradual over several days.
- Symptoms tend to settle spontaneously after several days.
- Apyrexia.
- On examination passive movements are usually normal.

Radiological features

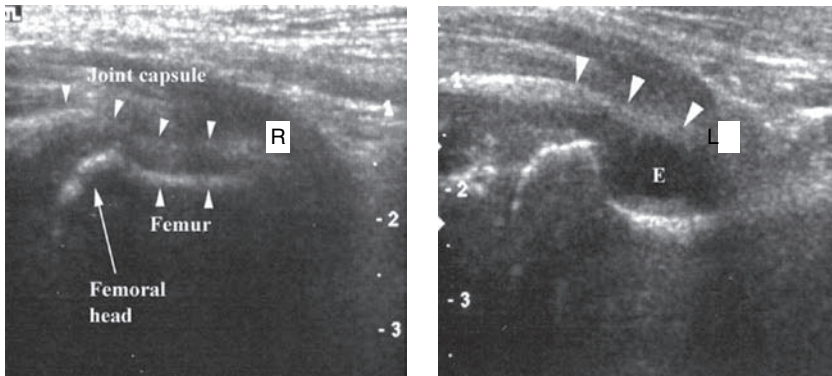
- Radiographs of the knee, femur and hip are usually normal.
- Occasionally a hip effusion can be seen on the plain radiograph.
- Ultrasound is the imaging modality of choice (>95% sensitivity). A difference of >3 mm in joint space between the normal and affected sides should be viewed as pathological.
- Ultrasound is poor at differentiating between a simple effusion, haemorrhage and sepsis.

Management

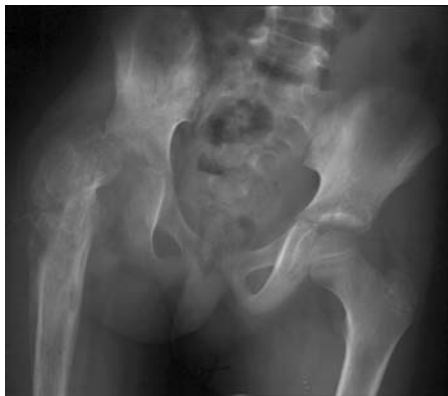- Transient synovitis is a diagnosis of exclusion.
- When the diagnosis is unclear, or the patient cannot bear weight, consider septic arthritis.
- Ultrasound guided aspiration of the joint fluid allows definite assessment.
- If the history and examination are consistent with the diagnosis, and investigations, including WCC and ESR, are normal, the patient can often be discharged to the care of a responsible adult with instruction to rest, and simple analgesia.
- Follow-up within 72 hours unless symptoms completely resolve.
- Admission for observation is sometimes needed.



Beware, the plain radiograph may appear normal.



However, the USS demonstrates a significant a left hip effusion (E).



End result of a missed right septic arthritis.

Juvenile idiopathic arthritis

Characteristics

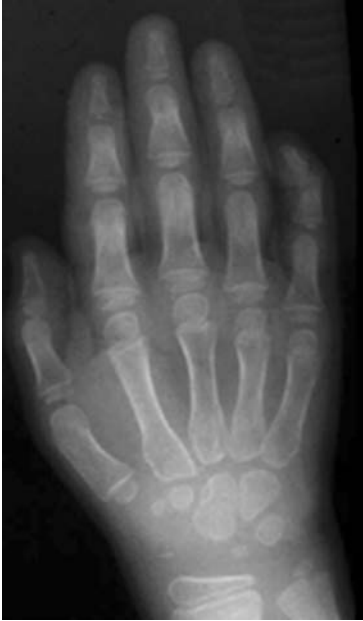- Defined as prolonged (>3 months) swelling of one or more joints in the absence of other causes, and presenting below the age of 16.
- Also known as JCA (juvenile chronic arthritis – British term) and JRA (juvenile rheumatoid arthritis – American term).
- Classified as pauci-/oligo-articular, polyarticular and systemic (Stills' disease).
- Cause unknown, but links with genetic loci and possible infectious agents.
- Pathology is synovitis, progressing to fibrosis and ankylosis.
- Beware of 'red joints' (rare in JIA) and leukaemia presenting with joint pains.
- Outcome – 50% normal, 25% mild disability, 25% severe arthropathy.

Clinical features

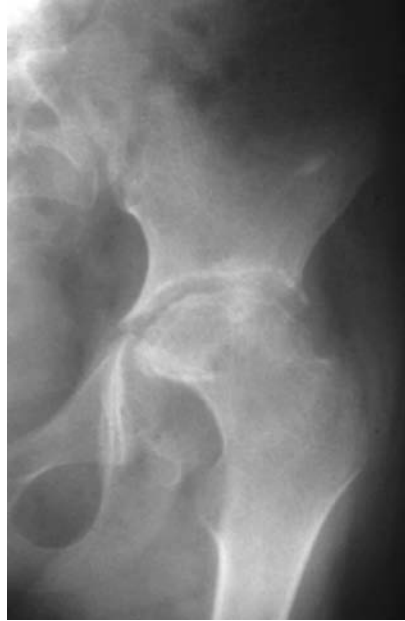- Systemic (20%) – usually <3 years old, M : F = 1 : 1.
 - Pyrexia, pain, rash, and lymphadenopathy are most common, but look for iritis, hepatosplenomegaly and pericarditis.
- Polyarticular (10%) – older children, F > M.
 - Morning stiffness or 'gelling' after a snooze with pain and swelling in multiple joints.
- Pauciarticular (70%) – usually <6 years old, F ≫ M.
 - Involvement of up to four joints in the first 6 months.
 - Two types:
 - Type I – mainly females aged 1–4 (antinuclear antibody positive).
 - Type II – mainly boys (positive for HLA B27).
 - Important to exclude (usually painless) chronic iritis – can cause blindness – look for loss of pupil circularity.
- Most common joints affected are the knee, ankle, and then fingers.

Radiological features

- X-rays used to exclude tumour/infection in the early stages.
- Radiological signs similar to rheumatoid arthritis (except large joint involvement occurs first, with late onset of bony changes).
- Periarticular soft-tissue swelling and juxta-articular osteoporosis.
- Articular erosions at ligamentous/tendinous insertion sites.
- Joint destruction may resemble neuropathic joints.
- Ankylosis in carpal joints.
- Subluxation of atlantoaxial joint (66%).



Juvenile idiopathic arthritis:
periarticular soft-tissue swelling,
with associated juxta-articular
osteopaenia.



Juvenile idiopathic arthritis:
periarticular erosions left hip joint.

Management

- Specialist paediatric rheumatology and ophthalmology review.
- Analgesia – including NSAIDS.
- Splintage (night time) to prevent joint contractures and physiotherapy.
- Intra-articular steroid controls synovitis, preventing joint destruction.
- Methotrexate for multiple joint involvement or recurrent disease.
- Systemic pulsed steroid therapy for resistant disease.
- Anti-TNF (e.g. Etanercept) can stop erosive joint destruction.
- Arthroplasty (e.g. knee/hip) or arthrodesis (e.g. wrist/fingers) for painful destroyed joints.

Langerhans-cell histiocytosis

Characteristics

- Poorly understood spectrum of conditions.
- Characterised by proliferation of Langerhans cells (similar to mononuclear macrophages).
- Can occur at any age; most present in childhood.
- Sub-divided into eosinophilic granuloma (80%), Hand-Schüller-Christian disease (10%) and Letterer-Siwe disease (10%).

Clinical features

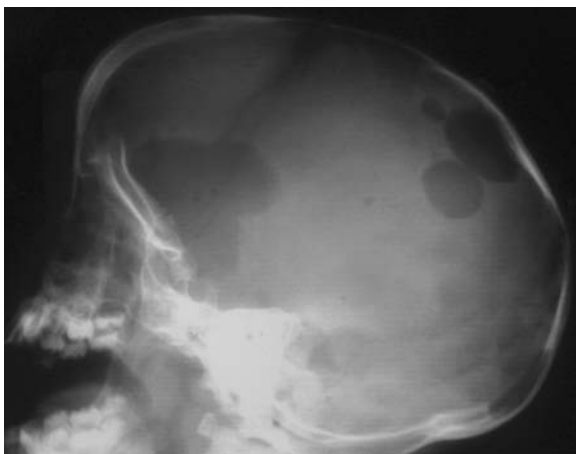- *Eosinophilic granuloma* – relatively benign. Often presents with non-specific bone pain in the 5–10 year age group.
- *Letterer-Siwe disease* – acute disseminated form tends to present early in infancy with wasting, hepatosplenomegaly and lymphadenopathy. Pancytopenia common.
- *Hand-Schüller-Christian disease* – chronic form. Presents in the 5–10-year-old group with diabetes insipidus, exophthalmos and lytic skull lesions.

Radiological features

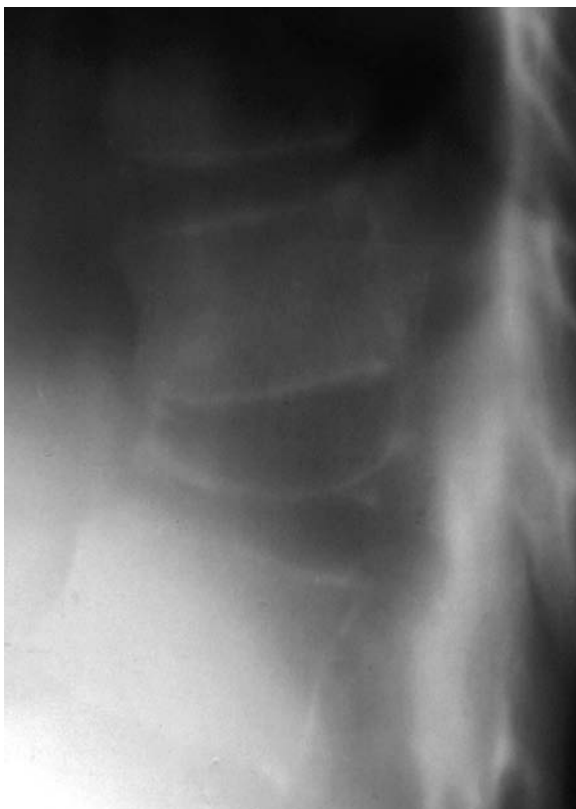- Lesions are usually well defined with a lucent centre and serrated and bevelled edge. A sclerotic margin is seen in the healing phase. True expansion is rare.
- Lesions common in skull and axial skeleton.
- Skull lesions often appear ‘punched out’ and may coalesce to form a geographical pattern. Differential inner- and outer-table involvement may give the appearance of a hole within a hole.
- *Vertebrae plana* – vertebral bodies appear flattened with a preserved disc height.
- *Long bones* – usually diaphyseal, respecting the epiphyseal plate and joint. Again, lytic with a sclerotic rim.
- Mandibular involvement can lead to the appearance of ‘floating teeth’.

Management

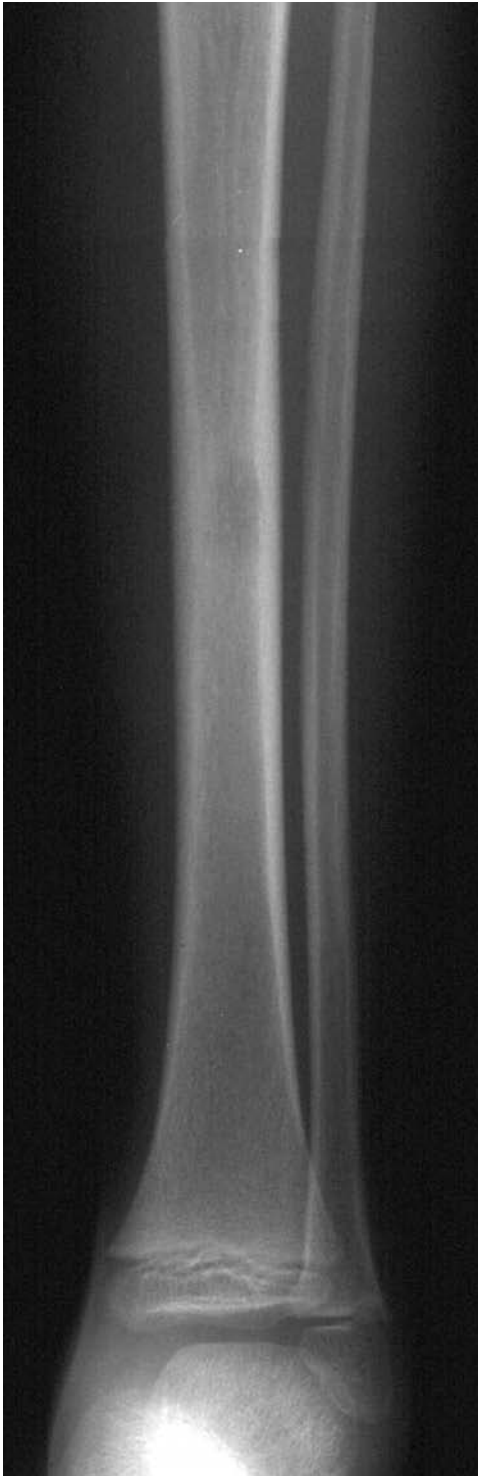- Orthopaedic management generally targeted to obtaining a definitive tissue diagnosis.
- If accessible, excision/curettage or radiotherapy should be considered.
- Chemotherapy for aggressive forms.



Langerhans-cell histiocytosis: multiple well-defined lytic areas, with serrated margins, within the skull vault.



Langerhans-cell histiocytosis: vertebra plana with preserved disc height.



Langerhans-cell histiocytosis: small lytic lesion within the mid tibial diaphysis.

Lymphoma of bone

Characteristics

- Synonymous with reticular cell sarcoma and histiocytic lymphoma.
- Can occur at any age. Male to female ratio of 2 : 1.
- Approximately 5% of all primary malignant childhood bone tumours.
- Bone marrow involvement occurs more frequently in non-Hodgkin's lymphoma than in Hodgkin's disease.

Clinical features

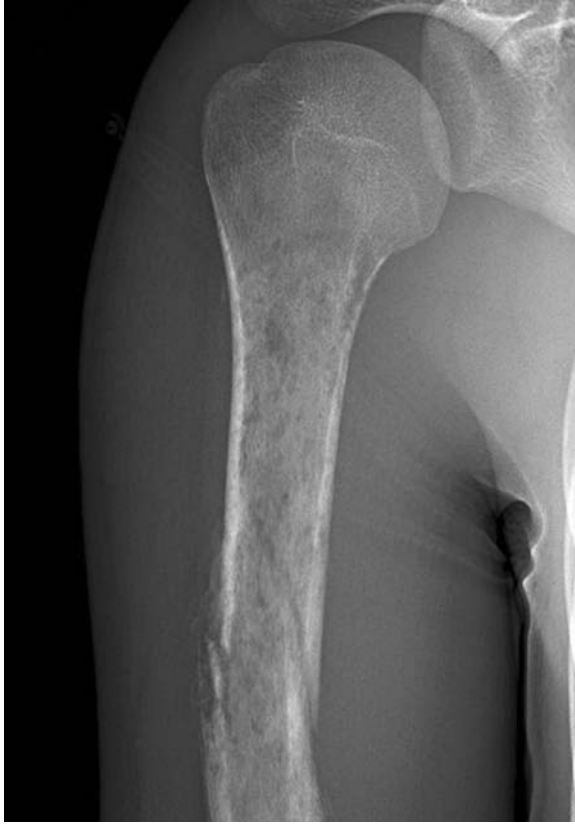- Patient may appear relatively well despite the presence of large lesions.
- Often present secondary to a pathological fracture.

Radiological features

- Earliest sign is cancellous bone erosion, seen in the diaphysis or metaphysis.
- Mottled permeative lesions, with cortical destruction occurring late.
- Lamellated/sunburst periosteal reaction similar to, but less florid than Ewing's sarcoma.
- Reactive new bone formation.
- Associated soft-tissue mass.

Management

- Orthopaedic management often targeted to deal with pathological fractures.
- Resection rarely curative.
- Prophylactic fixation may be of benefit in certain circumstances (load-bearing limb with lesion susceptible to pathological fracture).
- Medical treatment with chemotherapy and radiotherapy.



Lymphoma: extensive permeative lesion within the proximal humeral diaphysis with a pathological fracture.

Characteristics

- Approximately 100 times more common than primary bone tumours.
- Spread occurs via blood (arterial and venous), direct extension (rare) and lymphatic (rarer still).
- Common sites include vertebrae, pelvis, proximal femur and humerus.
- Common primary:
 1. Adult male – prostate, lung and kidney.
 2. Adult female – breast, lung and kidney.
 3. Children – neuroblastoma, leukaemia and lymphoma, medulloblastoma, sarcoma and Wilm's tumour.

Clinical features

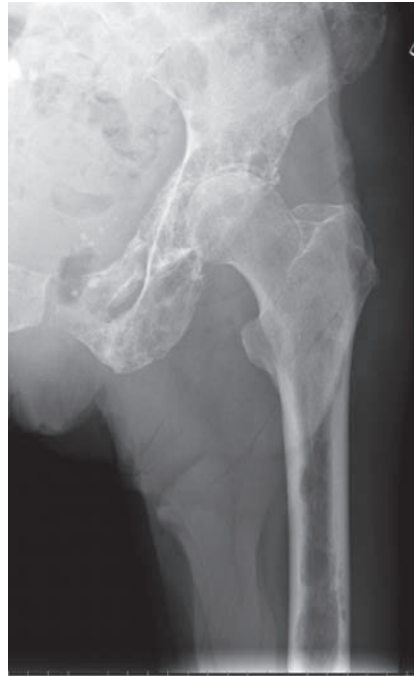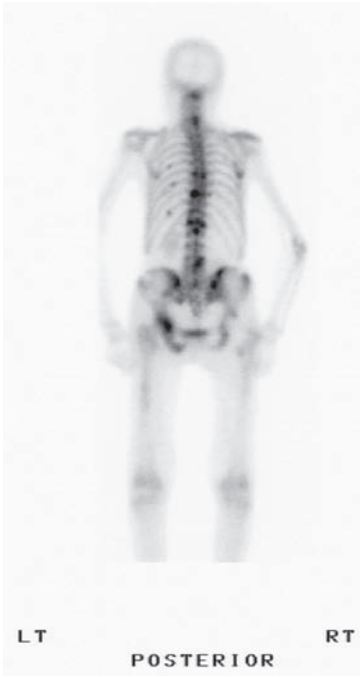
- Often depend on the primary. May be an incidental finding on staging.
- Rest pain and night pain are 'red flag' symptoms.
- Bony pain, systemic upset and pathological fractures.
- Always treat the sudden onset of pain in the elderly with suspicion. Symptoms of hypercalcaemia include depression, confusion, anorexia, nausea, weakness, abdominal pain and polyuria (all commonly seen in the elderly!).

Radiological features

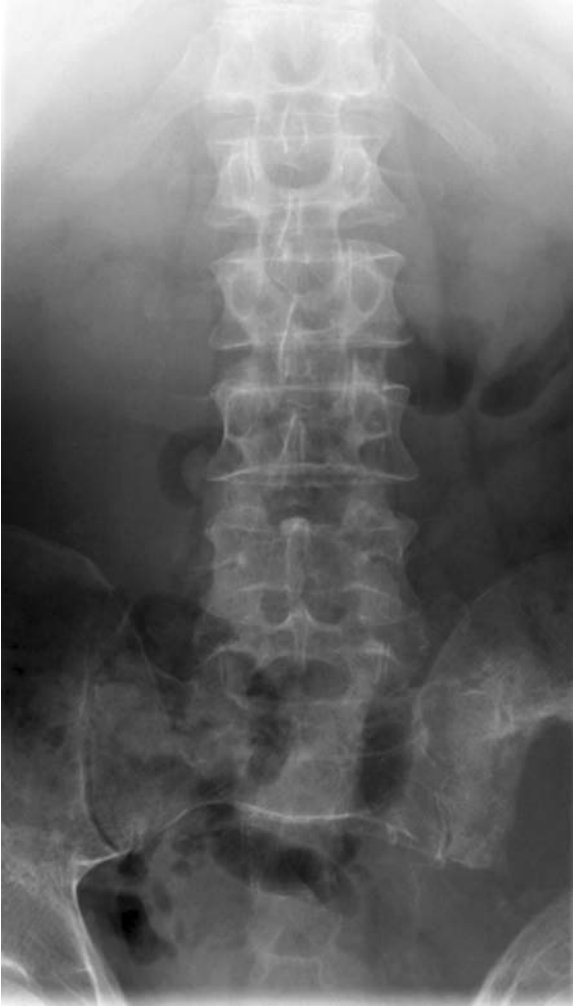- Again, often depends on the aggressiveness of the primary tumour.
- Metastases may be lytic, sclerotic or mixed.
- Bone destruction may be permeative, geographic or 'moth-eaten'.
- Zone of transition (area between normal and abnormal bone) usually wide, signifying aggression.
- Common 'lytic' metastases – kidney, lung, thyroid and breast primary.
- Common 'sclerotic' metastases – prostate, breast and stomach.
- Rare sclerotic – Hodgkin's disease, carcinoid, medulloblastoma, neuroblastoma and transitional cell carcinoma.
- Bone scan – often useful to define distribution of disease. Correlate with plain radiographs.

Management

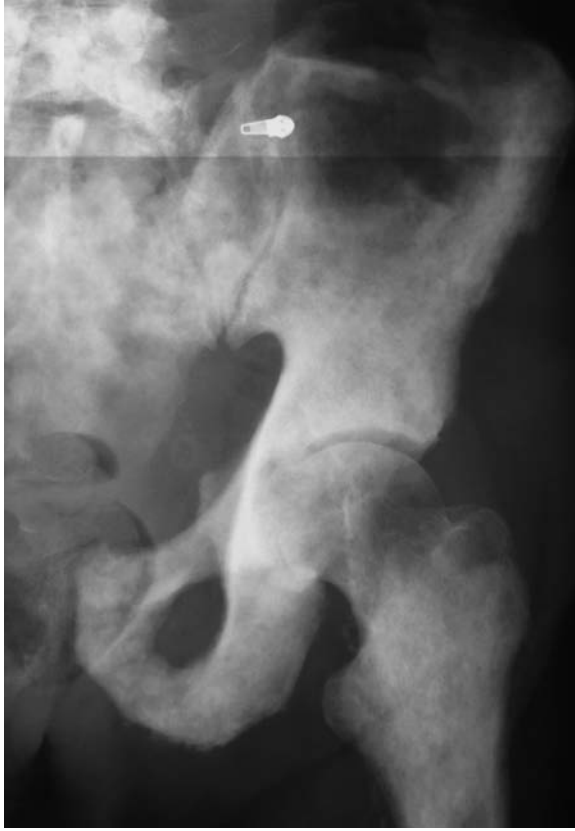- Chemo/radiotherapy depending on sensitivity.
- Fixation of impending and pathological fractures – beware treating isolated metastases – isolated lesions may be primary tumours or metastases amenable to resection – discuss with a tumour unit.



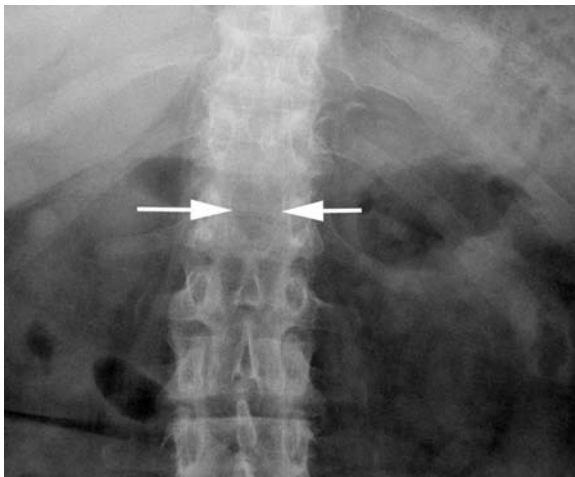
Widespread metastases in a patient with breast carcinoma.
Bone scan: multiple focal areas of isotope uptake within the axial skeleton and ribs. Plain X-ray: corresponding lytic lesions seen within the left superior and inferior pubic rami, ischial tuberosity, acetabulum and proximal femur.



Large lytic metastasis of the left innominate bone in a patient with renal carcinoma.



Widespread bony sclerosis due to prostate carcinoma.



Lytic metastasis at L1. The spinous process is absent (arrows).

Multiple myeloma

Characteristics

- Commonest primary malignant tumour in adults.
- >95% occur over 40 years of age. Extremely rare before 30.
- Male predominance 2 : 1.
- Usually occurs in multiple sites (vertebra, ribs, skull, shoulder, pelvis and long bones). Solitary plasmacytomas seen in vertebral bodies, pelvis and femur.

Clinical features

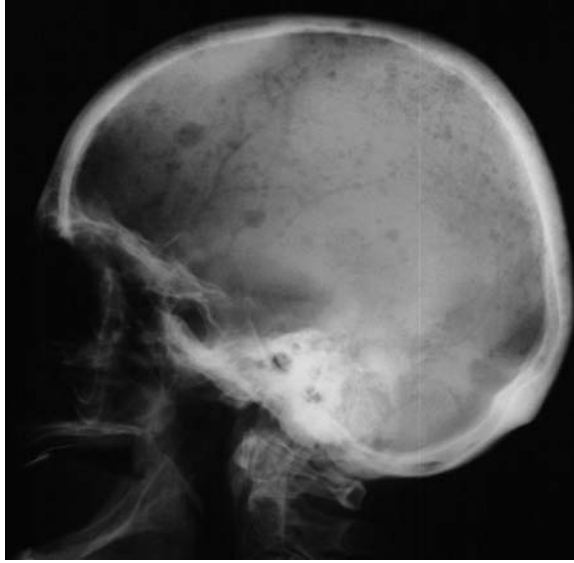
- Majority present with bone pain. Beware adult with back pain which has changed in character or is associated with systemic upset (fatigue, weight loss).
- May present with anaemia, renal impairment, hypercalcaemia and proteinuria.
- Approximately 50% will have Bence–Jones proteins in the urine.
- Serum electrophoresis may show monoclonal bands.

Radiological features

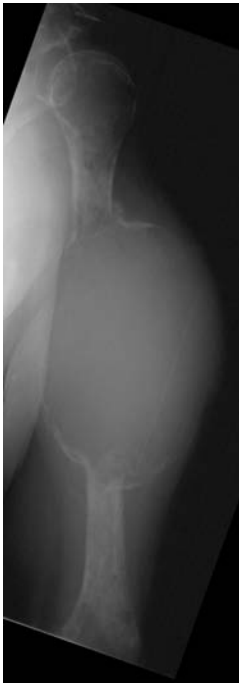- Early features include widespread osteoporosis with prominence of the trabecular pattern especially in the spine.
- Osteolytic lesions may be punched out (skull and long bones) or expansile (long bones, ribs and pelvis).
- Vertebral bodies are generally involved prior to the pedicle involvement in comparison to metastatic involvement.
- Involvement of the mandible; rare in metastatic disease.
- Subtle soft-tissue masses may be detectable adjacent to areas of bone destruction.
- Sclerotic lesions are rare and may be secondary to treatment.
- Bone scans can be normal and need correlation with plain radiographs.
- MRI – shows replacement of normal marrow (sensitive).

Management

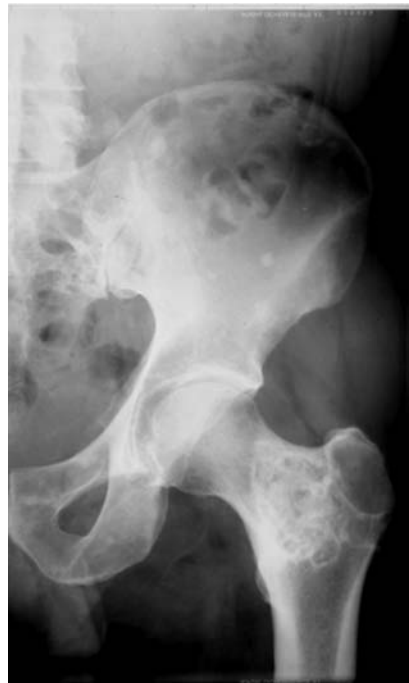- Myeloma management includes adequate hydration (to minimise renal problems), combination chemotherapy and bone-marrow transplant.
- Localised bone pain treated with radiotherapy.
- Prophylactic intramedullary nailing of impending long-bone fractures.



Myeloma: 'pepper pot' skull. Multiple lytic lesions within the skull vault.



Myeloma: markedly expansile lesion of the mid left humerus.



Myeloma: post-treatment. Large sclerotic myeloma deposit within the left femoral neck and inter-trochanteric area, and several similar smaller lesions within the left innominate bone.

Myositis ossificans

Characteristics

- Also known as heterotopic ossification.
- Benign condition involving ossification of muscle and other soft tissues.
- Majority of lesions described are secondary to trauma, including operative trauma such as total hip replacement.
- Calcification occurs within the traumatised tissue.
- Non-traumatic and hereditary forms are also described.
- Common sites involved are the large muscles of the extremities (80%), chest and back.

Clinical features

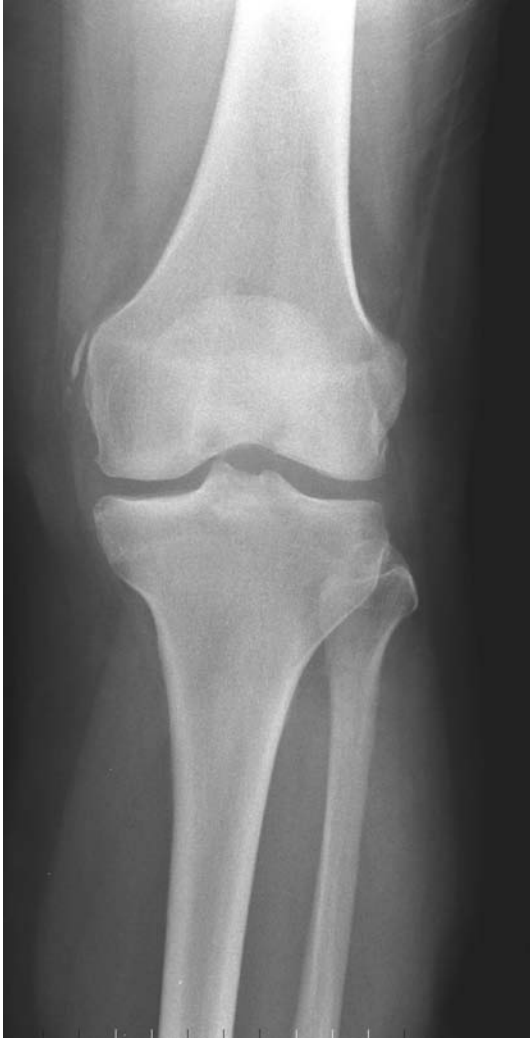- Painful tender soft tissue mass – important to have a clear history of trauma, otherwise the suspicion of malignancy must be considered.
- Decreased range of movement of the involved musculo-tendinous unit, which reduces the range of the joints supplied by that unit.
- Pain decreases with time unlike most sinister pathology.
- May be asymptomatic and diagnosed incidentally.
- Can occur in periarticular situations, e.g. around the elbow following a paediatric supracondylar fracture.

Radiographic features

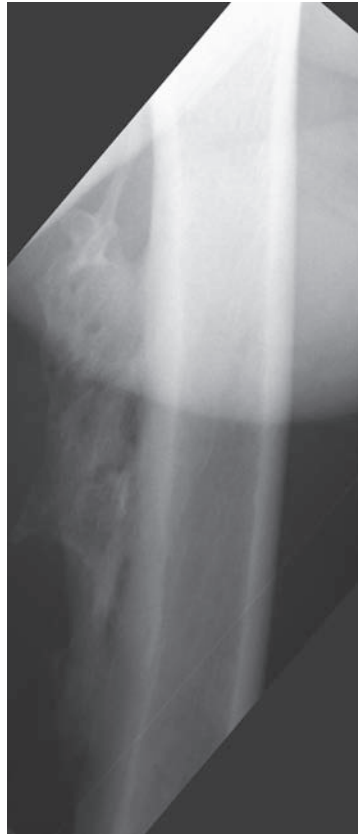
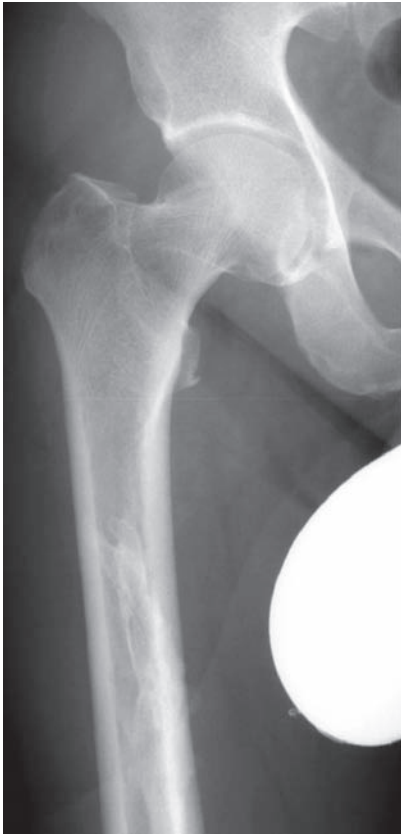- Faint soft-tissue calcification develops in 2–6 weeks, becoming smaller and organised by 5 to 6 months.
- Separate from bone, but periosteal reaction may occur and can be mistaken for osteosarcoma.
- May occur within the muscle for example ‘riders bone’ (adductor longus); ‘fencers bone’ (brachialis); ‘dancers bone’ (soleus).
- May be periosteal at tendon insertion; Pellegrini–Stieda lesion (medial collateral ligament of knee).
- CT – depends on age of lesion. Well-defined mineralisation at periphery of lesion after 4–6 weeks with diffuse ossification in mature lesion.
- MRI – early lesions may reveal an ill-defined mass with heterogenous signal. Later, soft-tissue and bone-marrow oedema develop with decreased signal intensity surrounding the lesion due to mineralization/ossification.

Management

- Directed towards diagnosis and exclusion of sinister pathology.
- Symptomatic control with NSAIDs.
- Indomethacin is usually first line for myositis and should be started early for best results.
- Avoid painful aggressive rehabilitation/new trauma particularly after paediatric elbow trauma.
- With revision hip replacement through an area of severe heterotopic ossification, consider radiotherapy and NSAIDs.



Pellegrini-Steida lesion.



Post-traumatic calcification at the insertion of the gluteus maximus muscle (frontal and oblique views).

Non-accidental injury

Characteristics

- True incidence unknown but increasingly recognised by health-care staff.
- Classified into physical, sexual, psychological abuse and neglect.
- Prevalent in all ethnic and socio-economic classes.
- No sex preponderance seen in physical abuse.
- Can occur at any age. Infants are more vulnerable to fatal head trauma than older age group.
- Up to one-third of fractures in children may be non-accidental.

Clinical features

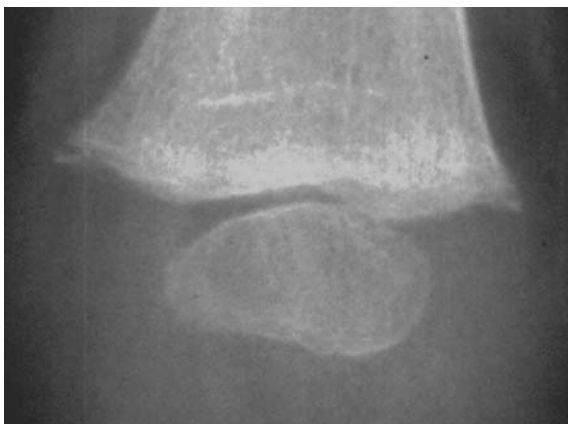- Spectrum of physical injuries from mild soft tissue to fatal trauma seen.
- Usually present with an obvious injury but beware the non-specific presentation. Observe the child's behaviour and parental interaction.
- History suggestive if injuries are not consistent with history; changing or incomplete history; delay in seeking help.
- Beware the infant with head injuries or injuries suggestive of significant abdominal trauma.
- Look for characteristic soft-tissue injuries such as circular burns (cigarette), linear weals, 'finger-print' bruises and immersion-burn injuries.
- Accidental bruising is unusual in the non-ambulant child.

Radiological features

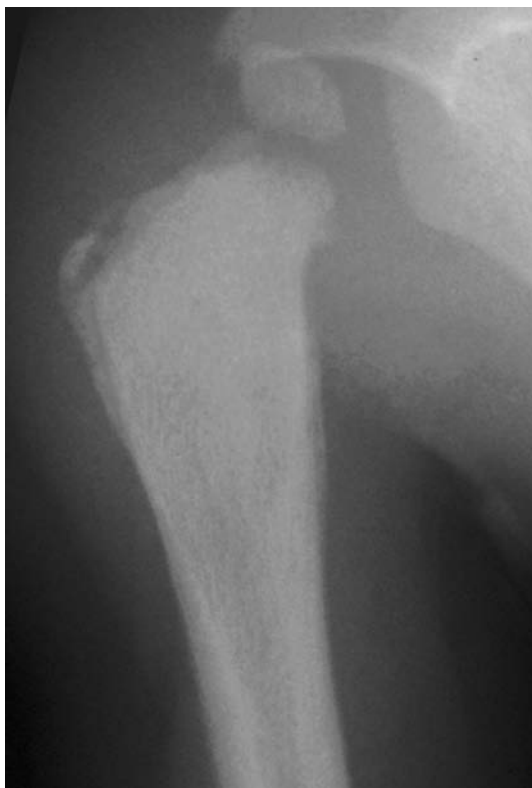- The location and developmental age of the child are better indicators than shape of long-bone fracture.
- Metaphyseal fractures are characteristic but less commonly seen than shaft fractures (low specificity). Other highly specific fractures include scapular, posterior rib, spinal, sternal, multiple fracture of differing ages and complex skull fractures. Epiphyseal separations are suspicious.
- Simple linear skull fractures can result from a minor accidental fall from height.
- CT head may be required. Look for evidence of brain injury, associated haemorrhage or skull fracture.

Management

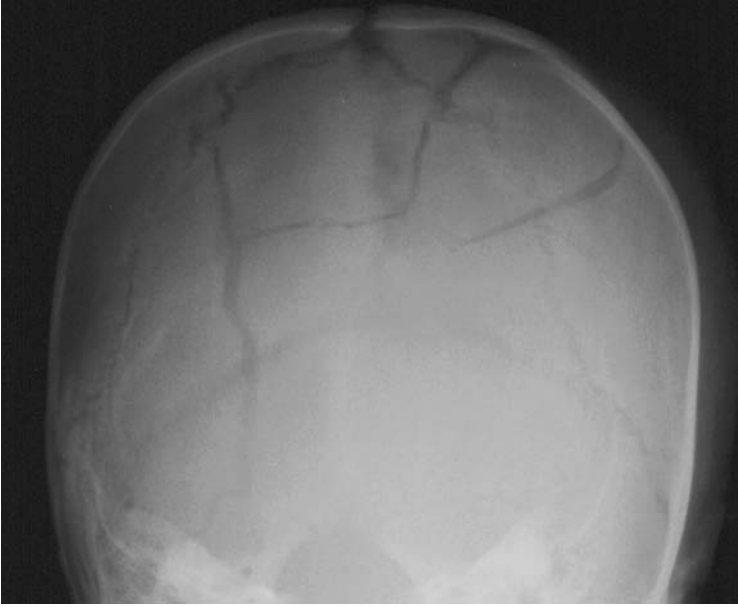
- ABCs.
- Sympathetic and considered approach to child and family.
- Treat as you would for accidental injuries but consider all for admission.
- Careful and accurate documentation. Photograph injuries if possible.
- Involve experienced staff early if suspicious.
- Follow local protocol (e.g. referral to paediatric registrar, check 'At risk' register, appropriate referral to social/community services).



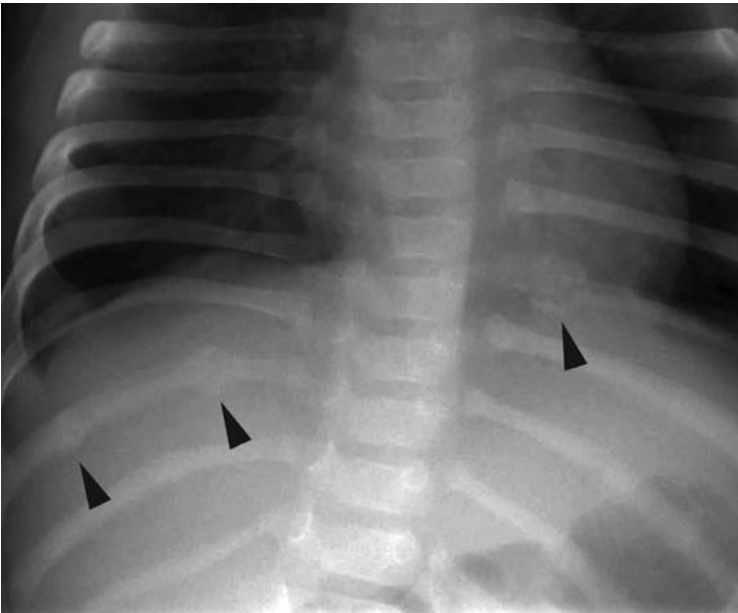
NAI: metaphyseal corner fractures distal femur.



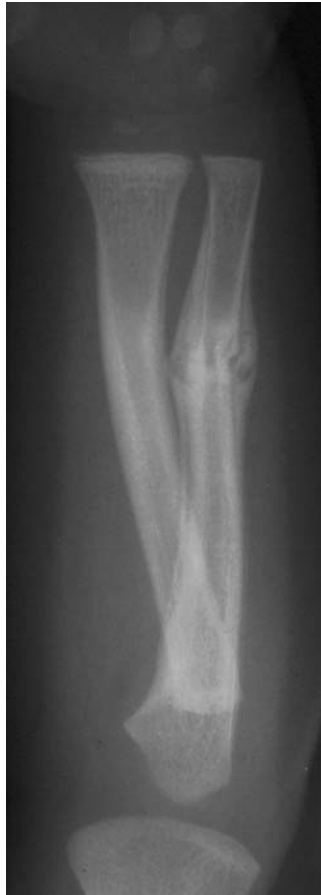NAI: metaphyseal fracture proximal humerus with periosteal elevation secondary to subperiosteal haematoma.



NAI: complex skull fracture.



NAI: multiple posterior rib fractures (arrowheads). Differing degrees of callus formation are seen, indicating the fractures are of differing ages.



NAI: acute on chronic fracture of the left ulna. Evidence of a recent fracture through healing callus.

Osteoarthrosis – osteoarthritis

Characteristics

- Chronic joint disorder characterised by a progressive loss of articular cartilage and marginal new bone formation.
- Classified as primary in which no cause is found, or secondary. Usually a combination of both primary and secondary factors is involved.
- Generally a disease of the elderly but seen in younger patients with articular cartilage damage or where abnormal stresses are involved.
- Characterised by progressive cartilage loss, marginal osteophyte formation, subarticular cysts, bone sclerosis and capsular fibrosis.

Clinical features

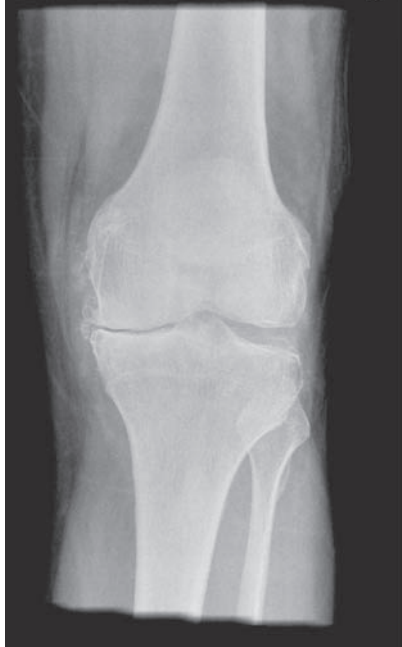- Commoner in weight-bearing joints (hip, knee and spine) than in others (glenohumeral). Interphalangeal involvement is more common in women. Previous injury to the joint can predispose.
- Family history – the known genetic trends may eventually explain OA.
- Pain is common and may be referred from an adjacent joint. Typically, worse in the morning or with immobilisation and aggravated by exertion.
- Stiffness common after inactivity, but may be constant with disease progression.
- Swelling from joint effusion, capsular thickening and/or osteophyte formation.
- Loss of function is generally a late feature. Look for muscle wasting as an indicator.
- ‘Joint failure’ – including muscle, bone and cartilage.

Radiographic features

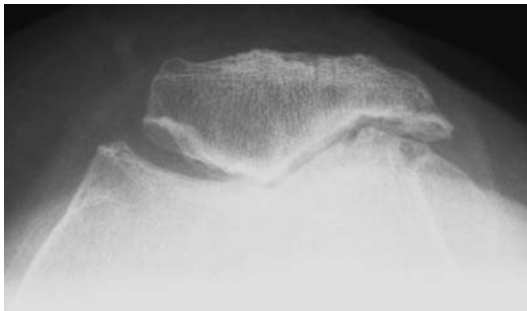
- Good quality multi-view X-rays form the main imaging modality.
- Ensure that films are taken with the appropriate loading, e.g. weight-bearing.
- Look for loss of joint space, subchondral cysts, marginal osteophytes and bony sclerosis. Bone density is generally preserved.
- CT can be useful to assess if cortical bone is involved. May reveal loose bodies not evident on plain radiography.
- MRI is the modality of choice to identify cartilage loss. Effusions and cysts are better demonstrated with MRI.
- Isotope scanning can be useful to assess distribution.

Management

- Early – aim to relieve pain; increase function and reduce load. Lifestyle changes are important. Weight loss; planned exercise and diet (e.g. high dose glucosamine/chondroitin) sometimes helps. Simple measures such as joint-stress avoidance with walking aids are beneficial. Simple



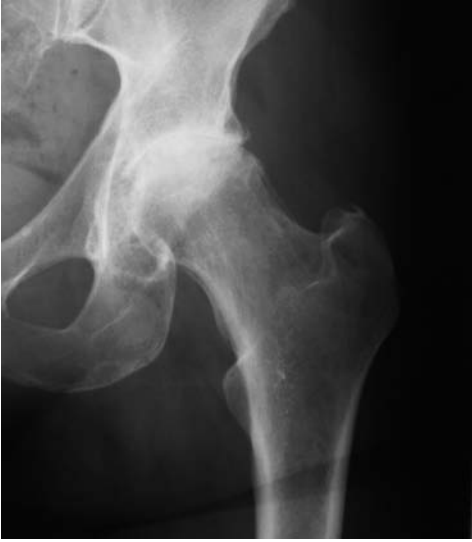OA: advanced degenerative change within the medial tibiofemoral joint compartment. Note the lateral meniscal chondrocalcinosis.



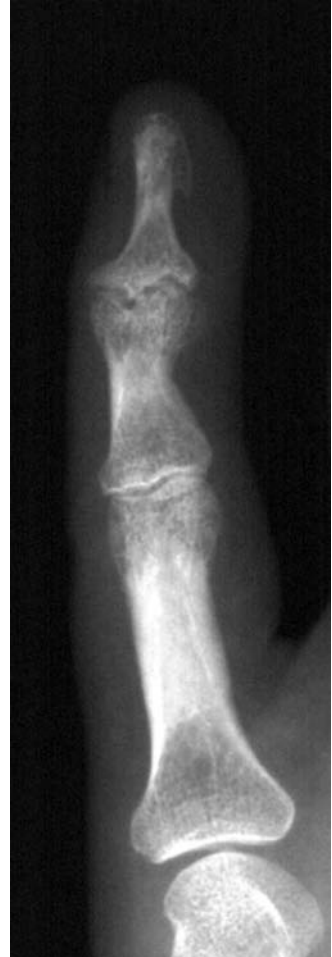OA: Severe patellofemoral OA.

analgesia and NSAIDs are advised. Orthoses can be used to increase function as well as providing support and help prevent deformities.

- Intermediate – realignment osteotomy and arthrodesis have discrete roles.
- Late – arthroplasty is the definitive treatment.



OA: advanced degenerative change seen in the weight-bearing compartment of the left hip joint.



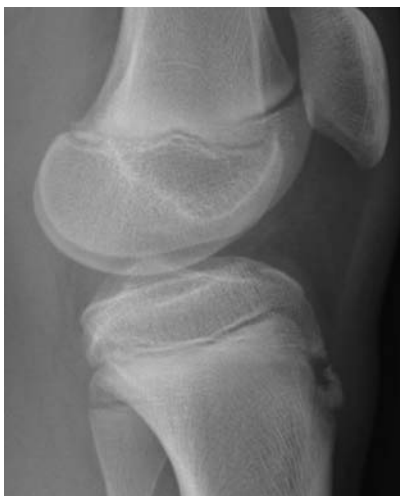OA: erosive OA at the DIPJ little finger.

Characteristics

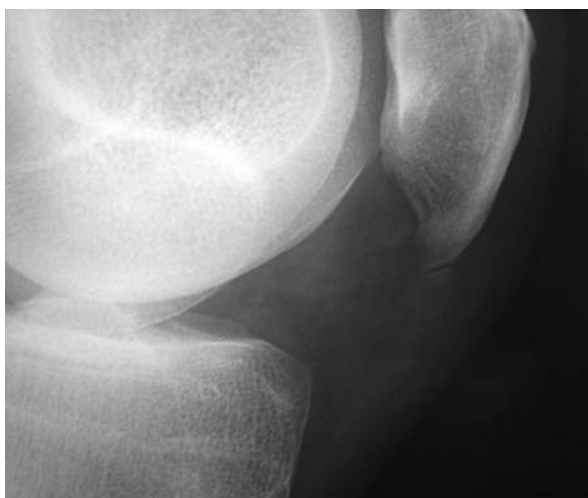- Includes a number of conditions with compression, fragmentation or separation of a small fragment of cartilage and underlying bone.
- Also known as osteochondritis, but pathologically there is no inflammation and hence the term ‘osteochondrosis’.
- Most commonly affects adolescents and young adults.
- The cause is unknown, but theories suggest an underlying patient predisposition, perhaps due to vascular coagulopathy, with a superimposed trauma/overuse syndrome.
- Pathology includes features of osteonecrosis in the bony part of the osteochondral fragment, with surrounding hypervascularity and osteogenesis in the ‘donor site’ of the osteochondral fragment.
- Subdivided by relating the presumed mechanism of final vascular insult:
 - Crushing – capillary compression in the subarticular bone secondary to bleeding/oedema post trauma.
 - Splitting (‘osteochondritis dissecans’) – trauma produces direct separation of osteochondral fragment blood supply.
 - Pulling (‘traction apophysitis’) – repetitive traction may similarly damage osteochondral vascularity, but not a true osteonecrosis.

Clinical features

- Crushing:
 - Late adolescents and young adults with poorly localised pain and limited movement.
 - Disproportionate growth may play a role, e.g. a long metatarsal produces excessive compression within its epiphysis.
 - Spontaneous osteonecrosis of epiphyseal ossific nucleus in a number of sites with well-known eponyms.
 - Freiberg’s (second metatarsal head) and Kienböck’s disease (lunate).
 - Scheuermann’s disease (vertebral osteochondrosis) is similar, but osteonecrosis is absent.
- Splitting:
 - Young adults – M > F.
 - Separation of articular osteochondral fragment.
 - Knee (medial femoral condyle most common), talus and hip are most common.
 - Pain, swelling, effusion ± locking (loose body).
- Pulling:
 - Adolescents classically with knee or heel pain and tenderness.
 - Osgood–Schlatter’s (tibial tuberosity), Sindig–Johanssen–Larsen (distal pole patella) and Sever’s diseases (os calcis apophysis) are the classic examples.



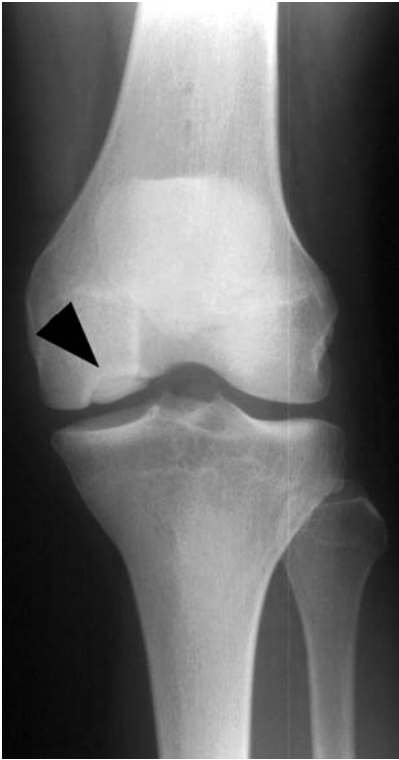Osgood–Schlatter disease: traction apophysitis of the tibial tuberosity with overlying soft-tissue swelling.



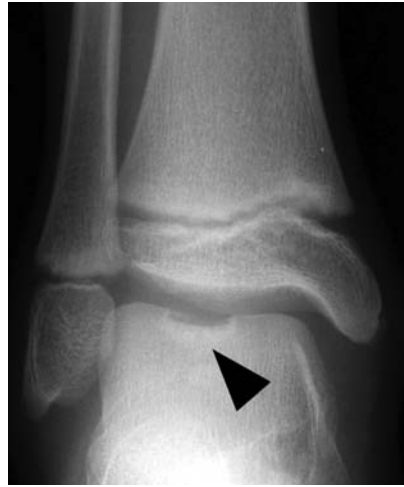Sindig–Johanssen–Larsen disease: traction apophysitis of the lower pole of patella.

Radiographic features

- Crushing:
 - Increased opacity, with surrounding lucency and then underlying sclerosis.
 - Later fragmentation and collapse.
- Splitting:
 - May not be seen on X-ray as the damaged joint surface needs to be tangential to the X-ray beam.



Osteochondritis dissecans: a large osteochondral fragment remains *in situ* in the medial femoral condyle.



Osteochondritis dissecans: a large osteochondral defect is seen within the talar dome.

- Radiolucency with adjacent sclerosis on X-ray.
- The defect (and sometimes loose body) is also visible after osteochondral separation on X-ray.
- MRI is more sensitive in the early stages with marked high signal.
- Pulling:
 - Increased radiopacity at an apophysis.

Management

- Crushing:
 - Analgesia and rest for the majority of cases.
- Splitting:
 - Reattachment of the bony fragment if the articular cartilage is still intact – often arthroscopically in the knee.
 - Removal of loose bodies and drilling of crater defects. Possible role for autogenous chondrocyte implantation (ACI or MACI[®]).
- Pulling:
 - Rest and analgesia – occasionally splintage is required.
 - If painful ossicles develop after the apophysis has fused, excision is very often successful.

Osteomyelitis (acute)

Characteristics

- Majority of primary osteomyelitis occurs in children. Usually occurs in adults secondary to debilitation or immune compromise (diabetes, drugs, disease).
- Organism seeding is usually haematogenous or direct implantation from trauma (accidental or iatrogenic).
- Causal organisms include *Staphylococcus aureus*, Group B *Streptococcus* and enteric species. In drug addicts *Pseudomonas* is common. *Salmonella* infection is associated with sickle-cell disease.
- The metaphysis is the commonest site in children (e.g. proximal femur). In adults the spine is commonly affected. The lower extremities of diabetic patients are particularly at risk.
- Pathological sequence usually follows inflammation, suppuration, necrosis, new bone formation ending with resolution.

Clinical features

- Characteristically the patient is feverish and complains of severe pain associated with malaise. Local erythema, oedema and warmth tend to be later signs. In adults beware new-onset back pain associated with systemic upset.
- Lymphadenopathy is usually present but non-specific.
- Infants may simply present with failure to thrive with only a mild constitutional upset.
- In the elderly and immuno-deficient patient, systemic features can again be mild. Take a full history – even an uncomplicated catheter change may be causative.

Radiological features

- Initial plain films are often normal.
- In the early stages look for distortion of fat planes signifying soft tissue swelling or adjacent fluid accumulation. Lucency may be visible after 5–7 days.
- After approximately 10–14 days, bony necrosis and periosteal reaction become evident.
- MRI – more sensitive in the early stages. Bone marrow is hypointense on T1WI + hyperintense on T2WI.
- Nuclear medicine – high sensitivity with gallium or diphosphonate bone scans.

Management

- Traditional management involves general supportive therapy for pain and dehydration.

- Exclude septic arthritis in children with a reactive effusion.
- Antibiotics targeted to the likely causative organism after sampling.
- Splintage may be of benefit to reduce pain and prevent joint contractures.
- Surgery can usually be avoided. Large collections require drainage.

Fig 1

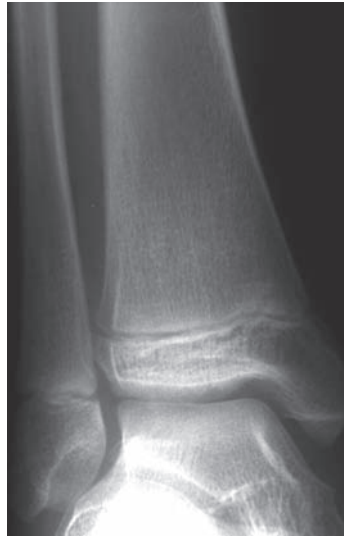

Fig 2

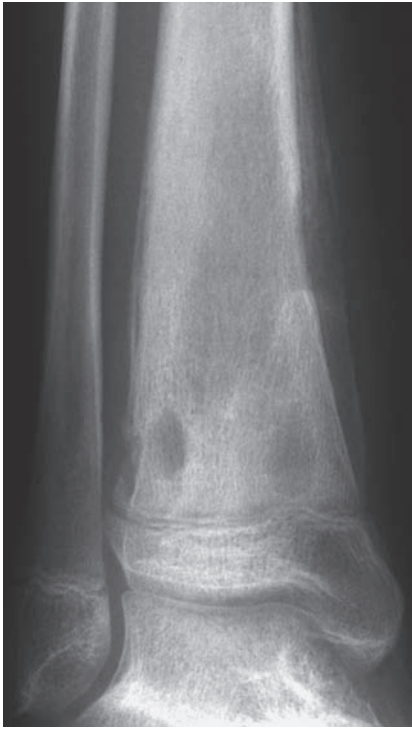
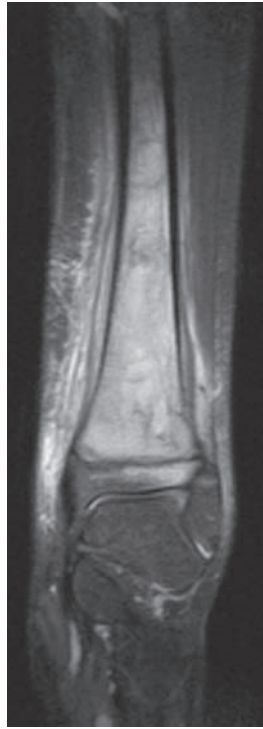
Fig 3



Acute osteomyelitis: initial radiograph (Fig. 1) appears normal. However, after approximately 6 weeks (Fig. 2), abnormal trabeculation and lysis are seen within the distal tibial metaphysis, with associated periosteal reaction. Coronal STIR MRI (Fig. 3) demonstrates extensive signal abnormality within the medullary cavity, extending across the epiphysis in to the physis. Periosteal elevation, due to subperiosteal fluid collections, and subcutaneous oedema are evident.

Characteristics

- *A systemic skeletal disease* characterised by low bone mass and micro-architectural deterioration of bone tissue (*Am. J. Med.*, **94** 646–650 1993).
- *Increased bone fragility* and susceptibility to fracture (*Am. J. Med.*, **94** 646–650 1993).
- *Pathology* – increased resorption compared to formation of bone.
- Post-menopausal women most affected.
- *Prevalence increases with age* – but senile osteoporosis differs from post-menopausal osteoporosis, although this is not fully understood.
- *Racial differences* likely to relate to higher starting bone density.
- *Family history* may be positive.

Clinical features

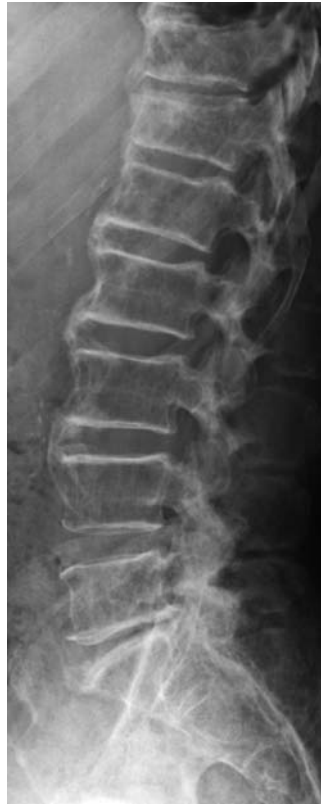- Usually diagnosed secondary to a fracture.
- Co-morbid medical conditions increase the likelihood of a fracture secondary to osteoporosis. For example, poor balance and falling sideways increases the risk of hip fracture six-fold compared to other directions.
- Exclude eating disorders in the young patient.
- Look for primary and secondary amenorrhoea, adequate calcium uptake and drug treatments, e.g. steroids.
- Common fracture sites are the femoral neck, vertebrae and distal radius.
- Vertebral fractures are often asymptomatic and discovered incidentally.
- Kyphosis and loss of height can occur following vertebral crush fractures.
- See Trauma section for clinical features.

Radiological features

- Bone density is difficult to interpret on plain radiographs, hence the use of the term osteopaenia to describe the relative bony lucency.
- See Trauma section for individual fractures.
- DEXA (dual energy X-ray absorptiometry) is the current investigation of choice for the diagnosis of osteoporosis – measured as the standard deviation from the ‘normal’ range.

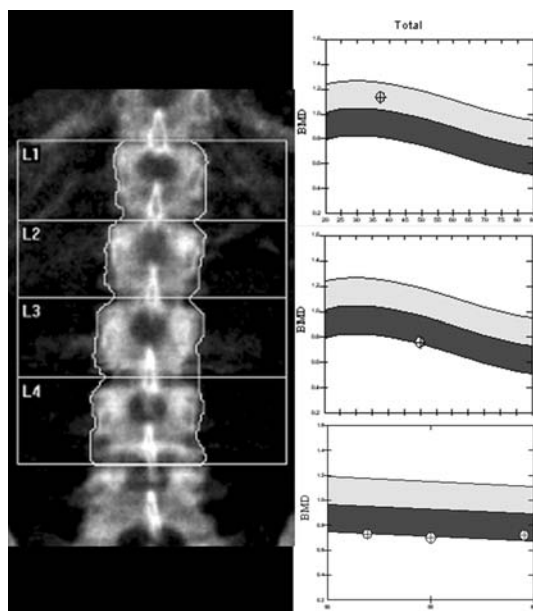
Management

- Aimed at prevention, preventing progression and treating complications.
- Prevention should begin early in life with education regarding good nutrition, weight-bearing exercise and limiting alcohol intake.
- Fall prevention is useful in the elderly.
- Group resistance exercise classes in athletic amenorrhoea are useful.
- Supplementary calcium and vitamin D.

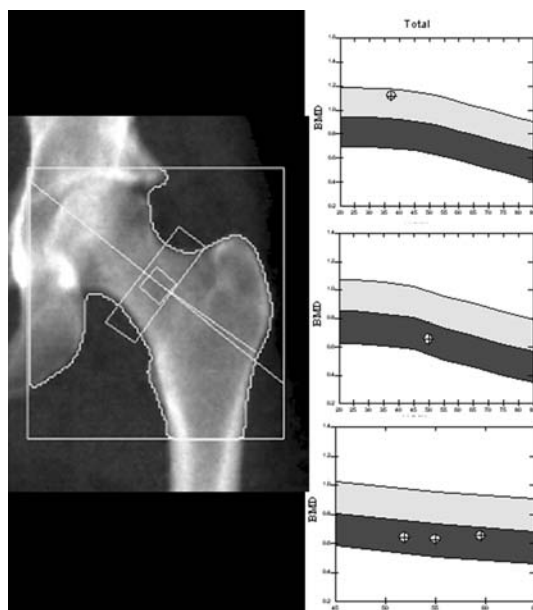


Generalised bony osteopaenia: assessment of bone density is difficult on plain radiographs, hence the use of the term osteopaenia, rather than osteoporosis, when reviewing X-rays. Quantitative measurement performed with DEXA scanning.

- Hormone replacement therapy is helpful at maintaining bone density although should not be first-line treatment because of associated risks.
- Bisphosphonates (inhibit osteoclastic activity) prevent further bone loss to reduce fracture risk.
- Teraparotide is anabolic for bone and increases bone density.



Osteoporosis: DEXA scan of the lumbar vertebral bodies, demonstrating (from top to bottom graphs, respectively) normal bone density, 'at-risk' osteoporotic patients, and the response to treatment.



Osteoporosis: DEXA scan of the left femoral neck, demonstrating (from top to bottom graphs, respectively) normal bone density, 'at-risk' osteoporotic patients, and the response to treatment.

Paget's disease

Characteristics

- Sir James Paget described the disease in 1877 as a chronic inflammatory remodelling disease of bones. He labelled the condition osteitis deformans.
- Characterised by bony thickening and enlargement secondary to increased bone turnover.
- The bone is weak and brittle due to abnormal bone structure.
- Unknown aetiology (possible link with paramyxovirus) occurring in approximately 3% of the population over 40.
- Environmental and family clustering is seen – 7% males in Lancashire (north-west UK).

Clinical features

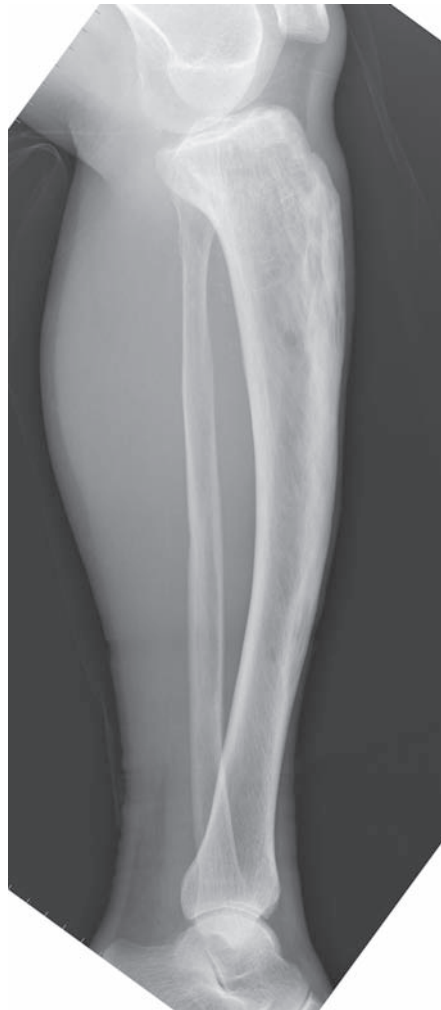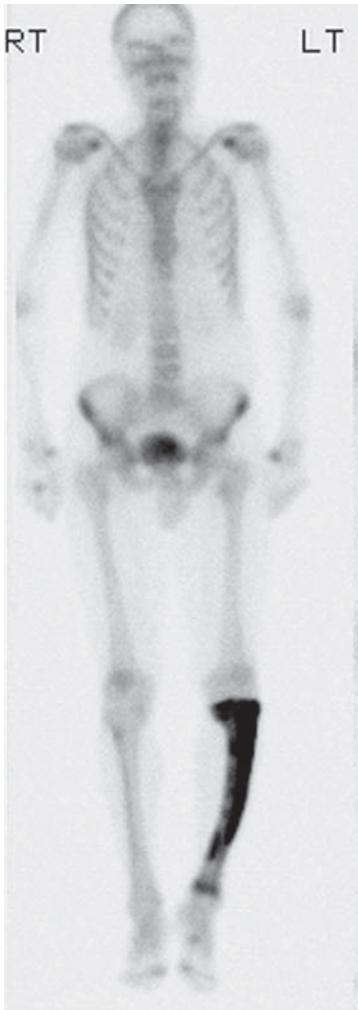
- Pain is the commonest symptom, but most patients asymptomatic.
- Monostotic or polyostotic.
- Sarcomatous change within the abnormal bone is the most sinister complication – said to be 1%.
- Other complications include pathological fractures, bony impingement on nerves and secondary arthritis.
- Deafness may occur secondary to nerve impingement or involvement of the ossicles.
- Frequently affected bones include the pelvis, lumbar and thoracic vertebrae, proximal femur, calvarium and tibia.
- High-output heart failure is a rare complication.

Radiological features

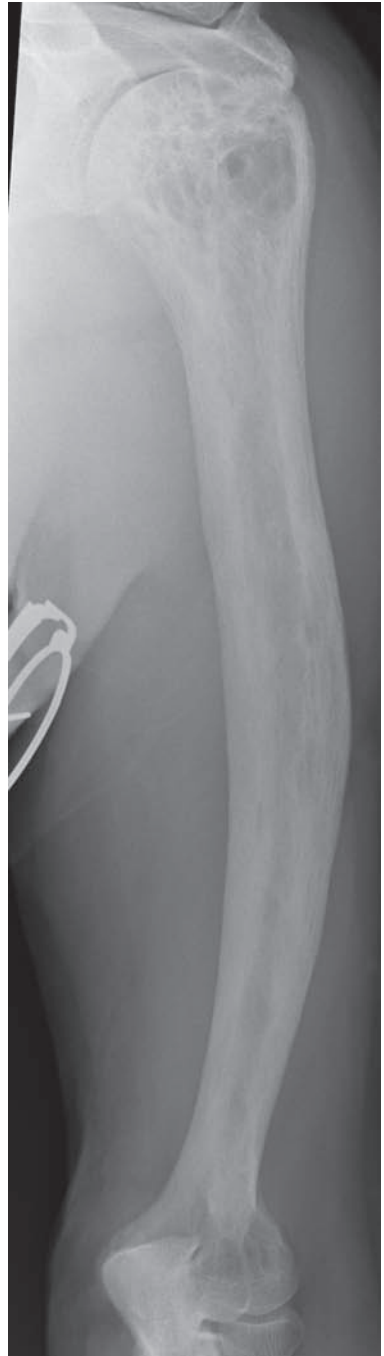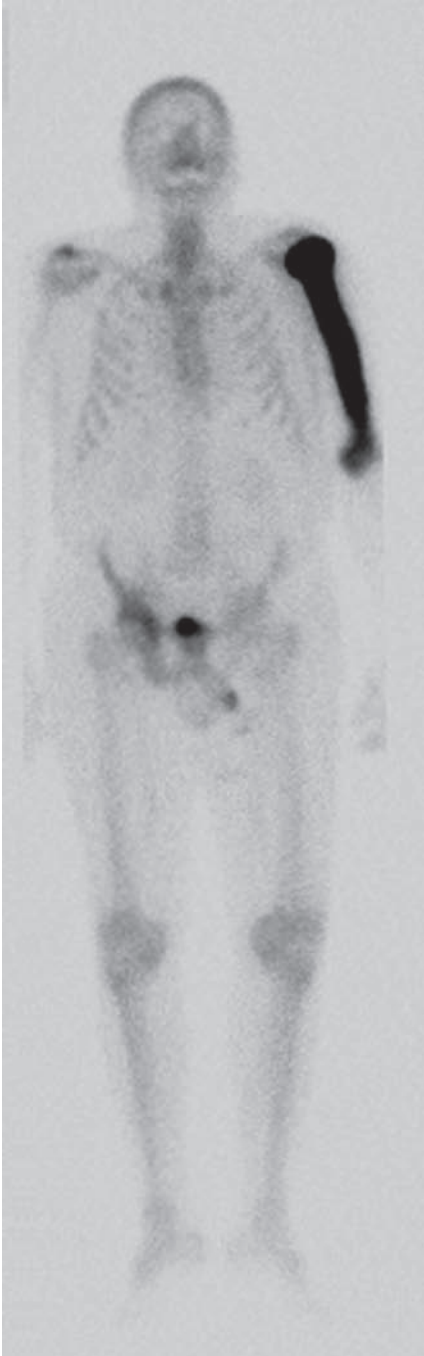
- Thickened coarse trabeculae with cortical enlargement.
- Cyst-like areas during the lytic phase.
- Skull – both tables are involved with diplopic widening. Well-defined lytic areas more common anteriorly. The bony texture resembles 'cotton wool'.
- Pelvis – ilio-pectineal line thickening. Trabecular coarsening.
- Long bones – curved femur and tibia.
- Spine – 'ivory vertebrae' (sclerotic in appearance) or 'picture frame' appearance seen secondary to peripheral trabecular thickening and a relatively radiolucent central portion of the vertebral body.
- Bone scan – marked increased uptake in affected bones. May be normal in 'burned out' disease.

Management

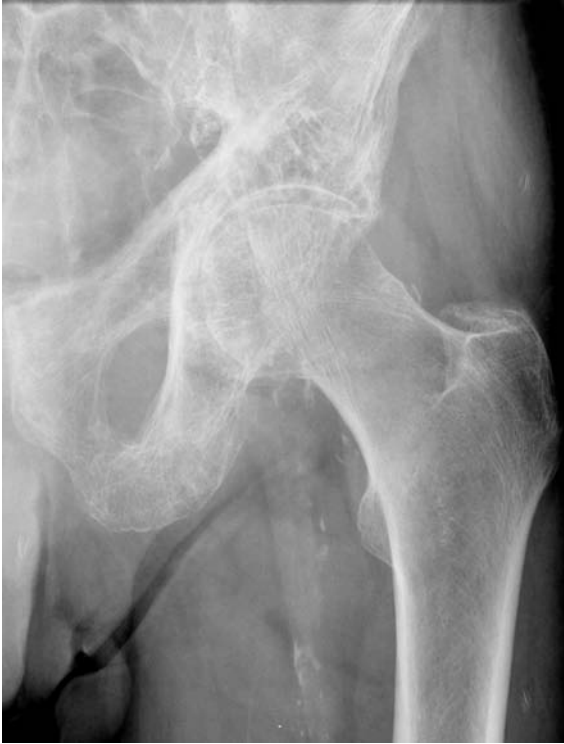- Often directed towards symptomatic relief.
- Drugs such as bisphosphonates (and calcitonin) suppress bone turnover.
- Surgical treatment of complications such as pathological fractures and secondary arthritis. Nerve entrapment may respond to decompression.
- Sarcomatous change generally has a very poor prognosis.



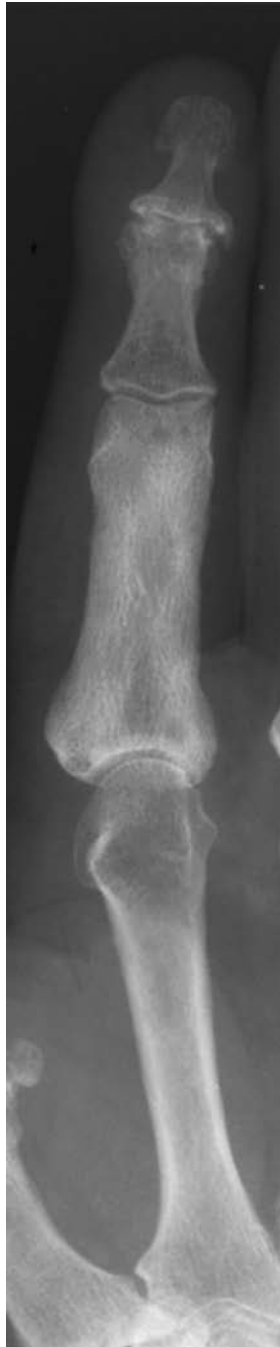Paget's disease of the left tibia: marked diffuse isotope uptake seen on bone scan with the typical radiographic finding of trabecular coarsening and tibial bowing.



Paget's disease of the left humerus: once again, marked isotope uptake is seen on the bone scan with trabecular coarsening and bowing of the humerus.



Paget's disease of the left innominate bone: thickening of the iliopectineal line and coarsening of trabecular pattern.



Paget's disease of the proximal phalanx of the left index finger: there is generalised cortical thickening and sclerosis of the phalanx.

Perthes disease

Characteristics

- A form of avascular necrosis of the femoral head, probably secondary to disruption of the blood supply to the femoral epiphysis.
- Commonest between the years of 4 to 8.
- Male predominance with a ratio of 5 to 1.
- Occurs in 1 in 10 000 and is bilateral in 10%.

Clinical features

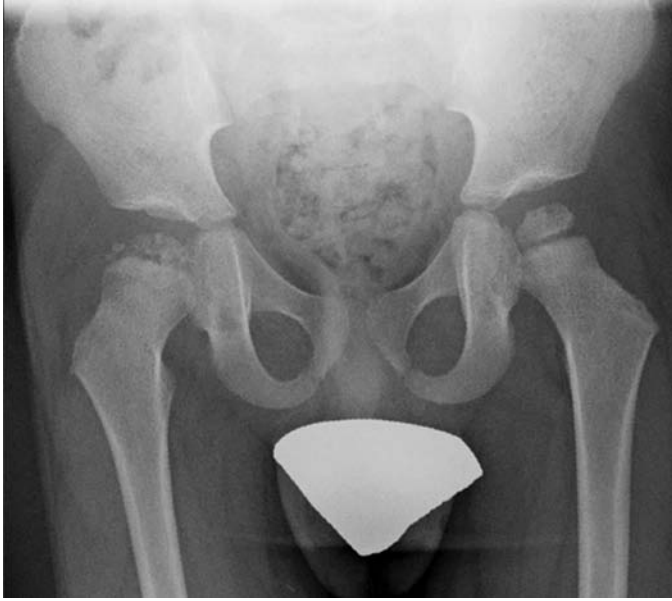- Presents with a limp or, or if bilateral with a painful gait.
- Pain may be referred to the knee or medial thigh.
- On examination, hip abduction and internal rotation are limited.
- Onset may be insidious and thus the child may present late with shortening on the affected side and disuse atrophy of muscle.
- Onset prior to age 8 confers better prognosis.

Radiological features

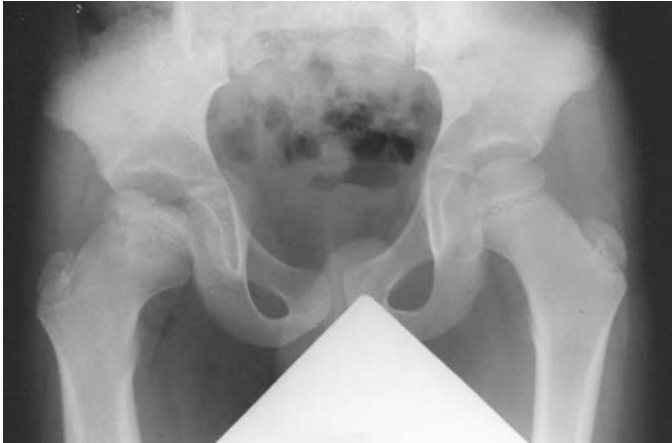- Radiographic features are usually well seen by time of presentation.
- Femoral epiphysis appears smaller on the affected side.
- Femoral head sclerosis with adjacent bone demineralisation.
- Slight widening of the joint space.
- Metaphyseal lucent areas – Gage’s sign.
- Subchondral fracture best seen on the frog lateral view.
- Sclerotic fragmentation of the femoral head.
- Coxa magna – widened flatter femoral head secondary to remodelling.
- CT may show loss of normal trabecular pattern.
- Bone scan will show decreased uptake followed by increased uptake as repair and secondary degenerative change predominate.
- MRI is sensitive, again with varying appearances depending on the stage.

Management

- Initial management involves bed rest and analgesia. In young presentation disease (<8 years) non-operative treatment is most common.
- Maintain the femoral head within the acetabulum.
- Surgical osteotomy may be appropriate in selected cases.
- Herring (*J. Bone Jt Surg. Am.* 2005) has shown surgical management with femoral or pelvic osteotomy is beneficial in late presentation (after age 8) for cases of moderate severity.
- Surgery in late-onset severe disease is controversial.



Avascular necrosis of the right femoral epiphysis.



Late-stage Perthes' disease. Note the right femoral head remodelling with coxa magna.

Pigmented villonodular synovitis (PVNS)

Characteristics

- Rare condition affecting tendon sheaths and joints, most commonly the knee, in young adults.
- Diffuse (most are intra-articular) or nodular (most are synovial sheath) forms exist.
- Pathologically, there is overgrowth of the synovium, in which haemosiderin is deposited, producing the classical brown synovial staining.
- Microscopically, there is an abundance of synovium, which contains lipid-laden histiocytes (foam cells), pigmented histiocytes and multinucleate giant cells.
- Increased numbers of mitoses are common and in the absence of haemosiderin staining and foam-cell histiocytes, consider synovial sarcoma.

Clinical features

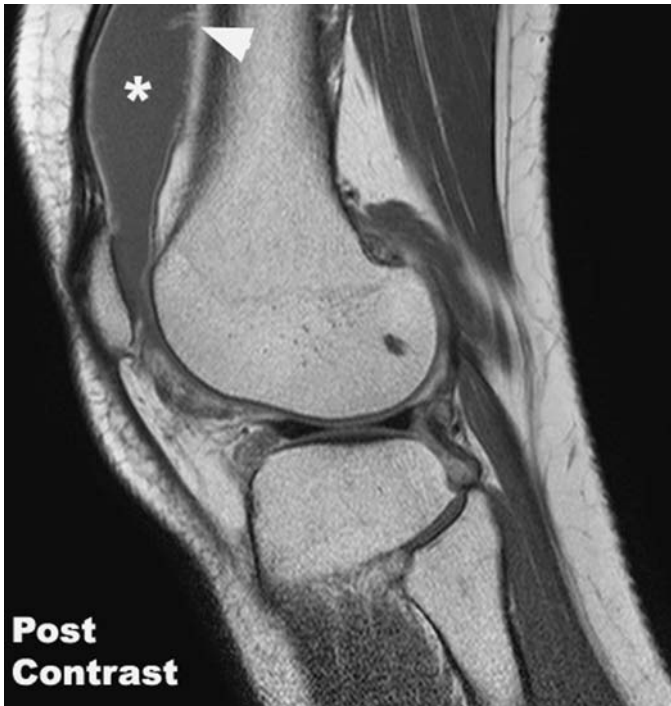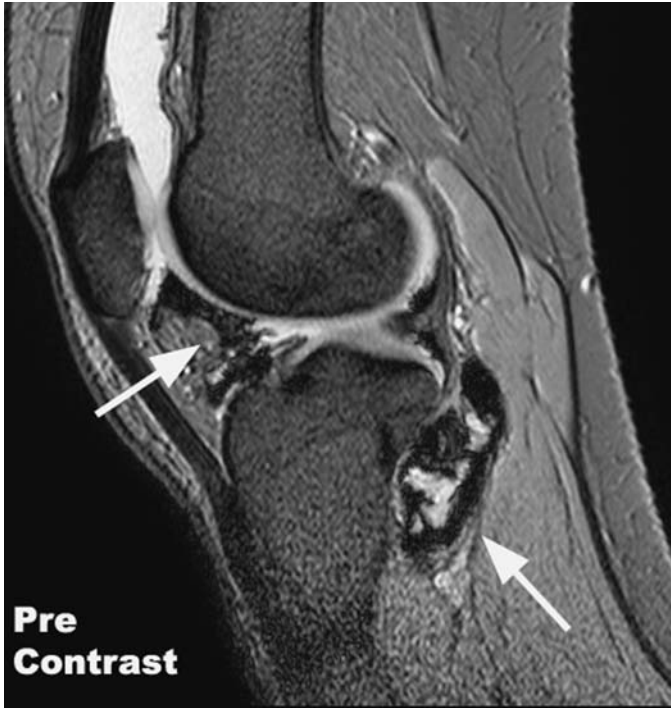- Pain, swelling and synovitis are the most common presentations.
- Joint aspirates are rust-brown.
- Excluding inflammatory arthropathy and tumour is essential.

Radiological features

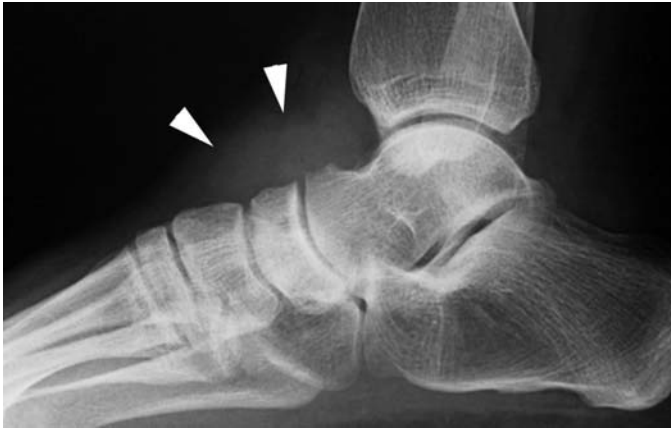- X-rays initially normal but look for periarticular soft-tissue swelling (effusion + synovial proliferation).
- Dense soft tissues (haemosiderin deposition).
- Multiple sites of deossification appearing as cysts.
- Later, well demarcated juxta-cortical erosions, with sclerotic margins, are common.
- No calcification, osteoporosis or joint-space narrowing until late.
- MRI demonstrates the extent of the synovitis well:
 - Synovial soft-tissue masses within a joint effusion.
 - Predominantly low signal intensity on all sequences (due to presence of iron) is characteristic.
 - Cannot distinguish PVNS from malignant synovial sarcoma.

Management

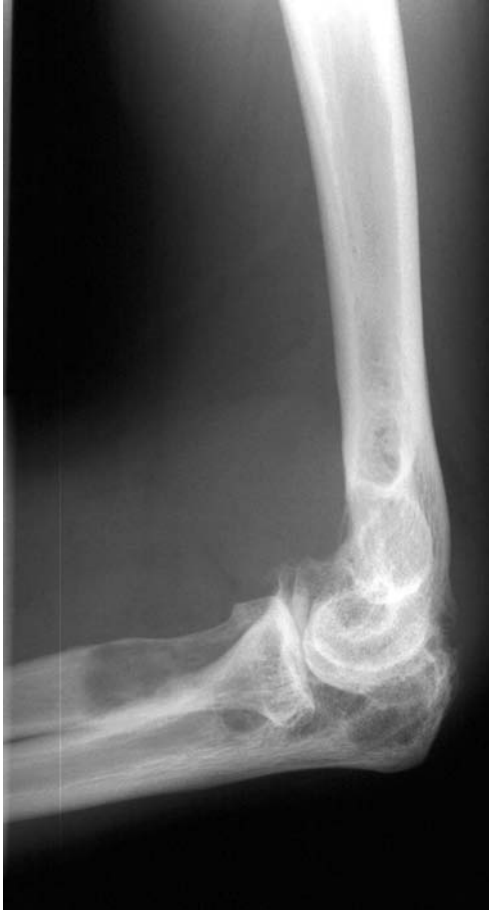- Synovial biopsy to fully exclude a synovial sarcoma.
- Synovectomy is the treatment of choice for symptomatic relief.
- Arthroscopic or open synovectomy depending on the joint involved.
- Complete synovectomy for diffuse disease or more local excision in nodular tendon-sheath disease.
- Possible role for radiotherapy or intra-articular radioisotopes in residual or recurrent disease.



PVNS: Sagittal GE T2 and T1 post-contrast MRI. Large joint effusion (*) with characteristic peripheral 'black' haemosiderin deposits (arrows). Note the prominent synovial enhancement (arrowheads) post-contrast.



PVNS: 'dense' soft-tissue swelling (arrowheads) over the dorsal aspect of the tarsal bones.



PVNS elbow: periarticular soft-tissue swelling, with large, well-defined areas of de-ossification (proximal radius and olecranon process), simulating the appearance of bone cysts.

Psoriatic arthropathy

Characteristics

- Affects 5%–10% patients with psoriasis.
- This is a proliferative synovitis.
- Early fibrosis is common.
- Classified as a seronegative spondyloarthropathy.
- HLA B27 is positive in the majority of patients.
- May mimic rheumatoid arthritis.

Clinical features

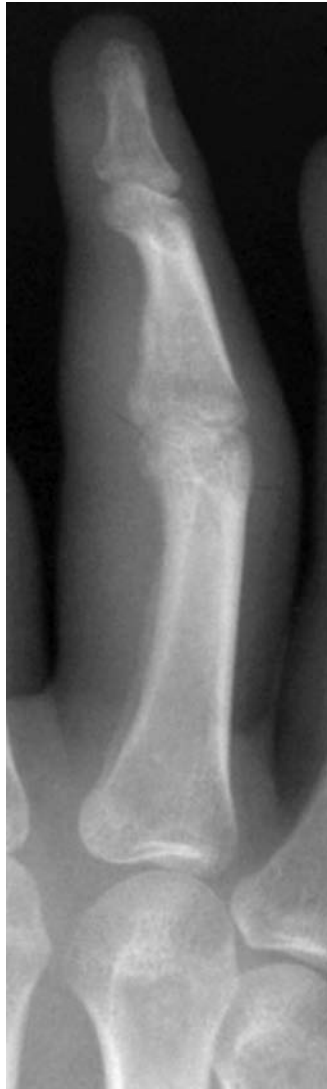- Skin rash commonly precedes arthritis.
- Nail changes include pitting, hyperkeratosis, ridging and subungual separation.
- Joint changes are similar to rheumatoid arthritis although rheumatoid nodules are absent.
- Characteristically a mild asymmetrical polyarthritis typically affecting the distal interphalangeal joints of the hands and feet.
- Bone destruction may be severe (arthritis mutilans).
- Sacroiliitis may mimic ankylosing spondylitis.

Radiological Features

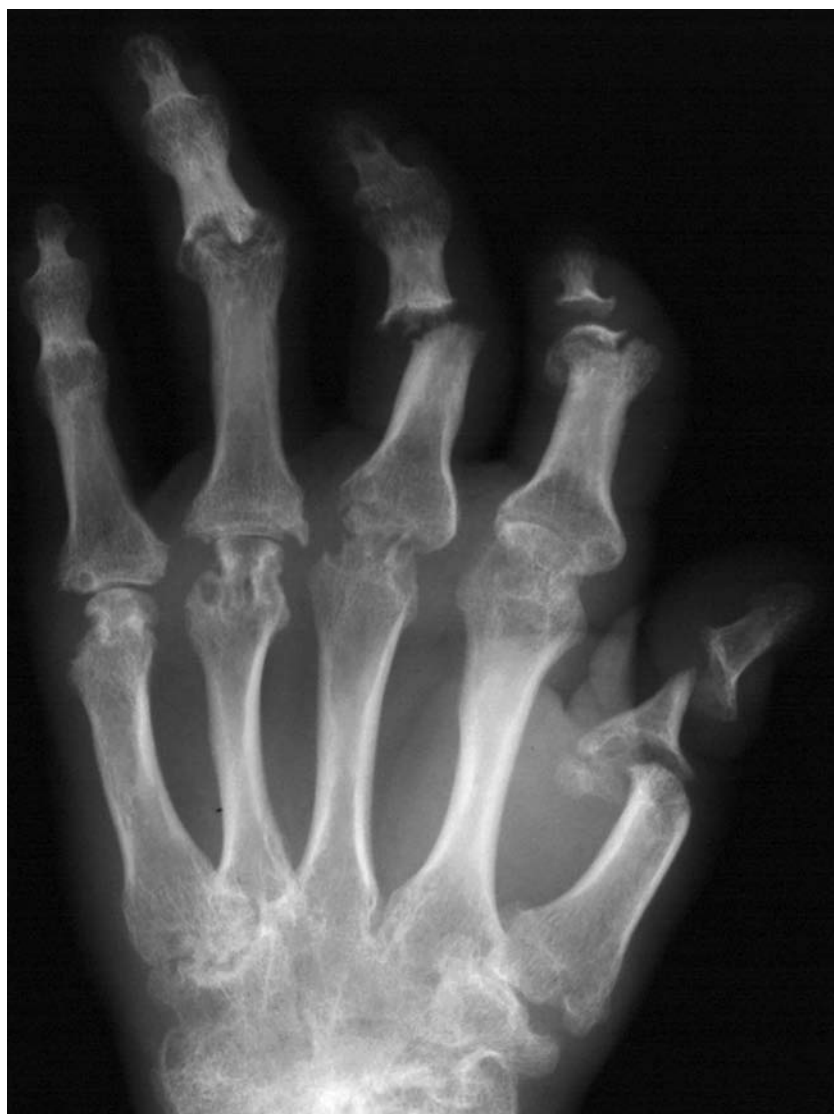- Within the large joints, changes are similar to rheumatoid arthritis.
- Bone density tends to be preserved.
- Psoriatic dactylitis = soft-tissue swelling of entire digit – ‘sausage digit’.
- Interphalangeal joint destruction secondary to erosions and periosteal new bone formation results in ‘pencil in cup’ deformity.
- Sacroiliac erosions are common.

Management

- Specialised care under the guidance of a rheumatologist.
- Treatment aimed at symptom control. NSAIDS are the mainstay of treatment.
- Immunosuppressant drugs (e.g. methotrexate) for resistant disease – current research therapies include anti-tumour necrosis factor.
- Physiotherapy and the use of splintage can help prevent deformity and functional loss.
- Most psoriatic arthropathy is burnt out in 10 years.
- Surgery for pain, instability and to improve function (arthrodesis/arthroplasty).



Psoriatic dactylitis: soft-tissue swelling of entire digit giving the appearance of a 'sausage digit'.



Psoriatic arthropathy: arthritis mutilans. Deforming polyarthropathy with severe bony erosions and 'pencil in cup' deformity at several interphalangeal joints.

Renal osteodystrophy (including osteomalacia)

Characteristics

- Renal osteodystrophy is a global term used to describe bone and joint changes secondary to chronic renal failure.
- Osteomalacia is characterised by incomplete mineralisation of the normal bone tissue.
- Abnormal phosphate retention in renal osteodystrophy leads to hypocalcaemia with resulting secondary hyperparathyroidism.
- Combined features of osteomalacia and secondary hyperparathyroidism are seen.

Clinical features

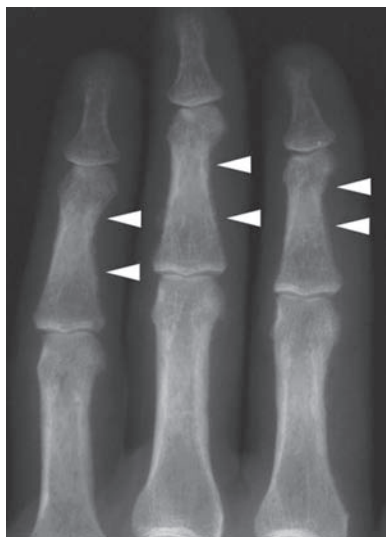
- Osteomalacia tends to present with non-specific bone pain and muscle weakness. Fractures are common especially in the more severely affected patients. Typical sites include femoral neck, pubic rami and vertebral bodies.
- Renal osteodystrophy can also present with rather non-specific features. Weakness and bone pain are common. Fractures are the most frequent complication.

Radiological features

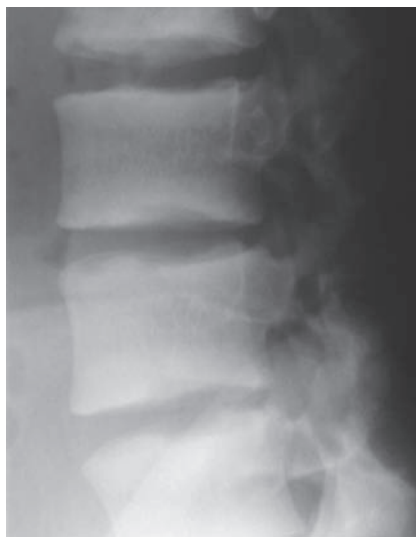- *Osteomalacia* – osteopenia may be the only sign. Coarsened trabeculae with a decrease in number and size. Bone deformity from softening. Pseudofractures = Looser zones (lucent lines at right angles to bone margin, especially in the scapula and femoral neck) and overt fractures may be evident.
- *Renal osteodystrophy* is characterised by bony resorption, soft tissue calcification and osteopenia. Osteosclerosis of the vertebral endplates leads to the classical ‘rugger-jersey spine’. Pathological fractures can also occur through brown tumours and amyloid deposits. Sub-periosteal bone resorption should be sought in the distal phalangeal tufts and along the radial borders of the middle phalanges. Skull radiology may show a ‘salt and pepper’ appearance secondary to trabecular resorption.
- *Bone scans* are useful in showing ‘hot spots’ secondary to subtle fractures. Diffuse uptake (‘superscan’) is seen with renal osteodystrophy and can be confused with widespread metastatic disease.

Management

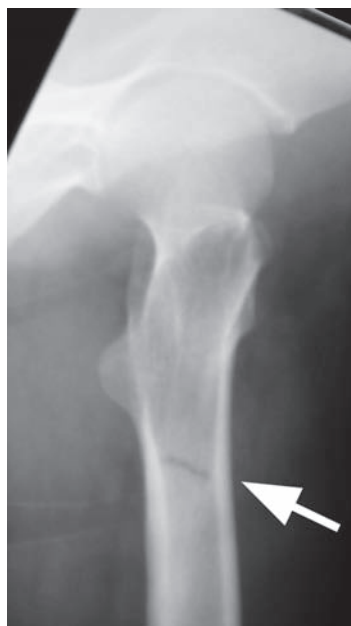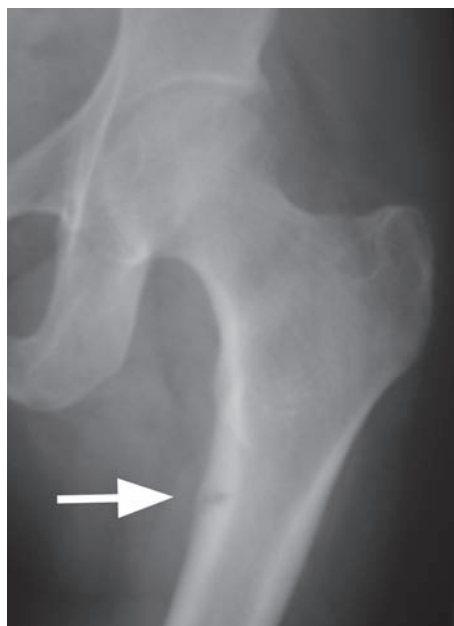
- Treatment is often directed towards the underlying cause of the disease.
- Medical management involves calcium and phosphate control.
- Orthopaedic intervention is generally reserved for the treatment of complications, such as fracture.



Renal osteodystrophy: subperiosteal bone resorption affecting the radial aspects of the middle phalanges of the index, middle and ring fingers (arrowheads). This is due to secondary hyperparathyroidism.



Renal osteodystrophy: classic 'rugger-jersey spine' due to osteosclerosis of the vertebral endplates.



Osteomalacia (frontal and lateral views of the right hip). Pseudofracture ('Looser zone') of the proximal femoral metaphysis.

Rheumatoid arthritis

Characteristics

- Chronic inflammatory disease affecting synovium and articular surface.
- Prevalent in 1% of the population.
- Female predominance in young.
- Similar M : F predominance in later life.
- Synovium becomes inflamed and proliferates, with subsequent degeneration.
- Articular erosion and destruction results in joint deformity and disability.
- Diagnostic criteria should include four of the following:
 - morning stiffness >1 hour.
 - swelling of >3 joints.
 - radiographic evidence of RA.
 - symmetric joint involvement.
 - rheumatoid nodules.
 - positive rheumatoid factor.

Clinical features

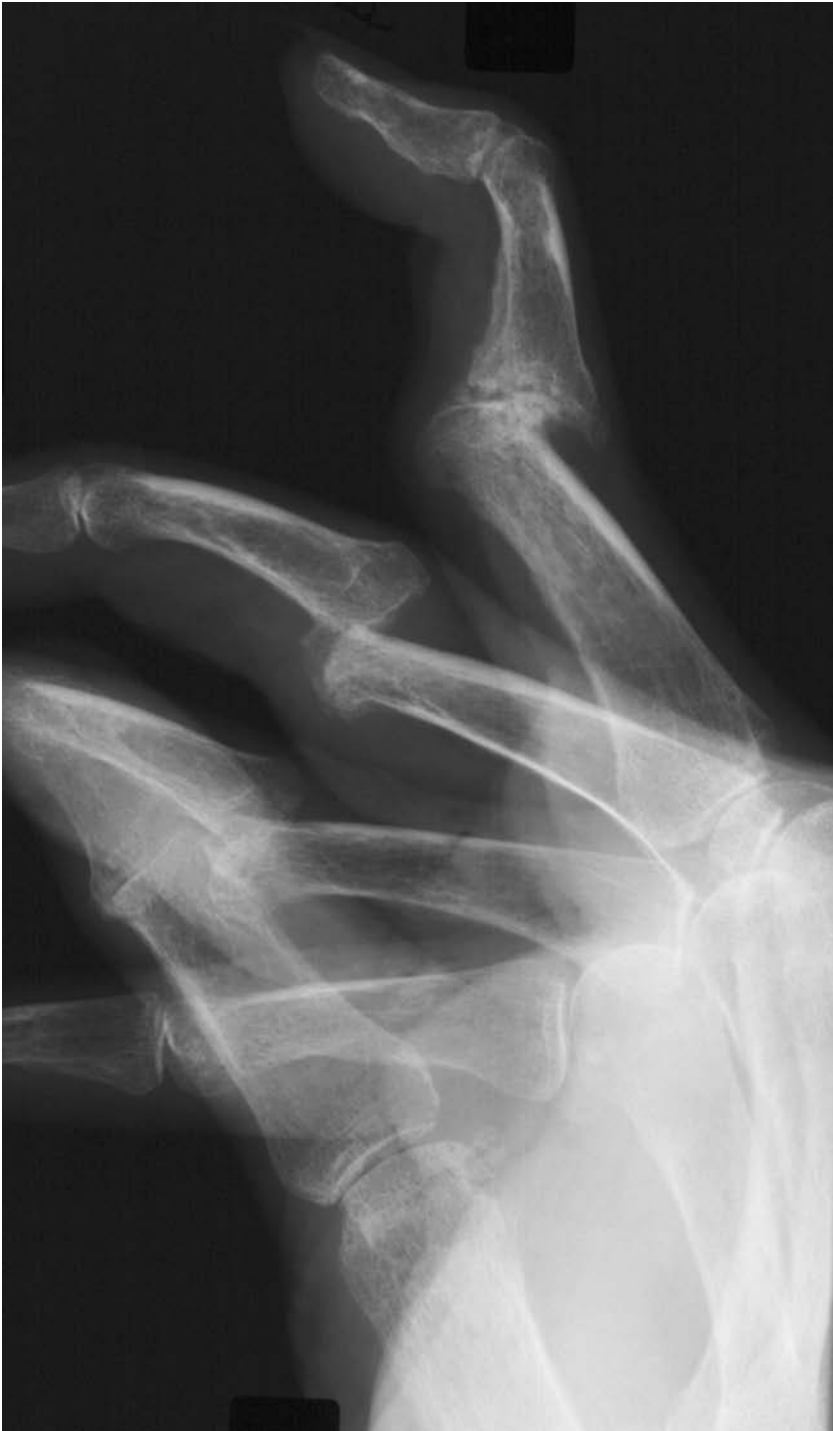- See diagnostic criteria.
- Systemic symptoms include fever; general malaise; weight loss and weakness.
- Acutely involved joints tend to be hot, swollen and painful, often with effusion. Look for an associated bursitis.
- Late joint destruction and deformity (e.g. swan neck and boutonnière).
- Other organ systems may be affected by inflammatory disease (pericarditis, pulmonary interstitial fibrosis, vasculitis, etc.).

Radiological features

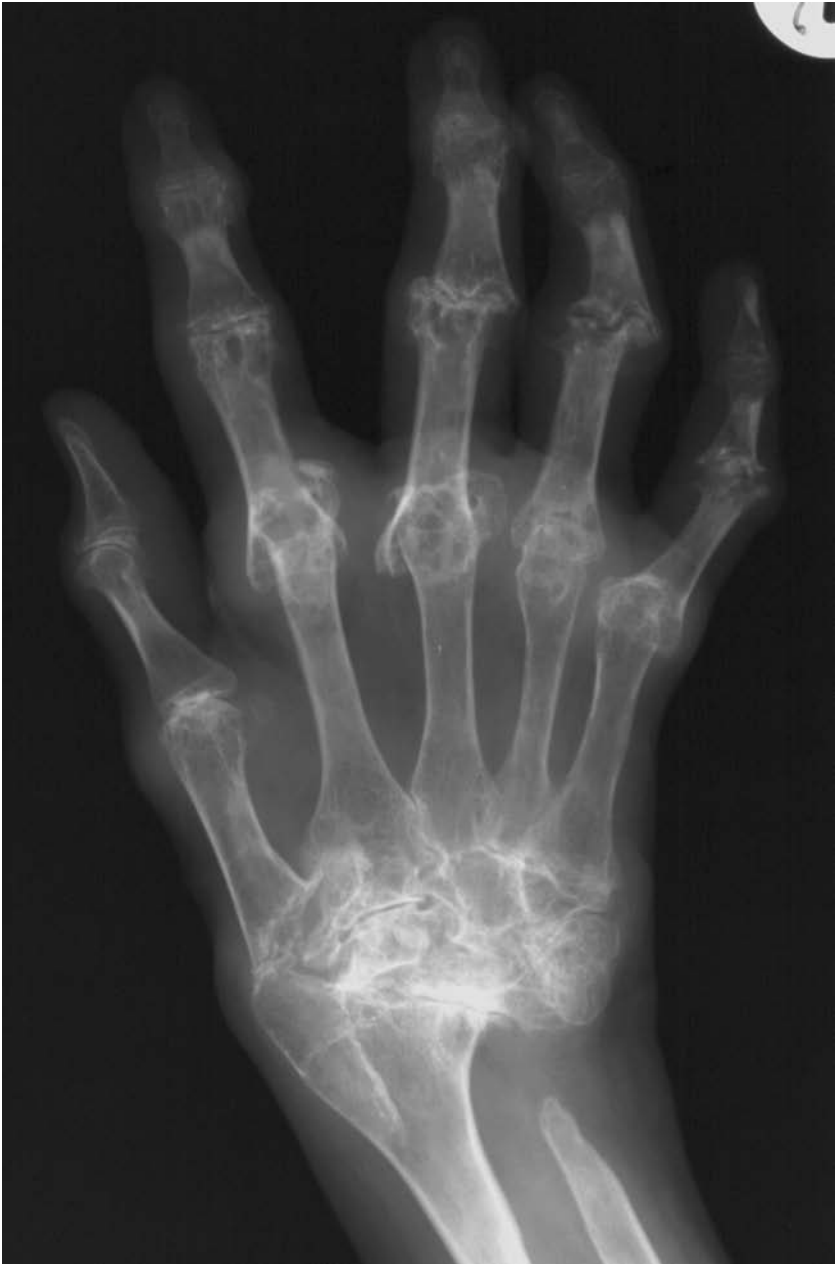- Early signs – fusiform soft-tissue swelling, local osteopenia, marginal and central bone erosions, joint-space widening.
- Late signs – loss of joint space, marked destructive changes, joint subluxation, fragmentation, fractures and ankylosis.

Management

- Specialised care under the guidance of a rheumatologist.
- Simple measures such as weight loss, diet, physical therapy and structured exercise can be effective. Support groups have also been shown to be effective.
- First presentation should be managed with rest and analgesia (NSAIDs). Refer for investigation.
- Disease-modifying drugs for persistent disease – with care.
- Surgical intervention is generally reserved for the associated complications, e.g. degenerate joints requiring arthroplasty.



Rheumatoid arthritis: swan-neck deformity.



Severe rheumatoid hand: deforming polyarthropathy with advanced erosive changes, joint subluxation, disorganised carpus and resorption of the distal ulna.

Characteristics

- Rickets is inadequate mineralisation of osteoid in the immature skeleton.
- Osteomalacia (softened bone) is the same inadequate mineralisation of bone, but occurring in the adult skeleton without the growth disturbances of rickets.
- Rickets occurs secondary to vitamin D deficiency/dysfunction, and with inadequate intake of calcium and phosphorus.
- Associated with sunlight deficiency, renal disease, liver disease and malabsorption, because of the effect on vitamin D synthesis.

Clinical features

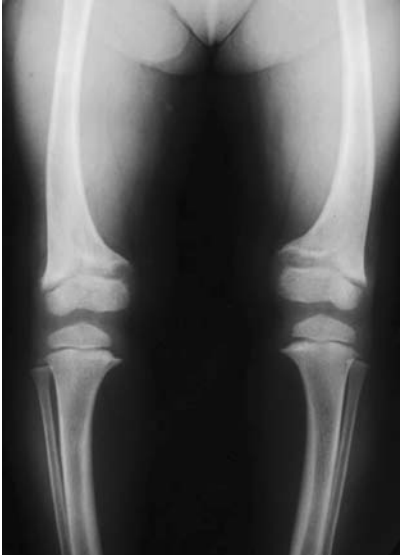- Infants may present with convulsions, tetany or failure to thrive.
- Craniotabes (skull deformity) develops early.
- Muscular hypotonia is common.
- Wrist, ankle and knee swelling.
- 'Rickety rosary' – costochondral junction enlargement.
- Harrison's sulci – lateral chest-wall gutters secondary to muscular action on weakened ribs.
- Leg bowing and knock-knees become more prominent on weight bearing.
- Spinal involvement and long-bone fractures are late manifestations.

Radiological features

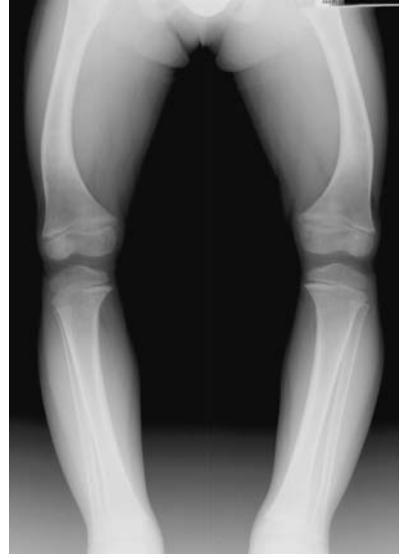- Metaphyses of long bones subjected to stress are particularly involved (wrists, ankles, knees).
- Irregular widened epiphyseal plates – due of the failure of mineralisation.
- Cupping and fraying of metaphyses – best seen where growth is maximal.
- Coarse trabecular pattern.
- Long-bone bowing.
- Periosteal reaction may be present.

Management

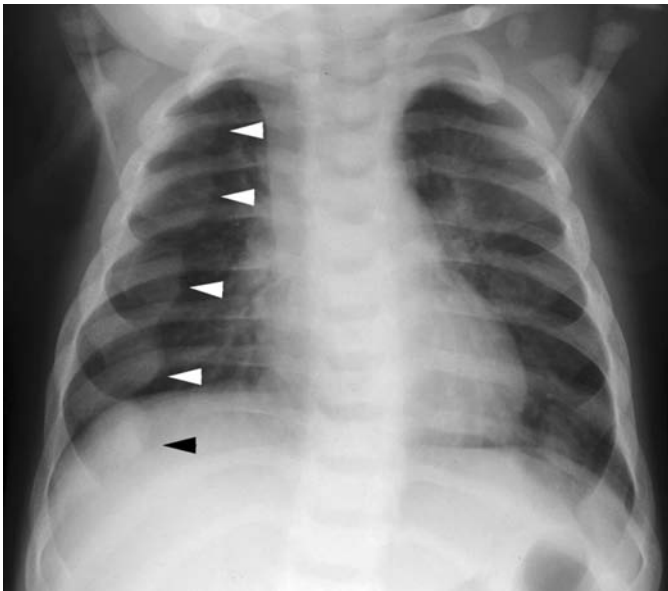
- Identify and treat underlying cause.
- Most deformities will correct with growth once the condition is treated.
- Corrective surgery for severe deformities may be required.



Rickets pre-treatment: irregular widened epiphyseal plates, with cupping and fraying of the metaphyses, and bowing of long bones.



Rickets post-treatment: the epiphyses and metaphyses assume a more normal appearance.



'Rickety rosary': costochondral junction enlargement (arrowheads).

Rotator-cuff disease

Characteristics

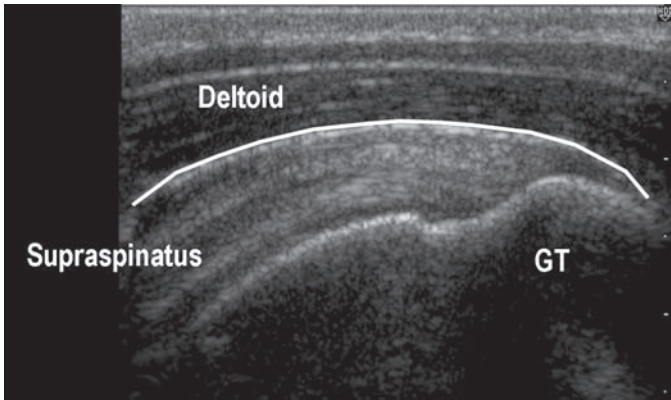
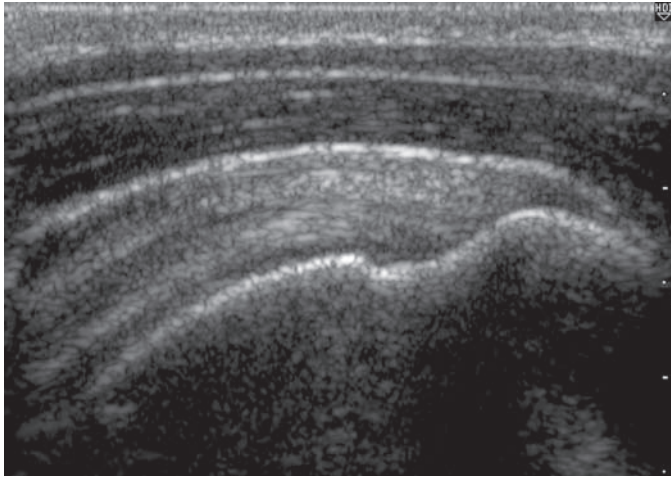
- The rotator cuff comprises the tendinous insertions of four muscles around the humeral head.
- Together, the cuff functions as a mass depressor of the humeral head.
- The four muscles are:
 - Supraspinatus – inserting on the greater tuberosity.
 - Infraspinatus – inserting on the greater tuberosity.
 - Teres minor – inserting on the greater tuberosity.
 - Subscapularis – inserting on the lesser tuberosity.
- Spectrum of disease ranging from ‘impingement syndrome’, which is a tendonopathy of the rotator cuff, to massive degenerative cuff tears.
- Mainly an age-related tendonopathy.
- Acute traumatic cuff rupture is rare – 1%–3%.

Clinical features

- Impingement:
 - Age 40–60.
 - Poorly localised pain over greater tuberosity and deltoid area.
 - Unable to sleep on the affected shoulder.
 - ‘Painful arc’ 60°–120° – Neer’s Sign.
 - Able to maintain power in all muscle groups when pain abolished by local anaesthetic – Neer’s test.
- Cuff tear:
 - Age > 40.
 - Poorly localised pain over greater tuberosity and deltoid area.
 - Unable to sleep on the affected shoulder.
 - Difficulty lifting arm and carrying – may struggle with the kettle.
 - Trick movements to shorten the lever arm and reduce the load on the cuff by keeping the hand closer to the body.
 - May progress to cuff-tear arthropathy.

Radiological features

- Gleno-humeral and axillary view may be normal.
- Sclerosis of the under-surface of the acromion may be seen – ‘Sourcil’ (‘eyebrow’) sign.
- Late cuff disease – humeral head rises breaking the Shenton-equivalent line of the shoulder.
- Ultrasound – high resolution USS is excellent in detecting small and medium-sized cuff tears with greater sensitivity than MRI in experienced hands. Dynamic investigation allowing assessment of subacromial impingement. Unable to ‘look’ under the scapula and, therefore, cannot assess large and massive tears as well as MRI. Fatty atrophy of the relevant muscle bellies is less well appreciated than on MRI.

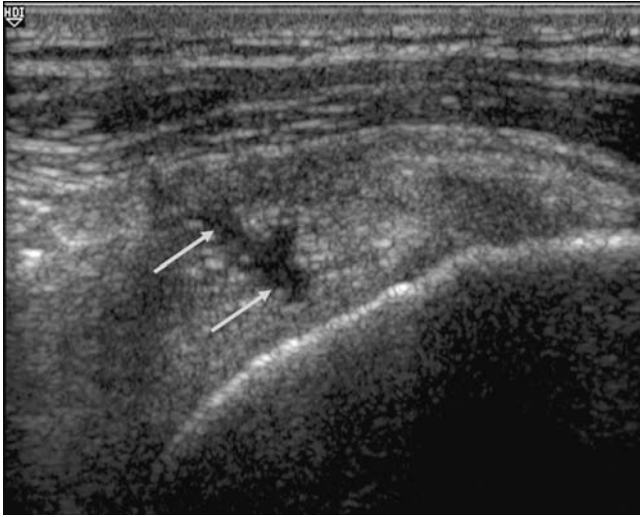

Normal USS appearance of the supraspinatus tendon (GT = greater tuberosity).

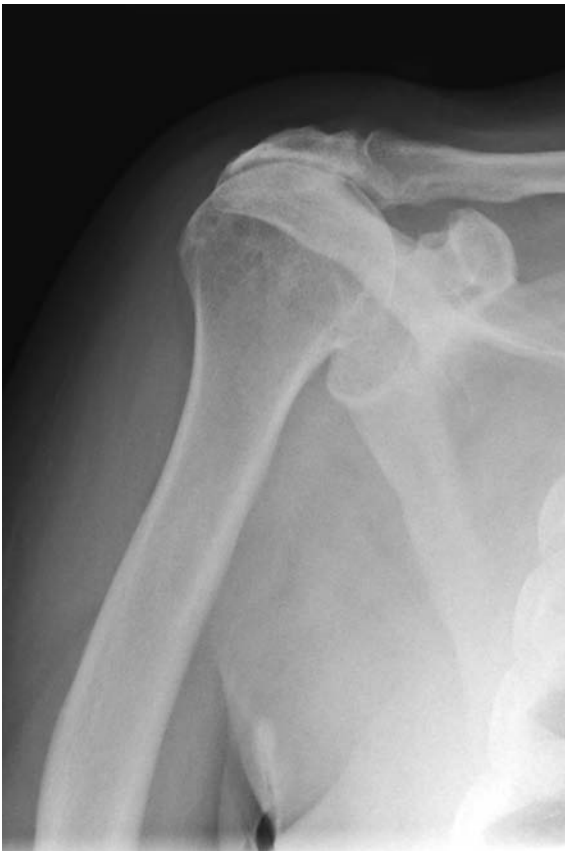- USS is also useful for accurate placement of injections – subacromial, glenohumeral or ACJ.
- MRI – the current gold standard, but can give false positive results for cuff tears in pure impingement.

Management

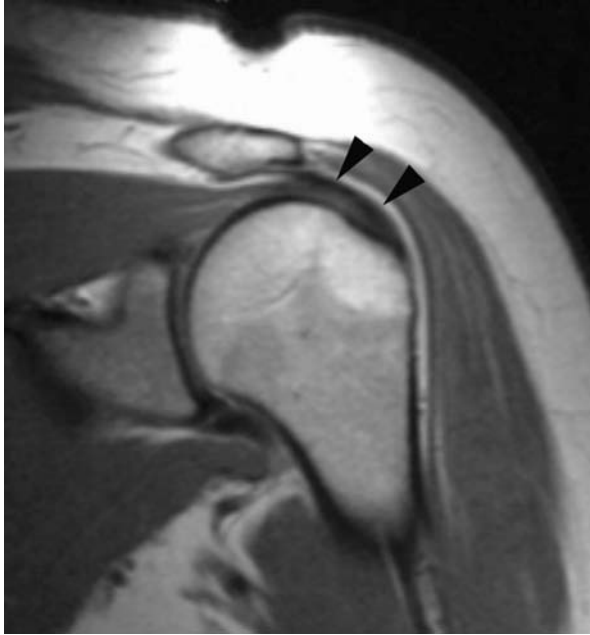
- Non-operative:
 - Sub-acromial injection of steroid and local anaesthetic.
 - Physiotherapy to strengthen/maintain remaining cuff muscles.
 - Analgesia/glenohumeral injection in massive cuff tears.
- Operative:
 - *Sub-acromial decompression* – arthroscopic or open.
 - *Repair of the rotator cuff* – open or arthroscopic.
 - *Debridement of the rotator cuff* – arthroscopic but no repair.
 - *Shoulder replacement* – for cuff arthropathy failing non-operative treatment, possibly with the reverse polarity ‘delta’ shoulder.



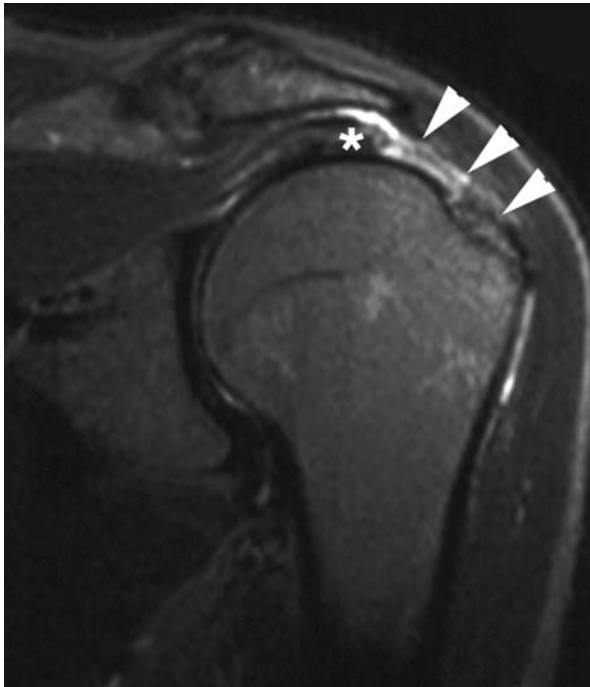
Partial thickness tear of the supraspinatus tendon.



Subacromial articular impingement. This appearance is often associated with advanced degenerative change/disruption of the rotator cuff.



Normal MR appearance of an intact supraspinatus tendon (arrowheads).



STIR: coronal oblique MRI demonstrating a full thickness tear of the supraspinatus tendon (arrowheads). The retracted supraspinatus muscle is clearly seen (asterisk).

Characteristics

- Triplanar deformity of the spine with lordosis, rotation and lateral wedging of vertebrae.
- Classified as **structural** or **functional** and more formally (by cause) by Scoliosis Research Society:
 - Idiopathic
 - Neuromuscular.
 - Neurofibromatosis.
 - Mesenchymal deformities:
 - Connective tissues.
 - Mucopolysaccharidoses.
 - Bone dysplasias.
 - Metabolic bone disease.
 - Endocrine disease.
 - Traumatic.
 - Infection.
 - Tumour.
 - Spondylolisthesis.
 - Adulthood spinal deformity:
 - Late presentation and true adult deformity.

Clinical features

- Idiopathic scoliosis most common in girls at adolescent growth spurt.
- Convexity usually to the right (idiopathic).
- Pelvic obliquity may be the presenting feature – ‘unequal leg lengths’.
- Careful developmental history including sexual development.
- On examination look for abnormal skin/hair changes over the spine, spinal alignment (plumb line from C7 should fall in the gluteal cleft and on spinal flexion a ‘rib hump’ will appear (due to spinal rotation in a structural deformity) on the side of the curve convexity.

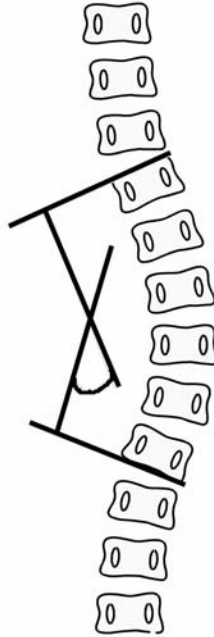
Radiological features

- Standing PA film of whole spine, lateral standing and supine lateral bending.
- Cobb angle – method of measuring the degree of scoliosis; choose the most tilted vertebrae above and below the apex of the curve. The angle between intersecting lines drawn perpendicular to the top of the top vertebrae and the bottom of the bottom vertebrae is the Cobb angle.
- Look for structural abnormality within the vertebrae.

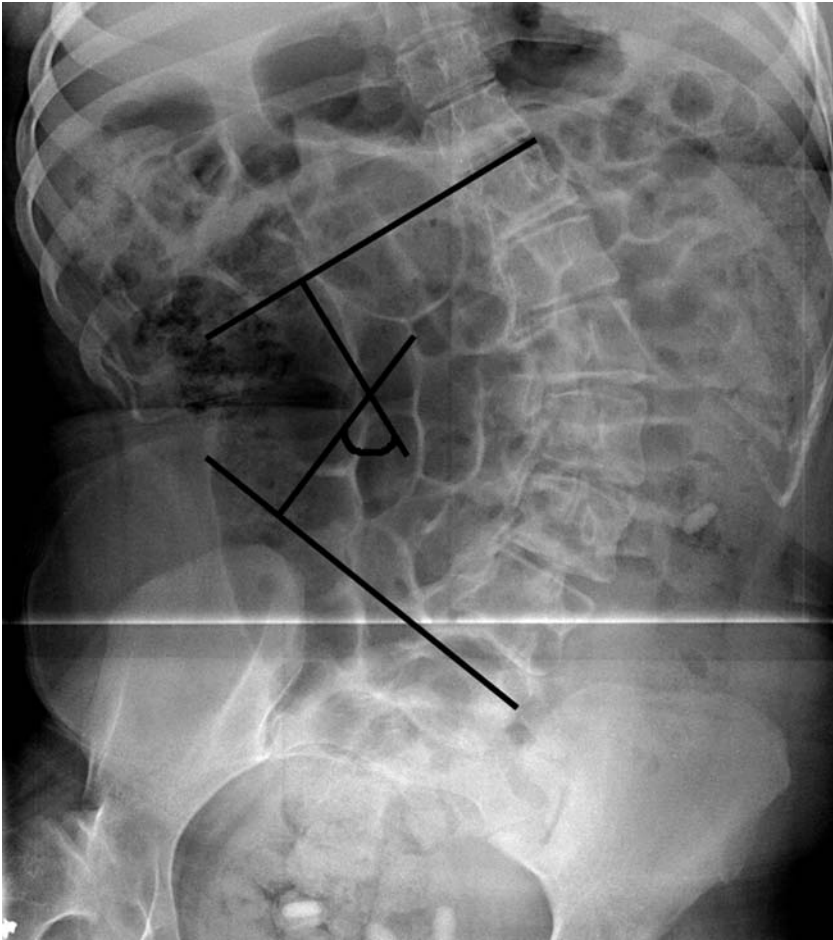
Management

- Initially observe and assess the progression – may not need any treatment.

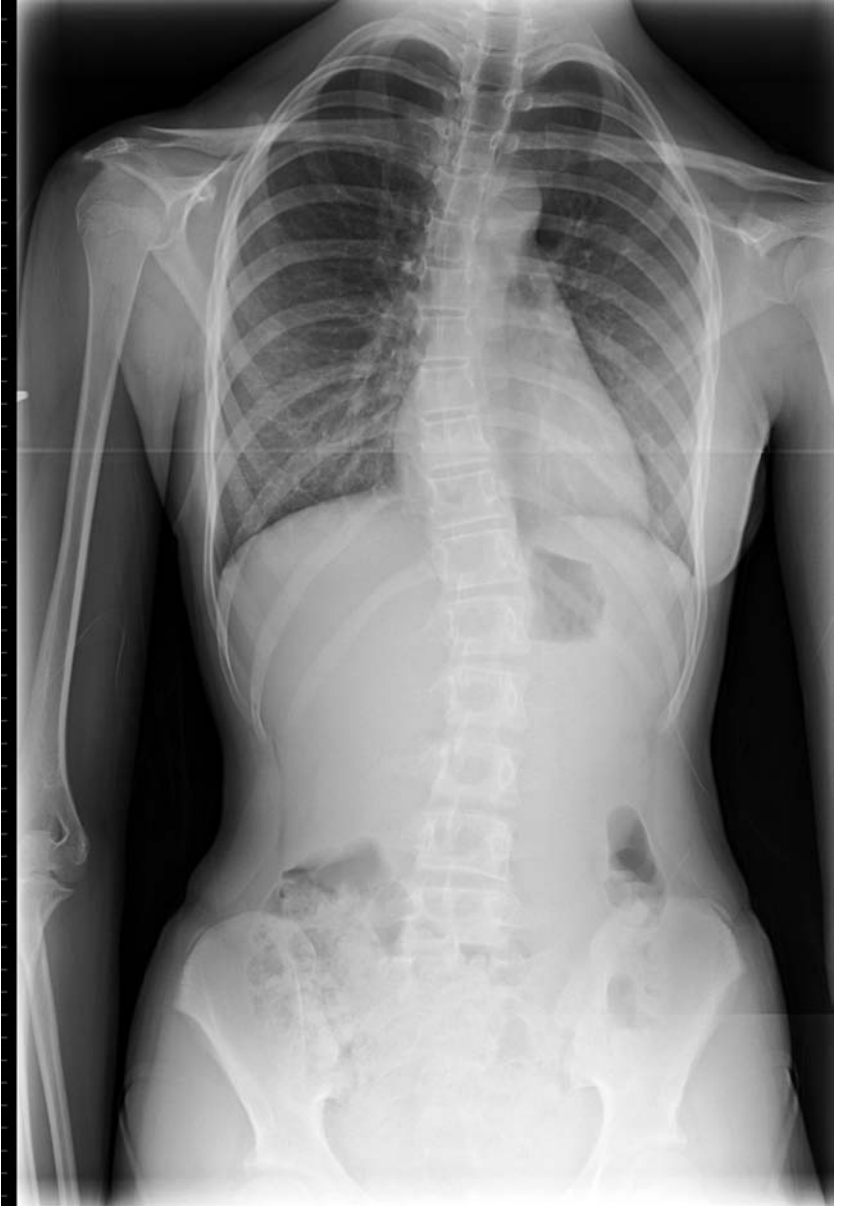- Non-operative – 25° – 45° curves with growth potential – bracing is controversial – poor compliance as must be worn 23 hours a day! The idea is to provide passive resistance to prevent the curve from worsening.
- Operative intervention – correction of deformity and instrumented fusion by posterior, anterior or anterior and posterior approaches.



Diagrammatic representation of how to measure the Cobb angle.



Cobb angle in practice.



Idiopathic scoliosis.

Scheuermann's disease

Characteristics

- Wedging of three adjacent vertebra (>5 degrees).
- Most common cause of structural kyphosis in thoracic and thoracolumbar spine.
- Unknown aetiology but strong family history.
- Usually seen in children/adolescents.
- $M > F$.
- Associated with spondylolysis and scoliosis.

Clinical features

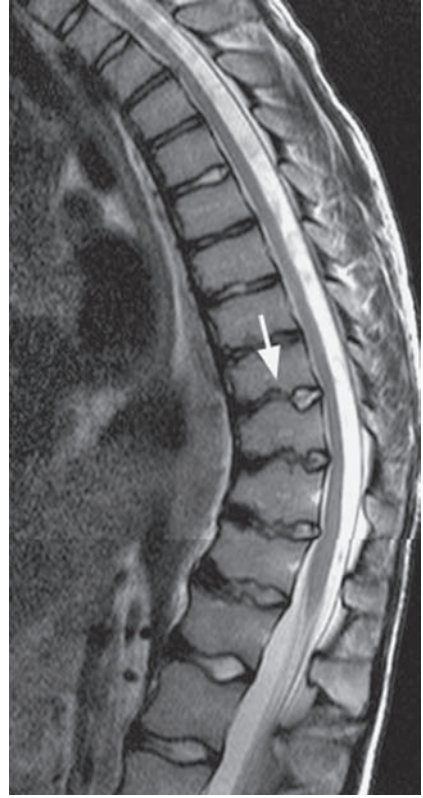
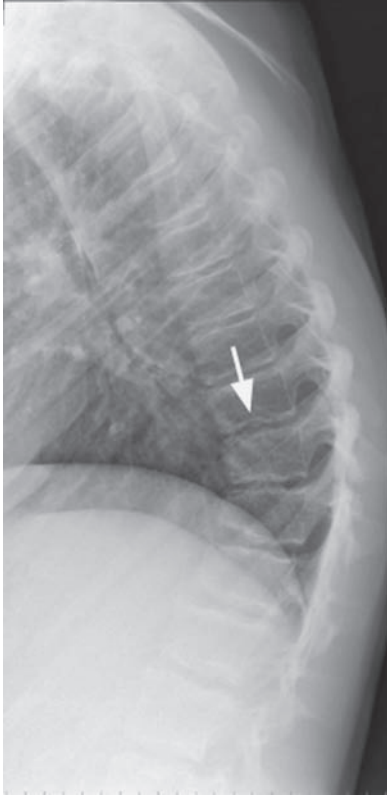
- Non-reversible hyperkyphosis in thoraco-lumbar spine with pain at the apex of the deformity.
- Hyperlordotic lumbar spine to compensate – associated with lumbar pain.
- Tight hamstrings.
- Poor posture generally.
- Back pain usually resolves as skeleton stops growing.

Radiological features

- Wedging of three adjacent vertebra (>5 degrees).
- Anteroposterior vertebral body diameter is increased.
- Disc space may be mildly narrowed.
- Vertebral body endplate depression (Schmorl's node) in up to 30%.
- Thoracic kyphosis (normally 25° – 40°) $>45^{\circ}$.
- Thoracolumbar kyphosis $>30^{\circ}$ – as there is straightening of the normal thoracolumbar spine.

Management

- Watch and wait until growth stops – analgesia.
- Exercise programme for posture – spinal strength, endurance and ROM.
- Optimize weight.
- Consider operative intervention if
 - $>75^{\circ}$ thoracic kyphosis with persistent pain
 - $>55^{\circ}$ rigid thoracic kyphosis.



Scheuermann's disease; plain X-ray and corresponding sagittal T2 MRI. Mild wedging of lower thoracic vertebral bodies, resulting in an increased kyphosis. Associated end plate irregularity and end plate depression – 'Schmorl's nodes' (arrows).

Septic arthritis – native and prosthetic joints

Characteristics

- Acute infection of a joint – usually monoarthritis, but may be at multiple sites.
- Usually bacterial; *Staphylococcus* being the most common infective group of organisms.
- Affects all ages (more common in young/old).
- Watch for immunodeficiency, e.g. steroids/chemotherapy, diabetes, HIV.
- Lower extremity (75%); over pressure points in diabetic foot.
- May originate from osteomyelitis or result in osteomyelitis.

Clinical features

- History of antecedent illness, recent surgery including dental work.
- Systemic illness – patients usually febrile and unwell.
- Hot, swollen, painful joint.
- Usually severely restricted movement and commonly held in a position as to reduce the pressure within the joint, e.g. in a septic knee, the patients hold the knee in approximately 10° – 15° flexion to relax the posterior capsule.
- Raised WBC (neutrophils), CRP and ESR. May have positive blood cultures.

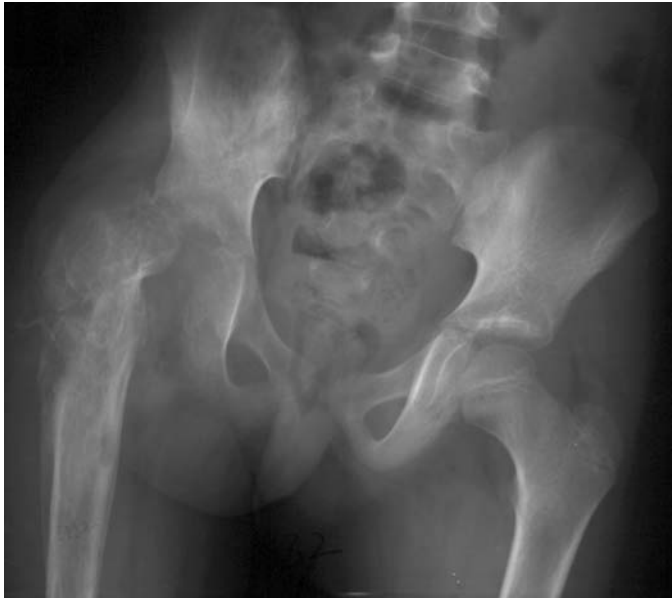Radiological features

- Initial radiographs often normal.
- Soft-tissue swelling secondary to local hyperaemia and oedema.
- Joint distension \pm subluxation of hip and humerus in children.
- Joint-space narrowing indicates rapid development of destruction of articular cartilage.
- Small erosions in articular cortex, loss of cortical outline and reactive bone sclerosis seen after about 8 to 10 days.
- Implants: lucency around the implant, subsidence and bone loss.

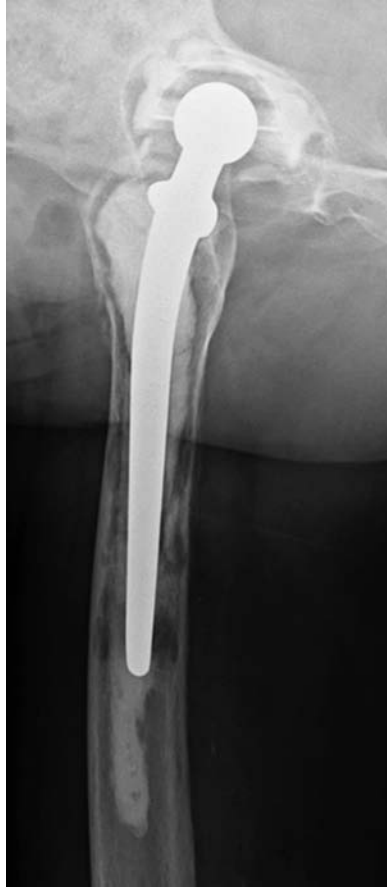Management

- Patient resuscitation if shocked.
- Careful aseptic aspiration of the joint – send for urgent Gram stain, culture and sensitivity, and crystals.
- If patient unwell, start empirical antibiotics (now specimen taken), but if patient systemically stable await microscopy.
- If positive for organisms, then the joint is likely to need debridement (open or arthroscopic), but repeated aspiration and prolonged antibiotics have been used as a successful treatment of septic arthritis by rheumatologists for some time.

- With arthroplasty, debridement is unlikely to succeed unless the infection is 'early' – between 2 and 6 weeks after implantation. Otherwise a formal (one- or) two-stage revision will be needed.
- Antibiotics (intravenous initially) will be needed up to 6 weeks, but local microbiological advice must be sought and the regime of antibiotics determined by the sensitivities from the specimens.
- Long-term suppressive antibiotic therapy is sometimes needed for persistent joint sepsis, particularly if an infected implant is not being removed.



Grossly disorganised and subluxed right hip joint secondary to a 'missed' septic arthritis.



Prominent zone of lucency at the bone–cement interfaces of both the femoral and acetabular components due to loosening.

Characteristics

- Autosomal recessive disorder resulting in substitution of valine for glutamic acid at position 6 of the beta-globin gene.
- Red blood cells are sickle shaped which are less deformable.
- Microcirculation occlusion leads to tissue hypoxia.
- Common in patients of black African descent.
- Homozygous and heterozygous forms, with major and minor clinical variants accordingly.

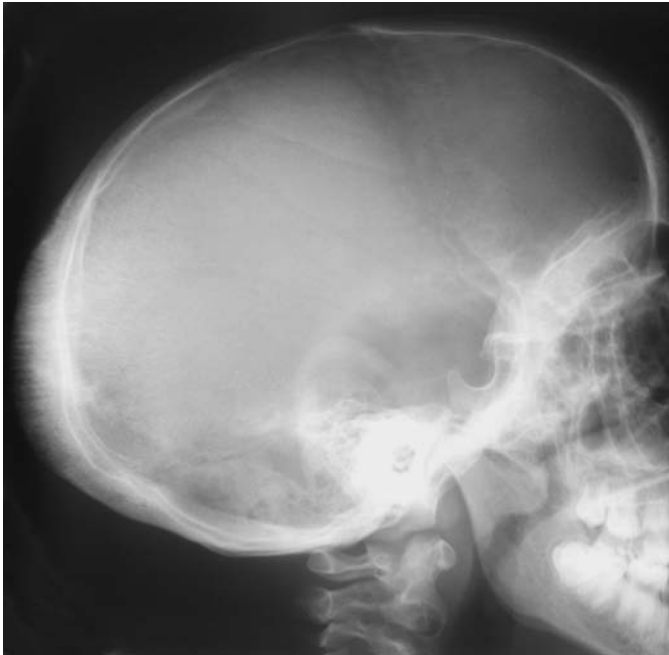Clinical features

- *Vaso-occlusive* – pain is the commonest symptom. Vaso-occlusion within bone can lead to avascular necrosis (femoral and humeral head typically).
 - Dactylitis (finger/toe swelling) secondary to vascular occlusion.
 - Abdominal organ involvement may mimic an acute abdomen.
- *Haematological* – marrow hyperplasia exacerbates anaemia.
- *Infectious* – splenic dysfunction results in susceptibility to infection by encapsulated organisms (*S. pneumonia*, *H. influenza*, *N. meningitidis*). Decreased resistance to *Mycoplasma*, *Salmonella*, *Staphylococcus* and *Escherichia coli* also seen. *Salmonella* species is the most common bacterial pathogen linked to bone (typically diaphyseal) and joint infection in sickle cell disease, and is thought to be implicated in over 50% of cases.

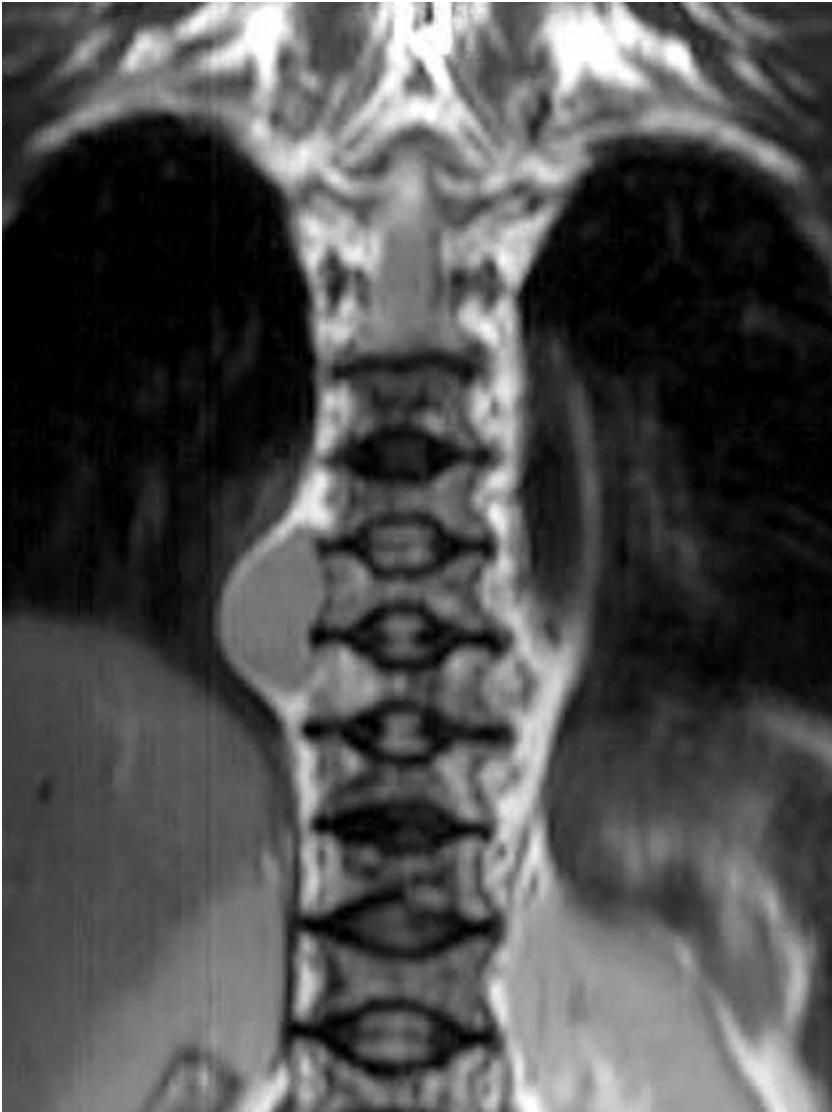Radiological features

- *AVN/bone infarcts*:
 - Mainly in diaphysis of small tubular bones (children); in metaphysis and subchondral areas of long bones (adults) – see separate section.
 - Dactylitis – patchy lucency with periosteal reaction in metatarsal and metacarpal bones.
 - Vertebra – endplate infarcts resulting in central endplate depression and characteristic ‘H’-shaped vertebral bodies.
 - Bone scan – Increased overall skeletal uptake (high bone-to-soft tissue ratio); decreased within 24 hours in acute infarction.
- *Marrow hyperplasia*:
 - Widening of the diploe with thinning of the outer table.
 - vertical hair-on-end striations.
 - Osteoporosis with thinning of trabeculae.
 - Biconcave ‘fish’ vertebrae due to bone softening in 70%.
 - Widening of medullary spaces thinning of cortices.
 - Coarsening of trabecular pattern in long and flat bones.
 - Extramedullary haemopoiesis.
 - Pathologic fractures.
- *Osteomyelitis/septic arthritis*.

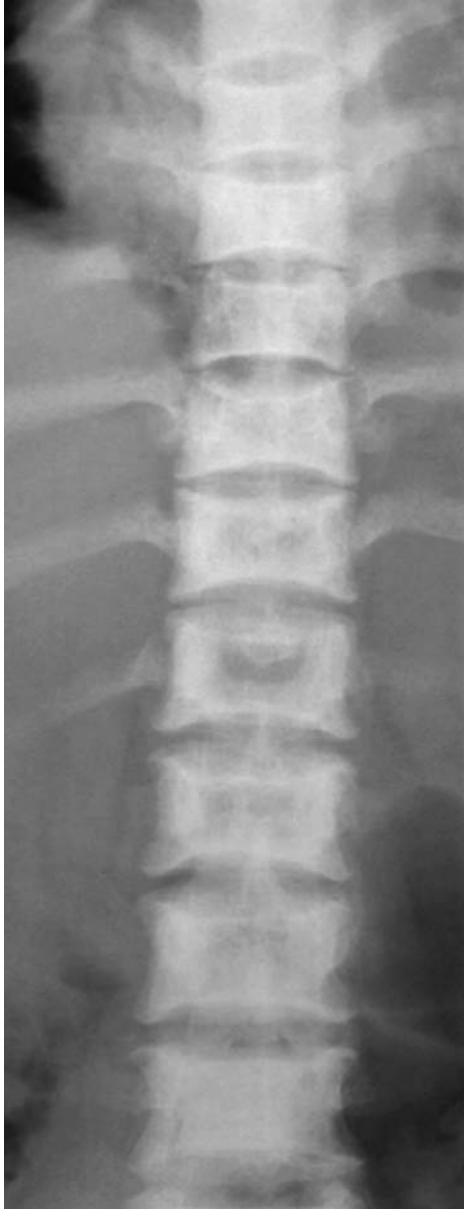- *Osteopenia*, periosteal inflammation and later sclerosis are seen.
- *MRI* – important role in demonstrating loculated fluid collections with or without sequestra, and cortical defects with adjacent soft tissue collections.
 - Fat-saturated T2-weighted sequences show fluid as high signal intensity within the bone marrow and a central sequestrum of low signal intensity.
 - Also useful for demonstrating communication of soft tissue with medullary fluid collections through cortical defects.
 - Intravenous gadolinium enhanced T1-weighted MR imaging is able to demonstrate the irregular, peripheral bone-marrow enhancement around a non-enhancing centre seen in osteomyelitis.



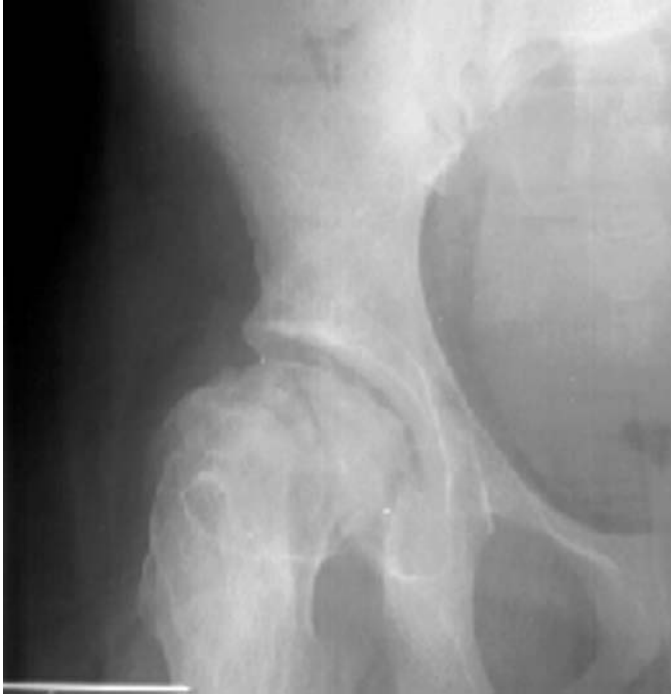Sickle-cell disease: marrow hyperplasia in the skull vault resulting in a 'hair on end' appearance.



Sickle-cell disease: coronal T1 W MRI of the thorax demonstrating a right paravertebral mass, representing extramedullary haemopoiesis. Note the 'H'-shaped vertebral bodies.



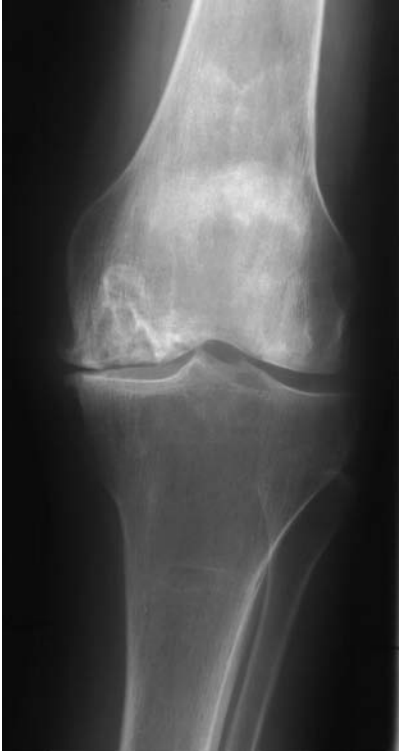Sickle-cell disease: central endplate depression, secondary to infarction, resulting in 'H'-shaped vertebral bodies.



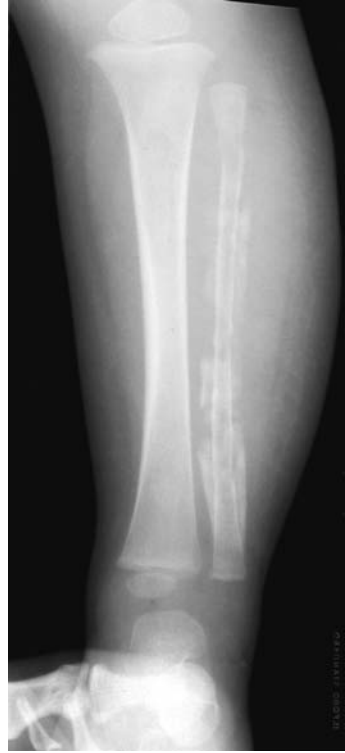Sickle-cell disease: deformity, sclerosis and collapse of the right femoral head secondary to AVN.

Management

- Follow local protocol and consult haematologist.
- Aggressive fluid therapy – avoiding overloading.
- Paracetamol and NSAIDs may be effective, but opioid analgesia often required.
- Oxygen for hypoxia.
- For suspected sepsis, parenteral Cephalosporin, after appropriate cultures.
- Joint replacement for symptomatic degenerate joints following osteonecrosis.



Sickle-cell disease: flattening of the left medial femoral condyle, secondary to AVN, with secondary degenerative changes.



Sickle-cell disease: extensive periosteal reaction along the fibula, with a mottled trabecular pattern, secondary to *Salmonella* osteomyelitis.

Slipped upper femoral epiphysis (SUFE)

Characteristics

- Commonest hip disorder of adolescence (male 13 to 16 years, female 11 to 14 years).
- Commoner in boys with a ratio of 3 to 1.
- Occurs in approximately 2 in 100 000.
- Commoner in obese, but active, patients.
- Unknown aetiology, although genetic and traumatic theories have been proposed.
- Usually seen during a period of rapid growth when the physis appears to be more susceptible to shear forces.
- A history of trauma is given in up to 50% of cases.
- 60% are bilateral.
- Stable (able to weight bear) are distinguished from unstable (not weight bearing) hips. Unstable hips have a 50% risk of future femoral head AVN.

Clinical features

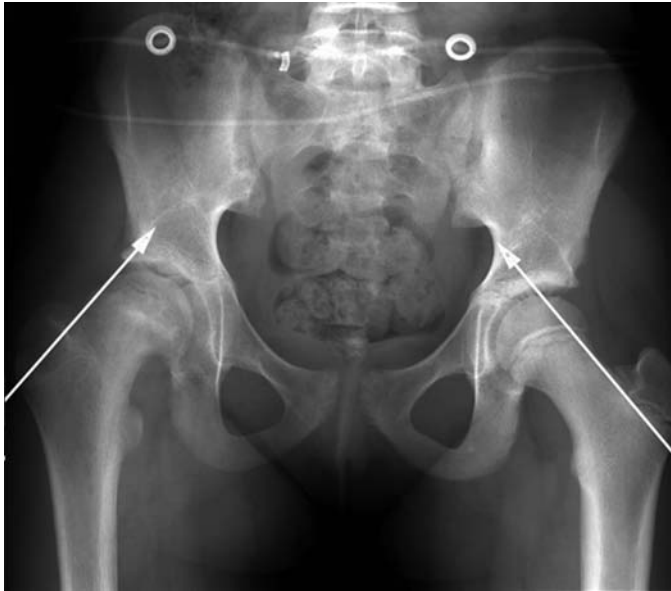- Presents with pain and a limp, not necessarily localised to the hip.
- Depending on the chronicity, limb shortening with a degree of external rotation may be present.
- Muscle atrophy occurs in delayed presentation.
- Pain and limited internal rotation on examination.
- Considered chronic if symptoms greater than 3 weeks.

Radiological features

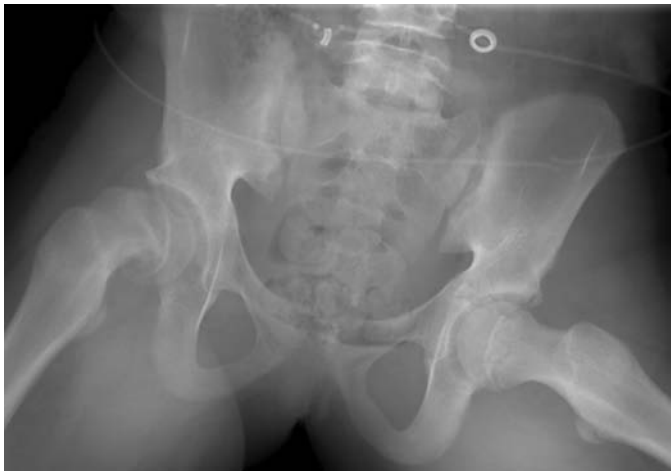- PA and 'frog leg' views are the standard views.
- Widening of the epiphysis with metaphyseal irregularity.
- Posteromedial displacement of the femoral head; this is seen as failure of a line, drawn along the superior femoral neck, to intersect with the femoral head.
- Epiphysis appears smaller due to posterior slippage.
- Slippage may only be seen on the frog leg view – but avoid frog view if the hip is 'unstable'.
- New bone formation (buttressing) seen late.
- Late findings include subchondral sclerosis, cyst formation, osteophyte formation and narrowing of the joint space.
- Ultrasound can be a useful adjunct showing an effusion with early slippage.
- MRI (bilateral) to look for 'pre-slip' if pain but normal X-rays.

Management

- Aimed at preventing further slippage and maintaining function. Always consider the contralateral hip.
- Mainstay of treatment involves surgical pinning *in situ*.



Slipped right femoral capital epiphysis. Note the right line of Klein does not intersect the right femoral capital epiphysis.



Frog leg lateral: postero-medial slip of the right femoral capital epiphysis.

- Following pinning, physeal closure usually occurs.
- Corrective osteotomy can be of functional benefit for significant deformity.
- Complications include avascular necrosis, chondrolysis, deformity and degenerative changes.

Tendinopathy – tendonitis

Characteristics

- Numerous sites in the body are affected by tendon pathology.
- Previously labelled as tendonitis, but histologically there is little true inflammation and hence the increasing use of ‘tendinopathy’/tendonosis.
- Often age-related (‘mucoïd’) degenerative change of the tendon substance.
- Sites involved – mainly rotator cuff (supraspinatus predominantly – see separate entry), Achilles tendon (*see separate entry*), patellar tendon and tibialis posterior tendon.

Clinical features

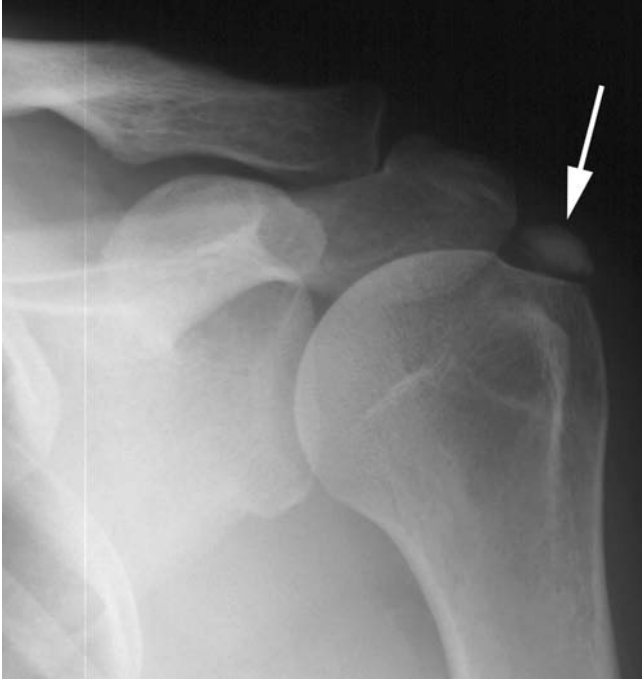- Usually within 30–65 age group.
- Present with pain, loss of function or with acute rupture.
- Tendon pain often predates rupture.
- Tender to palpation with possible palpable thickening.
- Pain on loading the involved tendon, or loss of discrete function, e.g. ankle plantar-flexion in tendo-Achilles rupture.

Radiological features

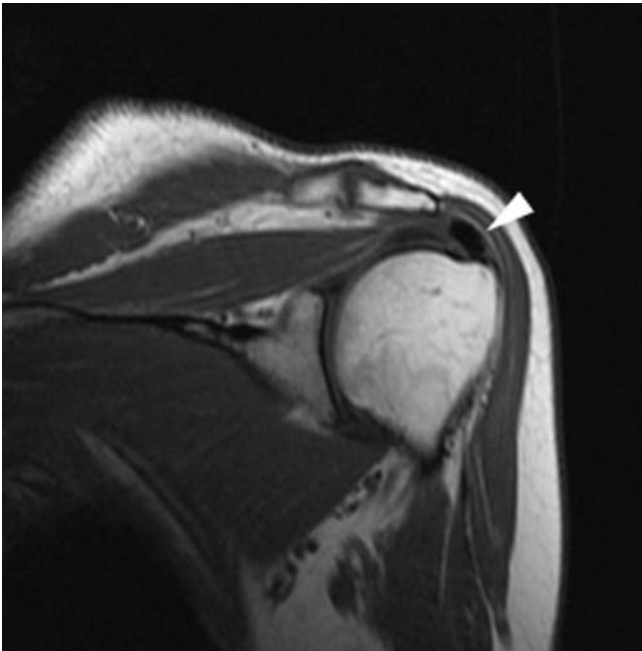
- USS/MRI for confirmation of clinical diagnosis/tendon assessment:
 - Focal thickening of the involved tendon.
 - Increased/heterogenous signal intensity within the tendon on T2/STIR images without disruption of the tendon.
 - Associated fluid in bursae/tendon ‘sheaths’.
 - May be intra-tendinous calcification.
 - Loss of tendon continuity if torn.
 - Associated muscle wasting and fatty atrophy proximal to ruptured tendon e.g. rotator cuff.

Management

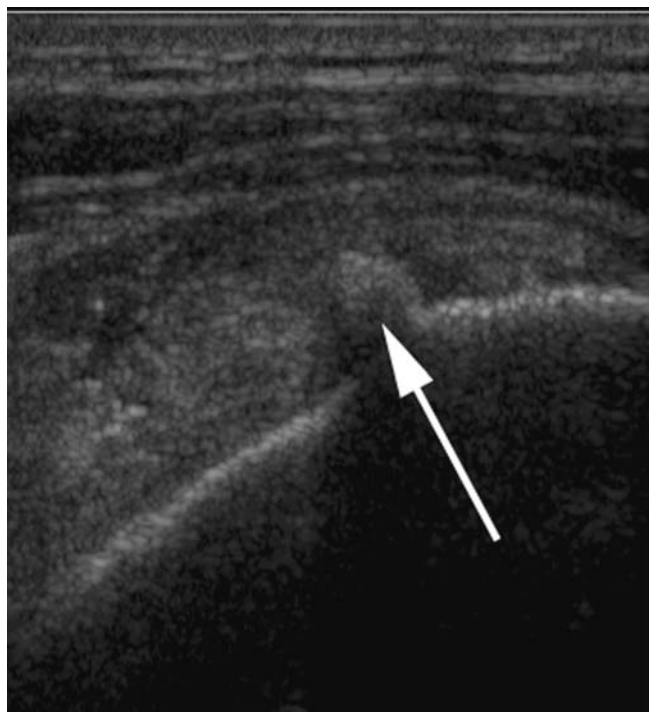- Remove any predisposing factors, e.g. stop the activity which triggers the condition.
- *NSAID* – particularly early proliferative rather than degenerative disease.
- *Physiotherapy* – eccentric loading, i.e. controlled stretching.
- *Possible steroid injection* – controversial because of risk of increased tendon rupture.
- Decompression of adjacent tissues, e.g. subacromial decompression.
- Intratendinous decompression, e.g. Achilles or supraspinatus tendons.
- Surgical repair for ruptured tendon, if possible.



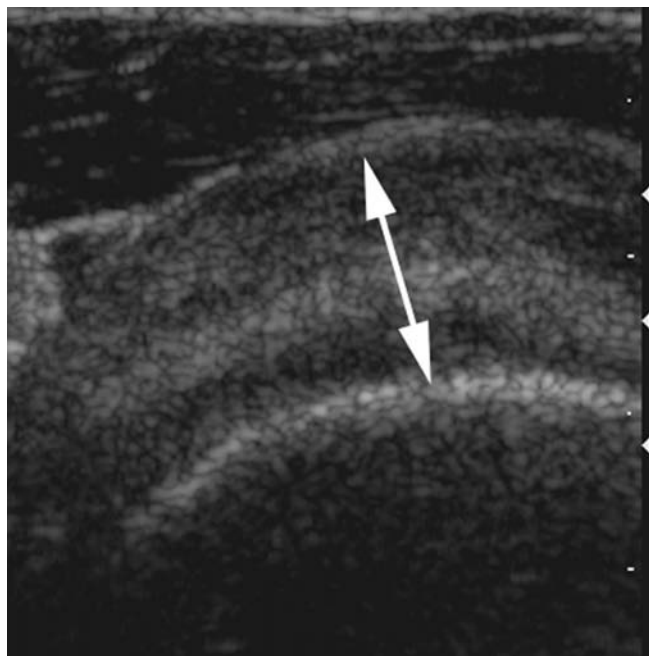
Calcific tendonopathy of the rotator cuff (arrow).



Calcific tendonopathy: coronal oblique T1 W MR. The intra-tendinous calcification appears as low signal (arrowhead).



Calcific tendinopathy: US. Calcified echogenic focus, with posterior acoustic attenuation (arrow), within the supraspinatus tendon.



Supraspinatus tendonitis: US. Diffuse thickening of the supraspinatus tendon.

Tuberculosis

Characteristics

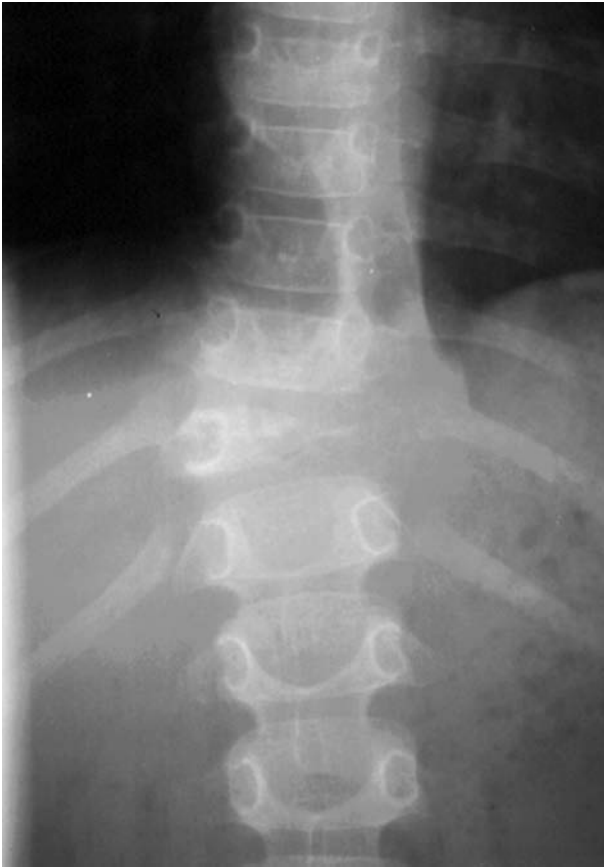- Incidence of tuberculosis (TB) is rising.
- Usually children and young adults.
- 3%–5% of cases involve bone or joints.
- The spine and large synovial joints are most commonly affected.
- One third of orthopaedic TB cases occur in multiple sites.
- Mycobacterium may settle onto synovium, subchondral bone or both – i.e. septic arthritis can develop into osteomyelitis and vice versa.
- Chronic granulomatous reaction with caseous necrosis, as in other tissues, may coalesce to form a central necrotic mass containing dead bone and pus.
- Untreated, ‘cold abscess’ formation and subsequent sinus formation draining to the skin.

Clinical features

- Previous TB or recent exposure to TB.
- Systemic symptoms with weight loss and fever.
- Night pain – during the day active muscle tone splints the joint involved, but relaxation at night causes an increase in pain.
- With spinal TB – groin and back abscesses, lower-limb neurology and vertebral collapse with kyphosis.

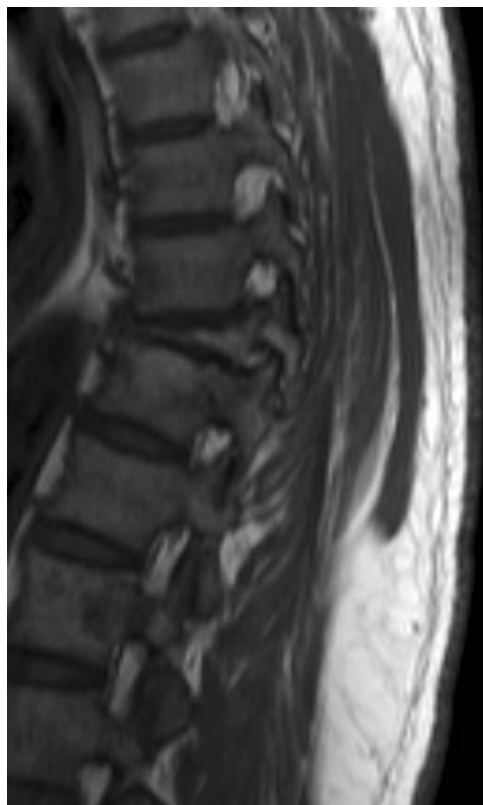Radiological features

- **Tuberculous spondylitis**
- Approximately 50% of skeletal TB involves the spine, most commonly the lower thoracic and upper lumbar levels.
 - The first sign is often demineralisation of the end plate, resulting in loss of definition of its dense margins on plain film, and then involvement of the adjacent intervertebral disc.
 - The loose internal structure of the disc allows dissemination under the anterior spinal ligament and into paraspinal tissues.
 - Calcification within a paraspinal abscess is virtually diagnostic of TB.
 - Untreated disease eventually results in vertebral collapse and anterior wedging, leading to kyphoscoliosis and gibbus formation.
- **Tuberculous osteomyelitis**
 - Isolated tuberculous osteomyelitis in the absence of associated tuberculous arthritis is relatively rare.
 - The femur, tibia and small bones of the hands and feet are the most commonly affected bones with isolated disease.
 - Typically the metaphyses are involved, with radiographic features including osteopenia and poorly defined osteolytic lesions with minimal surrounding sclerosis.



TB spondylitis: vertebra plana – marked compression of the T11 vertebral body secondary to a left paravertebral (Pott's) abscess.

- In the immature skeleton, a helpful feature in distinguishing tuberculous from pyogenic infection is that transphyseal spread tends to occur with TB.
- Two specific types of osteomyelitis are seen more commonly in children and young adults, cystic osteomyelitis and tuberculous dactylitis.
- **Tuberculous arthritis**
 - Characteristically a monoarthritis affecting large weight-bearing joints.
 - The radiological findings are non-specific with osteopenia, soft-tissue swelling, marginal erosions and varying degrees of cartilage destruction, mimicking those of an inflammatory arthritis. The relative absence of sclerosis, periosteal reaction and bone proliferation, and relative preservation of joint space in the early stages, is more typical of TB.

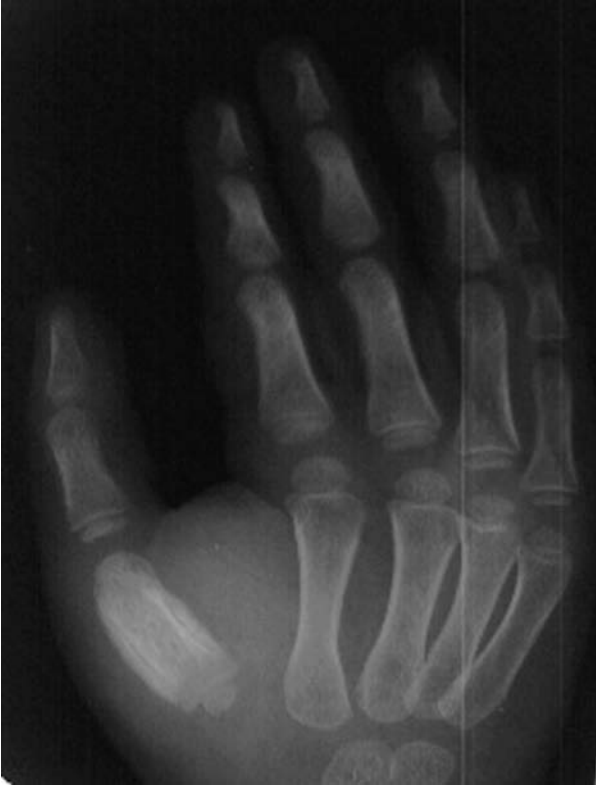

TB spondylitis: sagittal T1 W MRI. Gibbus deformity due to marked collapse of the T11 vertebral body.

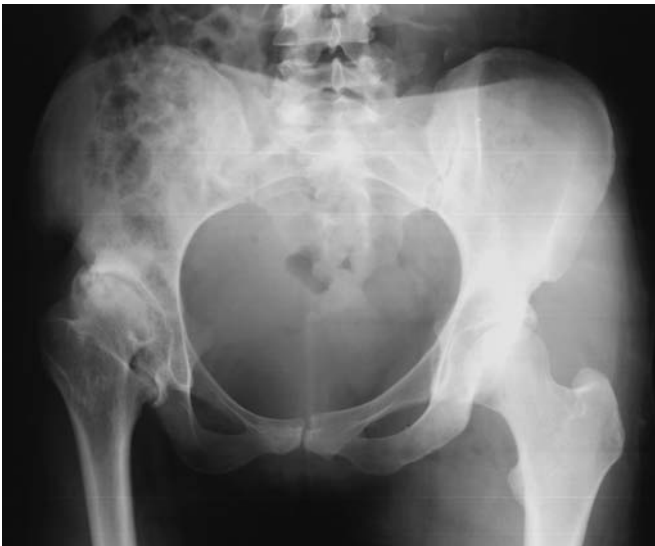- With progression of infection, bone sequestration and sinus formation can develop. The end result is usually fibrous ankylosis of the joint. Bony ankylosis occasionally occurs but is more commonly seen with pyogenic infections.

Management

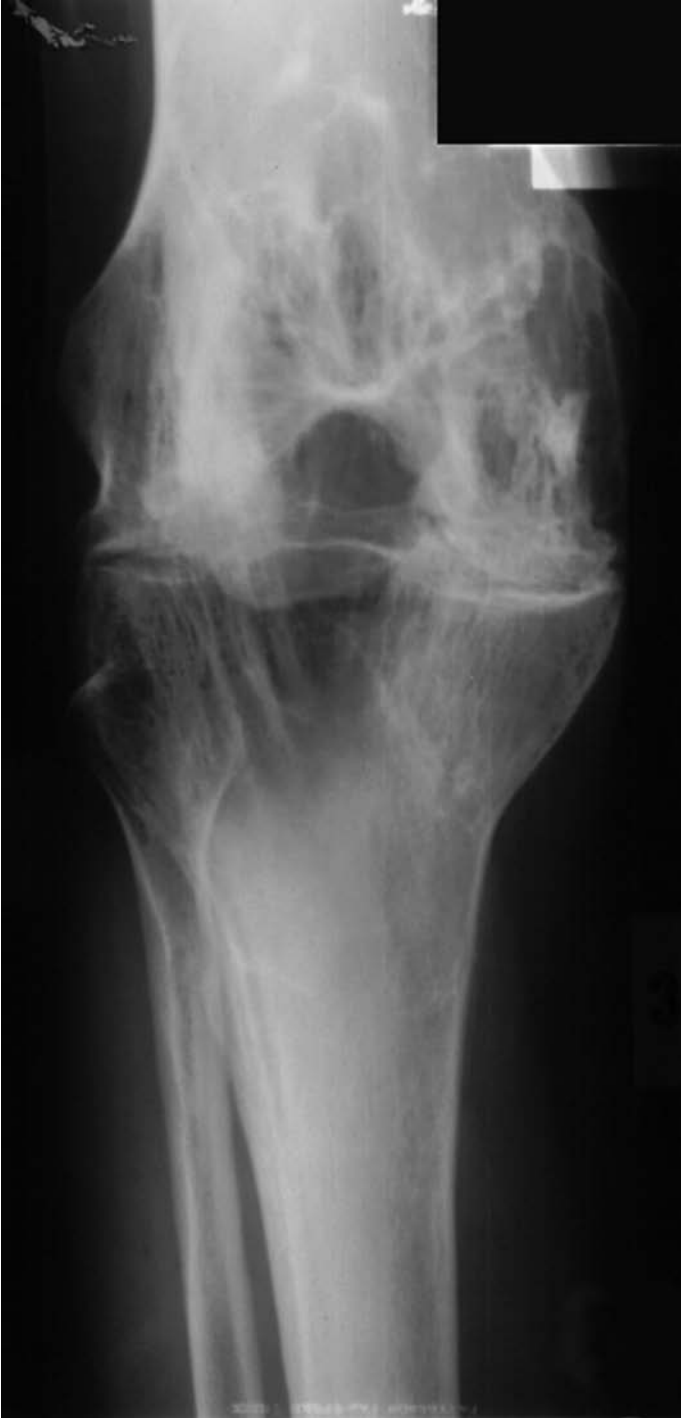- Investigations – raised ESR, CRP and lymphocytes.
- Heaf or Mantoux test.
- Aspiration (10% cases positive), synovial biopsy (80%) and prolonged culture yield acid-fast bacilli.
- Chemotherapy – triple treatment with a regime such as rifampicin, isoniazid and pyrazinamide for 8 weeks and then further rifampicin and isoniazid for up to 1 year.
- Surgical drainage of ‘cold abscess’ and joint washout.
- If the involved joint is destroyed, future arthrodesis or arthroplasty may be performed – again with prolonged chemotherapy.



TB dactylitis: tuberculous osteomyelitis of the first metacarpal with associated periostitis.



TB arthritis of the right hip – note the minimal sclerosis and new bone formation, for the degree of bony destruction.



TB arthritis: ankylosis of the right knee secondary to TB arthritis.

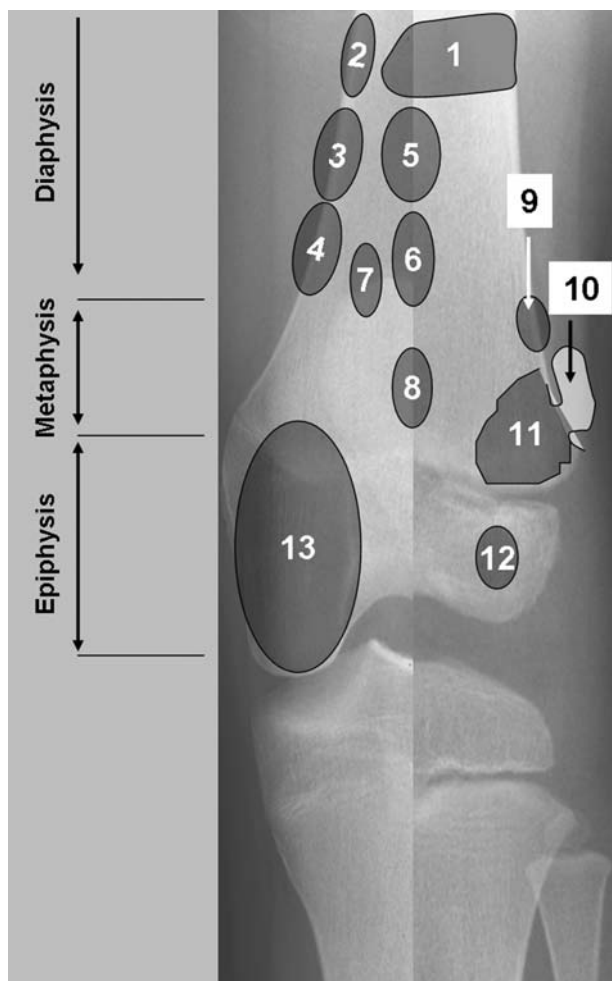
Tumours of bone (benign and malignant)

Characteristics

- Benign or malignant.
- Primary or secondary.
- Diverse pathology depending on histology, stage and patient age.
- Lesions classified by the dominant histological cell type.
- Staged by Enneking, assessing 'aggressivity' and spread (stages 1, 2 and 3) and further adapted by the American Joint Committee on Cancer (type A or B):
 - Stage 1 low grade lesion.
 - Stage 2 high grade lesion.
 - Stage 3 metastases.
 - Type A intracompartmental.
 - Type B extracompartmental.

Clinical features

- Age is important as many tumours are age-specific:
 - Children – many benign tumours, but beware:
 - Ewing's sarcoma.
 - Osteosarcoma.
 - 30–50s chondrosarcoma and fibrosarcoma present mainly in early middle age.
 - >50s myeloma (commonest primary bone tumour) rarely presents earlier.
 - >70s metastases more common than primary bone tumours.
- Pain is a common feature and persistent resting/night bone pain must be investigated.
- Swelling/lump – may be present for some time but become symptomatic/enlarge.
- *Trauma* – probably coincidental – self examination after minor trauma revealing a 'new lump' or persisting pain after injury not previously acknowledged.
- *Asymptomatic*, e.g. CXR for unrelated reason revealing humeral lesion
- Pathological fracture.
- *Neurological symptoms* – beware labelling a patient with sciatica if the symptoms and signs are not classical.



Sites of origin of primary bone tumours.

- 1 Ewing’s tumour, reticulum cell sarcoma, myeloma, chondrosarcoma.
- 2 Adamantinoma.
- 3 Osteoid osteoma.
- 4 Chondromyxoid fibroma.
- 5 Fibrous dysplasia.
- 6 Enchondroma, chondrosarcoma.
- 7 Fibrosarcoma.
- 8 Unicameral bone cyst, osteoblastoma.
- 9 Fibrous cortical defect.
- 10 Osteochondroma.
- 11 Osteosarcoma.
- 12 Chondroblastoma.
- 13 Giant cell tumour.

The left half of the X-ray relates to tumours in an adult population whilst the right half relates to the paediatric age group.

- *Marginal* – only for benign lesions as 50% recurrence rate if margin crosses into reactive zone.
- *Wide-local* – for low recurrence risk malignant disease or in conjunction with radiotherapy for high grade.
- *Radical – en bloc* compartment excision for high grade tumour – may require amputation, but might be suitable for megaprosthetic replacement and ‘limb salvage’.
- *Amputation* – may allow definitive excision and early mobilization with a prosthetic limb – this may be the only option in high grade disease.
- *Chemotherapy* – multi-agent – pre- and post-operative.
- *Radiotherapy* – with chemotherapy as an alternative to amputation (e.g. Ewing’s) or for inaccessible or diffuse disease.

Tumours of bone – Benign (separate section for bone cysts, ABCs)

Non-ossifying fibroma

Characteristics

- The most common benign tumour of bone is a non-ossifying fibroma – a developmental disorder where a collection of fibrous tissue shows delayed ossification.
- M > F.
- Peak age 10–20.
- Metaphyses of long bones, especially around the knee.

Clinical features

- Usually asymptomatic, but possible pathological fracture.

Radiological features

- Oval radiolucency surrounded by thin dense bone – narrow zone of transition.
- Usually aligned along the long axis of the metaphyseal cortex of long bone.
- Usually resolves with age.

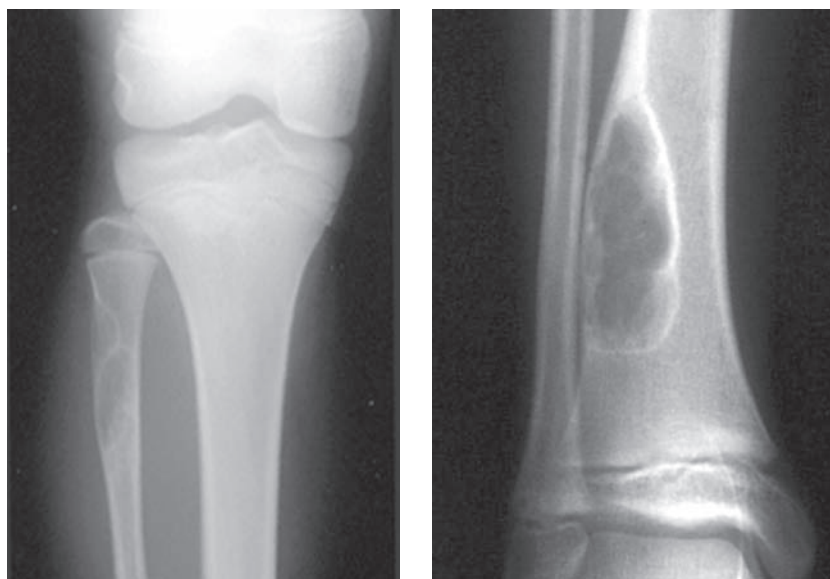
Management

- Reassurance.
- If persistent and symptomatic, then curettage and grafting.

Fibrous dysplasia

Characteristics

- Benign developmental anomaly of bone precursors – mixture of osteoid, woven bone and fibrous tissue instead of lamellar bone.



Non ossifying fibroma of the proximal fibula and distal tibial.

- Gritty feel.
- Malignant transformation in 5%–10% polyostotic disease.
- Age: first–second decade (highest incidence between 3 and 15 years), 75% before age 30; progresses until growth ceases; M : F = 1 : 1.
- Monostotic form (70%–80%):
 - Second–third decade.
 - Ribs (28%), proximal femur (23%), craniofacial bones (10%–25%).
- Polyostotic form (20%–30%):
 - Mean age of 8 years.
 - Unilateral: femur (91%), tibia (81%), pelvis (78%).
 - May be associated with McCune–Albright’s Syndrome – precocious puberty.

Clinical features

- Small lesions usually asymptomatic.
- Larger lesions prone to fracture or deformity.

Radiological features

- Normal bone architecture altered and remodelled.
- Metaphyseal or diaphyseal cystic areas of mixed lucency/sclerosis sometimes described as ‘ground glass’.
- Possible deformity or pathological fracture – proximal femoral deformity described as shepherd’s crook.

Management

- Treat symptomatically – for large lesions, curettage and bone graft.

Osteoid osteoma

Characteristics

- Benign self-limiting collection of osteoblastic material, surrounded by vascular fibrous tissue and then cortical bone.
- Often requires intervention because of pain.
- Usually a solitary and small lesion in any site.
- 50% femur/tibia.
- Peak age 5–25 years, rare over 40.

Clinical features

- Pain is the main feature.
- Pain usually worse at night and relieved by aspirin in 20–30 minutes in 75%–90%.

Radiological features

- Small radiolucent nidus surrounded by fusiform sclerotic cortical thickening.
- Intensely increased radiotracer uptake on bone scan.
- CT most accurate for diagnosis; small well-defined nidus surrounded by variable amount of sclerosis.

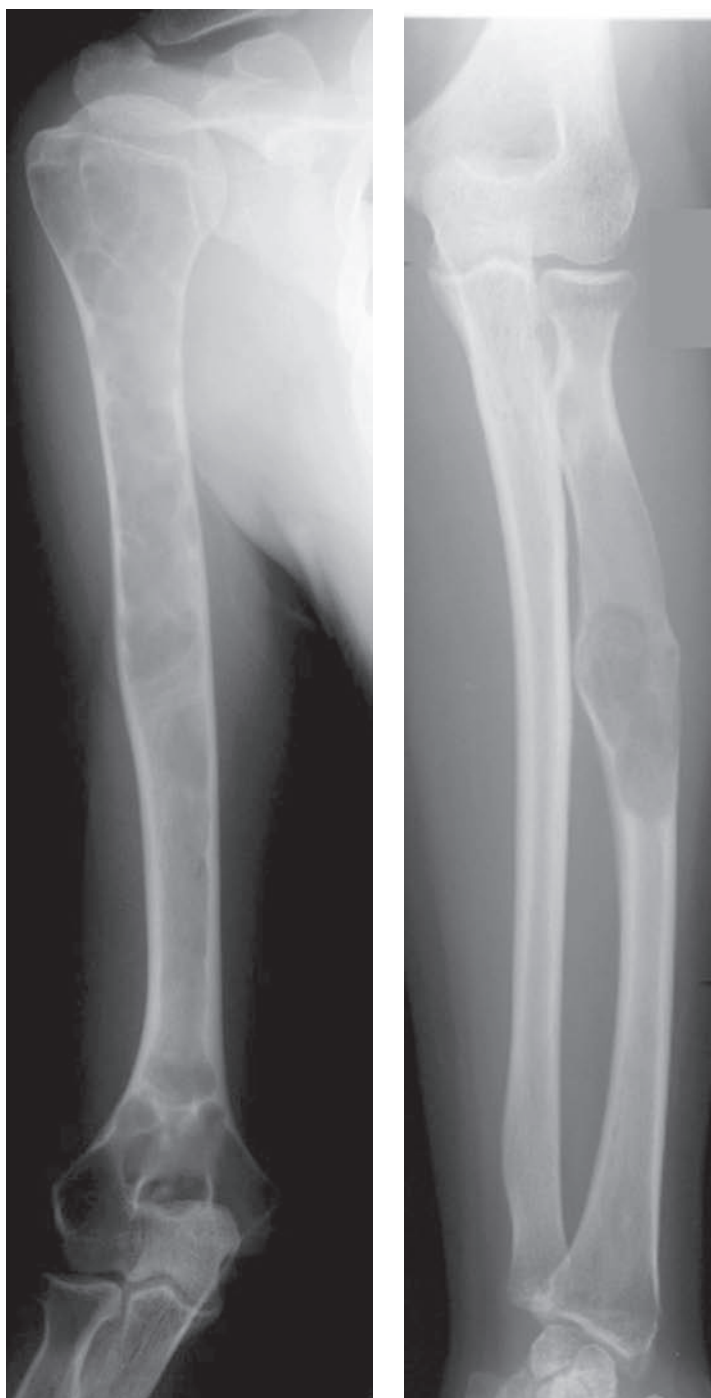
Management

- NSAID and reassurance.
- Surgical excision.
- CT guided radio-frequency ablation.

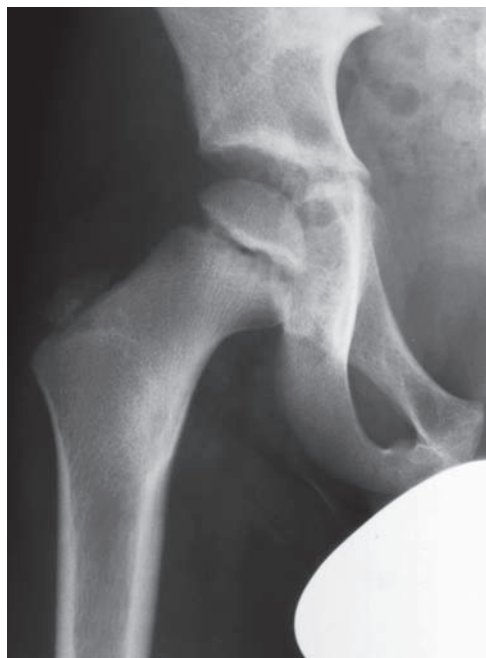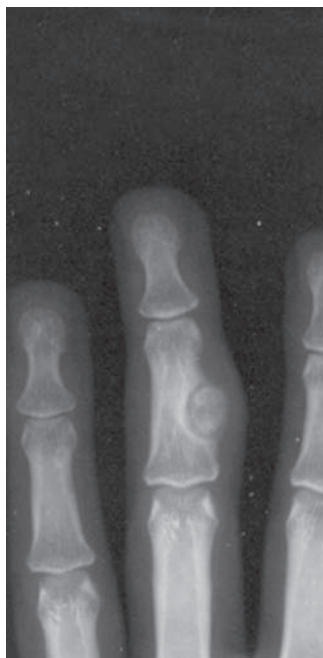Chondroma/enchondroma

Characteristics

- Benign tumour of cartilage mostly from within the medullary cavity.
- 10% benign bone tumours.
- Usually metaphyseal.
- Beware the periosteal (juxtacortical) form – this can only be differentiated from osteosarcoma on MRI and biopsy.
- 75% solitary.
- 25% multiple (Ollier's disease or Maffucci's syndrome).
- Ollier's disease has a 50% malignant transformation rate.



Fibrous dysplasia: two cases. Diffuse 'ground-glass' attenuation of the right humerus and a more focal area within the mid right radius. Note the pathological fracture within the mid radius.



Osteoid osteoma (OO): two cases. Juxtacortical OO arising from the middle phalanx of the middle finger. Right femoral OO medial aspect of the inter-trochanteric area.

- Maffucci's syndrome associated with multiple haemangiomas in which almost complete risk of transformation.

Clinical features

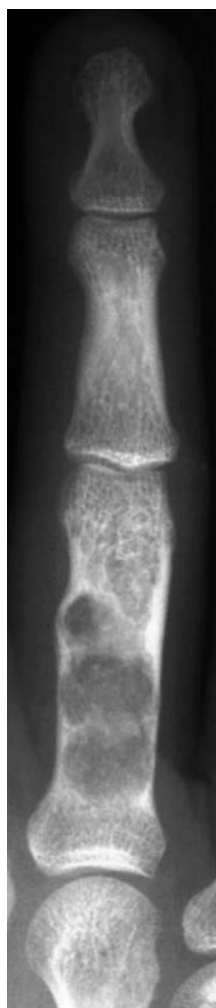- Usually present with a painless swelling or as an incidental finding.
- Often present with fractures.
- >50% small bones hands and feet.

Radiological features

- Oval lucency with fine marginal line.
- Scalloped erosion of endosteal surface.
- 'Ground glass' appearance due to cartilage content.
- Cortex may be expanded but is classically intact without periosteal reaction.

Management

- Watch.
- Repeat X-ray at 6-monthly intervals.
- Possible curettage and grafting if high risk of fracture and no sign of transformation.
- Periosteal form needs wide local excision.

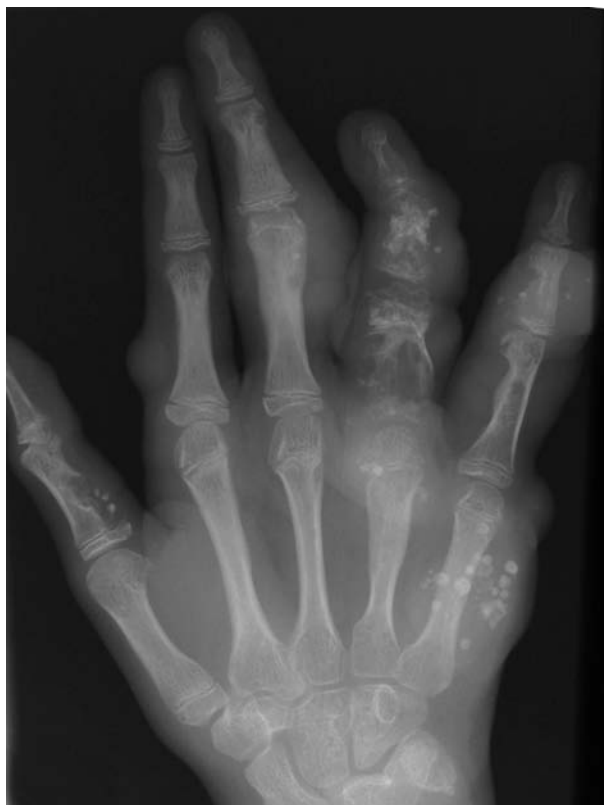

Enchondroma: scalloped erosion of the endosteal surface of the proximal phalanx with 'ground-glass' attenuation matrix due to the cartilage contents. A subtle pathological fracture is evident.

Osteochondroma

Characteristics

- Relatively common developmental anomaly.
- Overgrowth of cartilage at the margin of the physis (growth plate).
- Ossification then produces a bony protruberance with a cartilage cap.
- Commonest sites – distal femur, proximal tibia and iliac crest.
- Malignant transformation possible – look for tumour growth after physal fusion. Transformation to chondrosarcoma of 1% is quoted.
- Teenage/young adult.



Maffucci's syndrome: multiple enchondromata with multiple soft tissue haemangiomas. Note the numerous calcified soft tissue phleboliths.

Clinical features

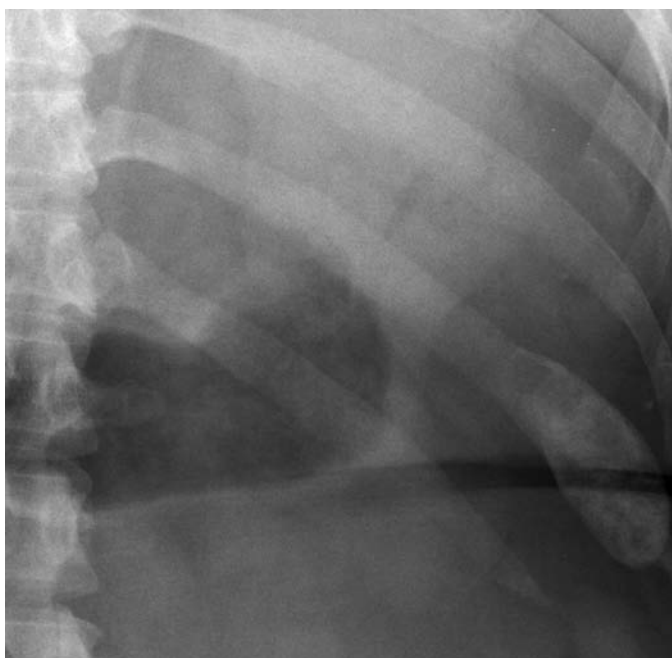
- Presents with lump or pain because of impingement of overlying soft tissues (e.g. bursa, nerve, skin).
- May be multiple – hereditary multiple exostoses (diaphyseal aclasis) – said to have higher rate of malignant transformation – 6%.

Radiological features

- Well-defined exostosis – smaller than clinical assessment because of cartilage tip.
- Growth away from the epiphysis, towards the diaphysis.
- Base of lesion is in continuity with the medullary cavity.
- Cartilage cap in larger lesions may undergo degeneration and calcify.

Management

- Reassurance.
- Observe.
- Excise if painful, neurological symptoms, recurrence from previous excision or continued growth after physal fusion.



Chondroma of the left 11th rib.

Tumours of bone – malignant (myeloma, metastases – separate sections)

Chondrosarcoma

Characteristics

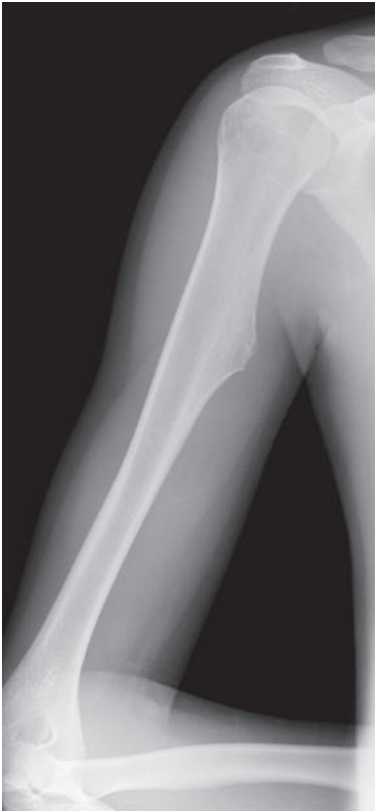- Primary malignant tumour of cartilage matrix producing cells.
- 17% primary bone tumours.
- M > F (2 : 1).
- Peak age 30–65.
- 30% pelvis, 20% femur.

Clinical features

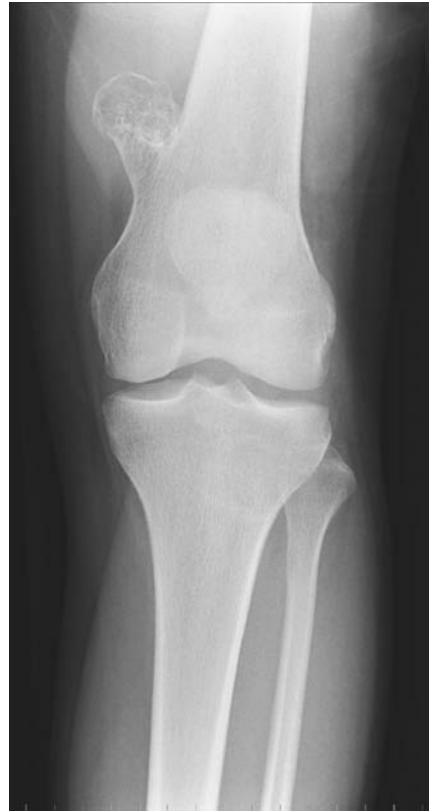- Presents with pain – ‘ache’ – or an expanding mass.
- Metastases not common, but late seeding to lung.
- Prognosis depends on grade:
 - Low grade up to 85% 5-year survival.
 - High grade as low as 15% 5-year survival.

Radiological features

- Variable radiographic appearance.
- Unusually large soft-tissue mass attached to bone.



Osteochondroma arising from the medial diaphysis of the right humerus.



Osteochondroma arising from the lateral aspect of the distal left femoral metaphysis.

- Flocculent/streaky chondroid calcification is characteristic (70%) usually centrally, but may have subperiosteal new bone formation.
- May be cystic with endosteal scalloping and cortical expansion.
- Bony destruction occurs late.

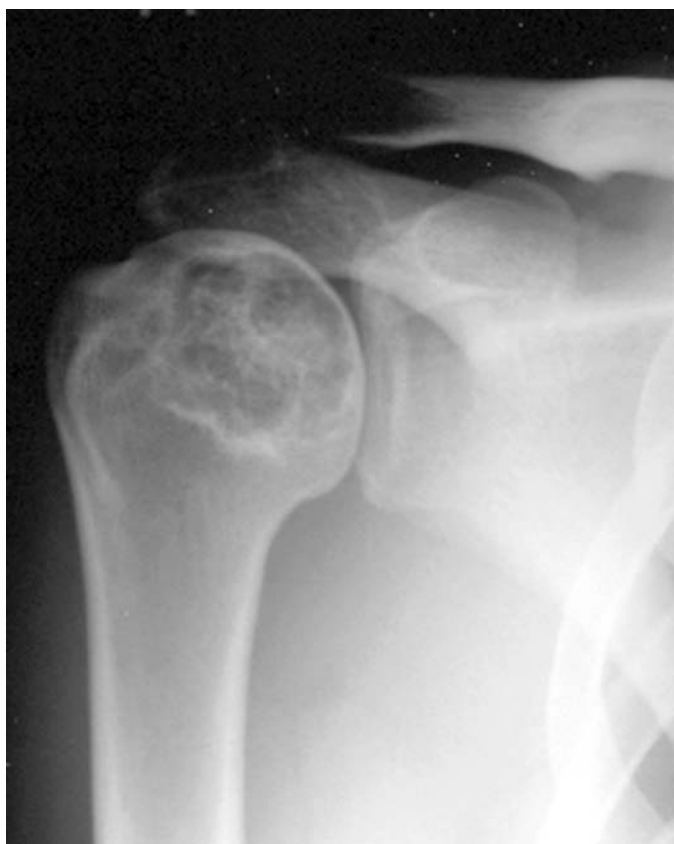Management

- Wide local excision.
- Radiotherapy for inoperable lesions.

Osteosarcoma

Characteristics

- Highly malignant bone-forming primary bone tumour.
- Parosteal osteosarcoma is a low-grade variant.
- Arises in the medullary canal and grows out and through the periosteum into surrounding soft tissues.



Chondrosarcoma of the right humeral head. Note the central chondroid calcification.

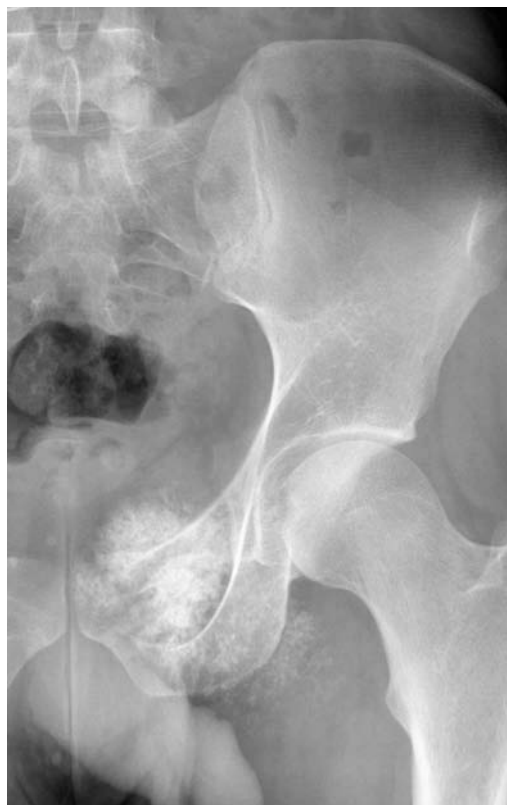- Most commonly affects long-bone metaphyses.
- Predominantly occurs in children, adolescents and young adults.

Clinical features

- Presents with pain – constant, worse at night, gradually increasing in severity.
- A palpable lump may be present.
- Fracture is rare.
- The abnormal area may be tender or normal on examination. A palpable mass is found late in the disease with surrounding inflammation.
- Raised ESR, CRP and alkaline phosphatase.

Radiological features

- Usually large bone lesion of >5–6 cm when first detected.
- Variable density – osteolytic and osteoblastic areas.

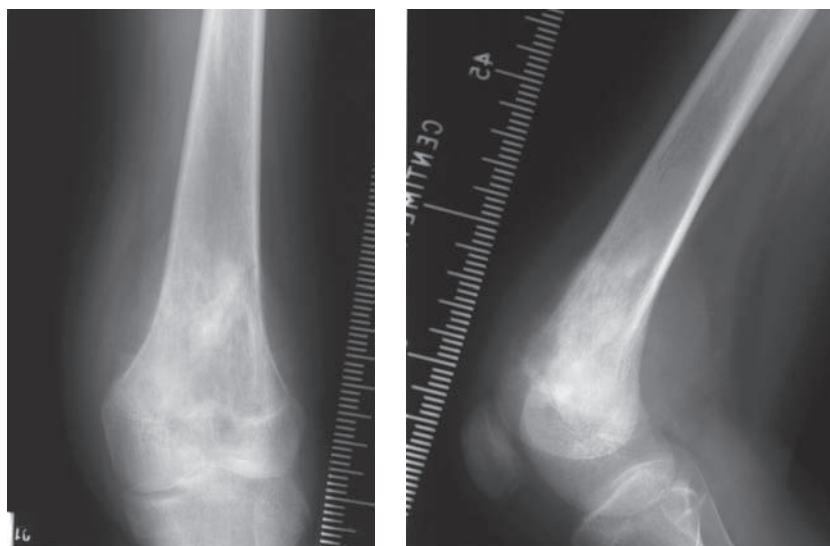


Chondrosarcoma of the left superior pubic ramus. Large soft-tissue mass containing prominent streaky chondroid calcification.

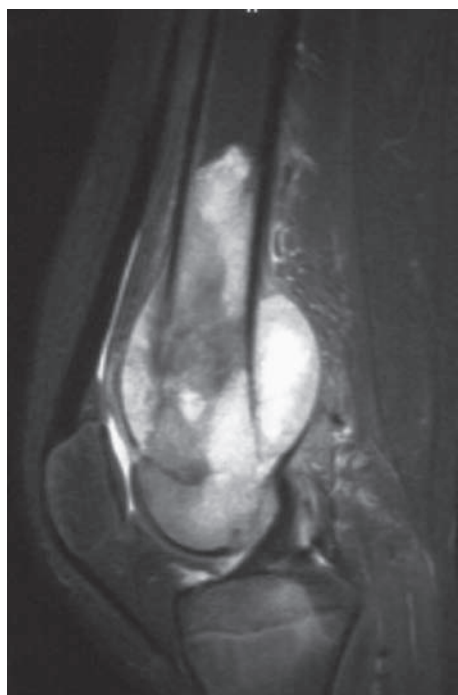
- Poorly defined margins; moth-eaten bone destruction + cortical disruption.
- Cortex often disrupted due to aggressive periosteal reaction with 'extra-osseous tumour' containing streaks of new bone in the soft tissue; so-called 'sunburst' sign.
- *Codman's triangle* – reactive new bone formation where tumour emerges from the cortex and grows into the soft tissue.
- Transphyseal spread before plate closure (75%–88%); physis does *not* act as a barrier to tumour spread.
- Spontaneous pneumothorax (due to subpleural metastases).

Management

- CT/MRI to delineate extent of tumour.
- Bone scan to identify skip lesions.
- CXR and pulmonary CT – 10% patients have pulmonary metastases at presentation.
- Biopsy and multi-disciplinary planning.
- Chemotherapy.



Osteosarcoma of the distal left femur (frontal and lateral views). Ill-defined sclerosis within the distal femoral metaphysis with aggressive spiculated periosteal reaction medially.



Osteosarcoma: sagittal STIR MRI. Large extra-osseous component seen extending, anteriorly and posteriorly, into the adjacent soft tissues. The extent of the marrow involvement and transphyseal spread are clearly delineated.

- Subsequent wide excision – consider amputation with skip lesions.
- Long-term survival after excision and chemotherapy approaching 60%.

Ewing's sarcoma

Characteristics

- Malignant, non-osteogenic primary bone tumour.
- Highly undifferentiated small cells in sheets associated with blood vessels.
- Incidence of 0.6–0.8/million and accounts for 10% of primary bone tumours. Peak incidence is second decade of life, rarely <5 or >30 years of age.
- There is a slight male preponderance (M : F = 1.6 : 1). Only 2% of Ewing's occur in the black population. Five-year survival has increased with multi-agent chemotherapy from 10% to >70% (Burgert *et al.*, 1990). Must differentiate from lymphoma, embryonal rhabdomyosarcoma, metastatic neuroblastoma, small-cell sarcoma, osteomyelitis and Langerhans' cell histiocytosis.
- Believed to be neural in origin.
- Most frequently found in the long bones (femur, commonly distal metaphysis) and pelvis. Any part of the bone may be affected.

Clinical features

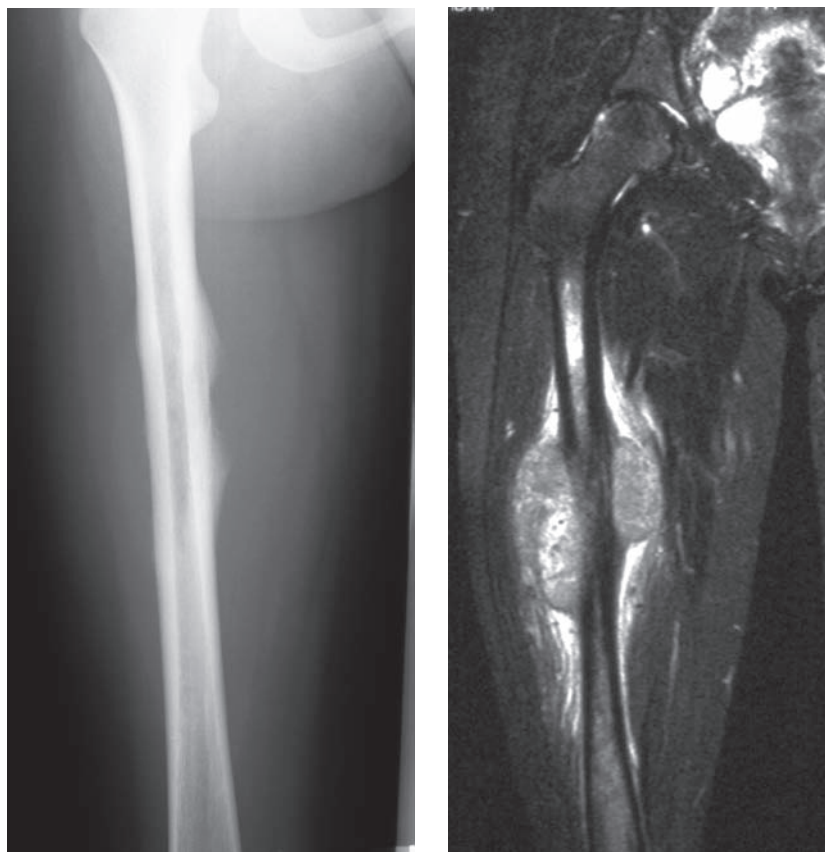
- Most patients complain of pain (90%) and swelling (70%).
- Patients are sometimes febrile (20%) and may fracture (10%).
- Spinal Ewing's are quite likely to have neurological deficit (50%).

Radiological features

- *Plain radiographs* – destructive, poorly demarcated lytic lesion in bone with an associated large soft-tissue mass.
- *Less commonly* – mixed density or sclerotic.
- *Lamellated periosteal reaction* – 'onion skin' appearance.
- 'Sun burst' and 'hair on end' appearances may be present.
- MRI demonstrates soft-tissue spread and bone-marrow involvement; MRI is repeated after chemotherapy to restage after tumour shrinkage.
- Metastatic disease is assessed by CXR, chest CT and bone scan.

Management

- Local and systemic imaging as above to stage the disease. Bone marrow biopsy away from the primary lesion to assess the spread into the bone marrow. Local biopsy (by definitive tumour surgeon) to provide histological confirmation of diagnosis.
- Preoperative chemotherapy and re-stage by local MRI.
- Surgical excision can then be contemplated for local control, usually in the form of 'en-bloc' wide excision, often combined with primary joint reconstruction (e.g. a distal femoral replacement/rotating hinge knee).



Ewing's sarcoma: large eccentric and destructive lytic lesion arising from the medial femoral diaphysis, with prominent periosteal reaction. Sagittal STIR MRI demonstrates a huge soft-tissue component and marrow involvement, both of which are not appreciated on the plain radiograph.

- Occasionally preoperative radiotherapy is used to shrink the tumour to facilitate *en bloc* excision, and radiotherapy is offered post-operatively if the excision margin is intra-lesional or marginal.
- Good prognostic signs are tumours of the extremities, tumours <10 cm (volume < 100 cm³), the absence of metastases at presentation and good initial response to neoadjuvant chemotherapy.

TRAUMA RADIOLOGY

SECTION



ATLS – Advanced Trauma Life Support

Characteristics

- Standardised team approach to the trauma patient.
- Prioritisation of diagnosis and treatment of injuries according to threat to life.
- Initiated in Nebraska, USA in 1978, following a plane crash.
- The pilot was an orthopaedic surgeon. His wife was killed and his children injured.
- He vowed to change the management of trauma when he saw the substandard care he and his family received at the primary-care facility.
- Worldwide courses are now run, which are compulsory for emergency physicians and trauma surgeons in many countries.
- ATLS identified a trimodal death distribution:
 - Immediate, e.g. major vessel avulsion.
 - Minutes to hours (“The Golden Hour”), e.g. obstructed airway, pneumothorax or haemorrhage.
 - Days to weeks, e.g. sepsis or multi-system failure.
- ATLS focuses on the second peak, but good care then impacts on the third peak which on recent data has been dramatically reduced.

Clinical features

- Primary survey – a swift and targeted evaluation with subsequent life-saving treatment:
 - A = Airway and C-spine.
 - B = Breathing.
 - C = Circulation.
 - D = Disability.
 - E = Exposure.
- Primary adjuncts:
 - Monitoring, e.g. ECG.
 - Catheters, e.g. urinary.
 - X-rays: AP pelvis, supine CXR, lateral C spine.
- Secondary survey:
 - Top-to-toe evaluation.

Radiological features

- *AP pelvis*.
 - Obtain pelvic views in multiple-trauma patients and in those with unexplained shock following trauma.
 - Assess the pelvic 'rings' for steps or asymmetry.
 - Compare like for like bearing in mind rotational differences.
- *CXR*.
 - Assess for aortic rupture (see below).
 - Assess for rib fractures/flail chest.
 - Assess for lung contusion/pneumothorax.
 - Assess for diaphragmatic rupture.
- *Lateral C spine* – examine the **ABCs** (see below).

Acetabular fractures

Characteristics

- Part of the innominate bone (formed from ilium, ischium and pubis) which forms the roof of the hip joint.
- The key factor is displacement (>1 mm), indicating loss of hip-joint congruity and subsequent risk of post-traumatic arthrosis.
- Classified by Letournel – (described the acetabulum as an inverted ‘Y’ with anterior and posterior columns) into *simple* and *complex* fracture patterns.
 - Anterior column = pelvic brim, anterior wall, superior pubic ramus and anterior iliac wing.
 - Posterior column = greater and lesser sciatic notch, posterior wall, ischial tuberosity, most of quadrilateral surface.
- *Simple fractures*:
 - Posterior-wall fractures.
 - Posterior-column fractures.
 - Anterior-wall fractures.
 - Anterior-column fractures.
 - Transverse fractures.
- *Complex fractures*:
 - Posterior-column and posterior-wall fractures.
 - Transverse and posterior wall.
 - T-shaped.
 - Anterior wall/column with hemi-transverse posterior fracture.
 - Both columns.

Clinical features

- Generally high-energy trauma, often following motor vehicle accident.
- Usually young patients.
- Associated hip dislocation relatively common. Look for short limb and rotational deformity.
- Posterior dislocation most common – leg is short and internally rotated.
- Distal neurovascular injury possible – particularly sciatic/obturator nerves.
- Pelvic/groin pain exacerbated by hip movement.

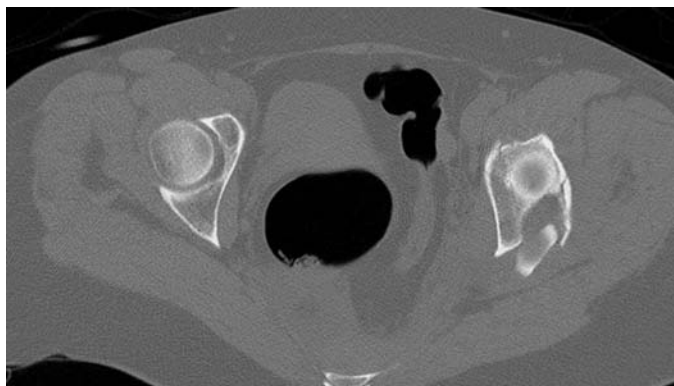Radiological features

- *AP pelvis* – identify 6 lines – *iliopectineal, ilioischial, tear-drop, roof, anterior rim, and posterior rim of the acetabulum*.
- *Judet views*. These are 45° oblique views to profile the anterior wall and posterior column (iliac oblique – taken with the iliac wing of fractured acetabulum perpendicular to the X-ray beam) and then anterior column and posterior wall (obturator oblique – the obturator foramen is perpendicular to the X-ray beam).

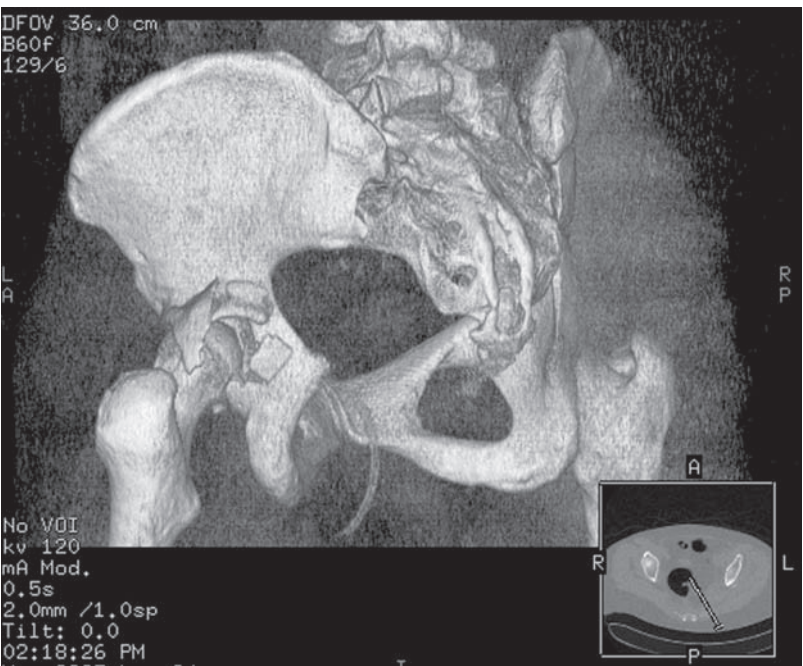
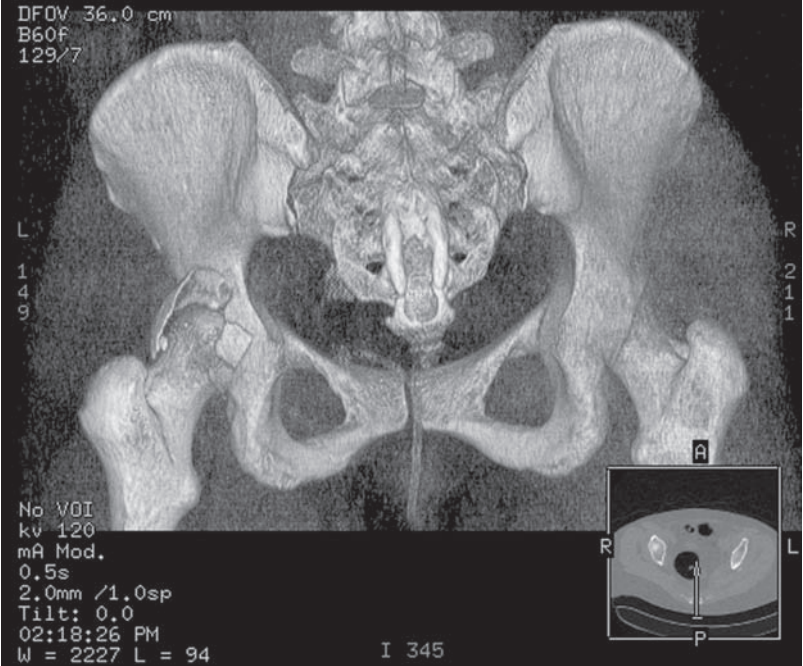
- *High resolution CT* – is particularly useful to identify posterior injuries, define fracture anatomy and plan surgical reconstructions.
- *3D CT reconstructions* – can be useful (particularly with digital subtraction of the femoral head) for visualisation of fracture planes and assess the degree of displacement. However, undisplaced components of a fracture may be missed.

Management

- Assess patient as a whole – ATLS principles.
- Reduce any associated dislocated femoral head:
 - Usually closed reduction under GA in theatre.
 - Check congruence/stability with image intensifier.
 - Look for intra-articular fragments.
- Skin/skeletal traction.
- Judet views (if not already available) and CT to assess need for reconstruction.
- Indications for ORIF or occasionally PRIF (percutaneous reduction internal fixation):
 - ≥ 2 mm displacement.
 - Posterior wall fractures with hip instability – 20%–65% posterior wall.
 - Loss of femoro-acetabular congruence.
- Indications for non-operative treatment:
 - Undisplaced fractures.
 - Majority of acetabulum intact – despite small area displacement.
 - Patient sepsis.
 - Technically un-reconstructable, e.g. multi-fragmentary, osteoporosis.
- If specialist pelvic surgeon not available – transfer patient when stable.



Left acetabular fracture: high-resolution axial CT demonstrating a fracture of the left acetabulum, involving the posterior wall and posterior column.



Volume-rendered 3D reconstruction confirms the complex nature of the left acetabular fracture and aids in surgical planning.

Aortic rupture

Characteristics

- 80%–90% of patients die before reaching hospital.
- Associated with deceleration injuries, such as a fall from a height or in road-traffic accidents over 40 mph.
- The aorta is usually disrupted distal to the origin of the left subclavian artery.

Clinical features

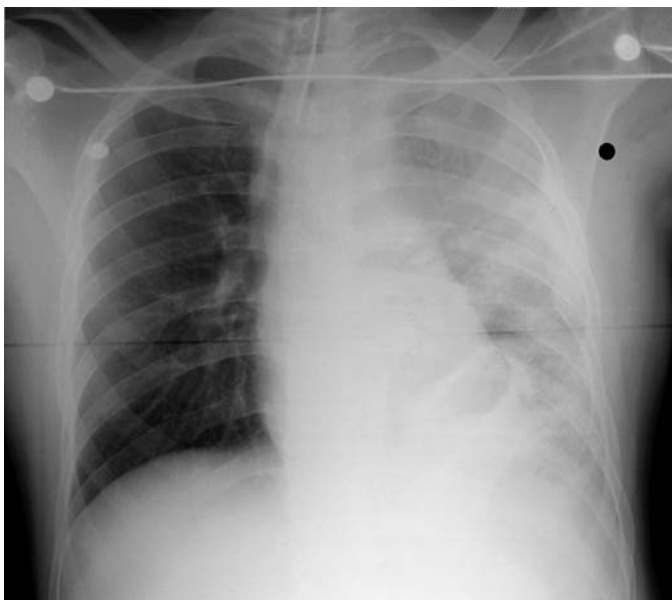
- An aortic rupture should be suspected from the mechanism of injury.
- Chest or inter-scapular pain will be present.
- Differential brachial blood pressures or different brachial and femoral pulse volume are suggestive.

Radiological features

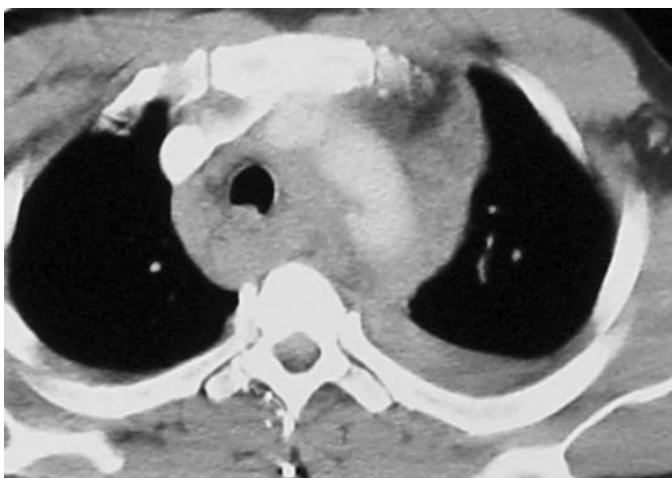
- *Chest radiograph.*
 - Widened mediastinum (greater than 8 cm on a supine AP chest radiograph).
 - Blurred aortic outline with loss of aortic knuckle.
 - Left apical pleural cap.
 - Left-sided haemothorax.
 - Depressed left/raised right main stem bronchus.
 - Tracheal displacement to the right.
 - Oesophageal NG tube displacement to the right.
- *CT thorax.*
 - Vessel wall disruption or extra-luminal blood seen in contiguity with the aorta is indicative of rupture.

Management

- Intravenous access.
- Judicious fluid replacement.
- Adequate analgesia.
- Avoid hypertension (excess fluid replacement/poor pain control, etc.).
- Urgent surgical/cardiothoracic involvement with a view to thoracotomy and repair.



Traumatic aortic rupture: tracheal deviation to the right, depressed left main stem bronchus, left haemothorax, blurring of the outline of the aortic arch and a left pleural apical cap. Rib fractures and a traumatic left diaphragmatic hernia are also noted.



Aortic rupture: contrast enhanced CT (different patient). Slit-like rent in the wall of the aortic arch with an associated haemomediastinum and left haemothorax.

Cervical spine injury

Characteristics

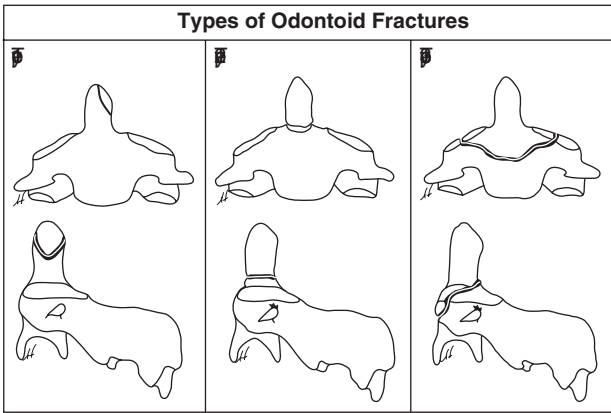
- Majority are seen secondary to road-traffic accidents. Falls from height and sporting accidents make up the second largest category.
- Most commonly seen in young men. A relative increase in incidence is seen in the elderly as arthritis and degenerative changes increase susceptibility.
- *Classified according to mechanism of trauma:*

Flexion injuries

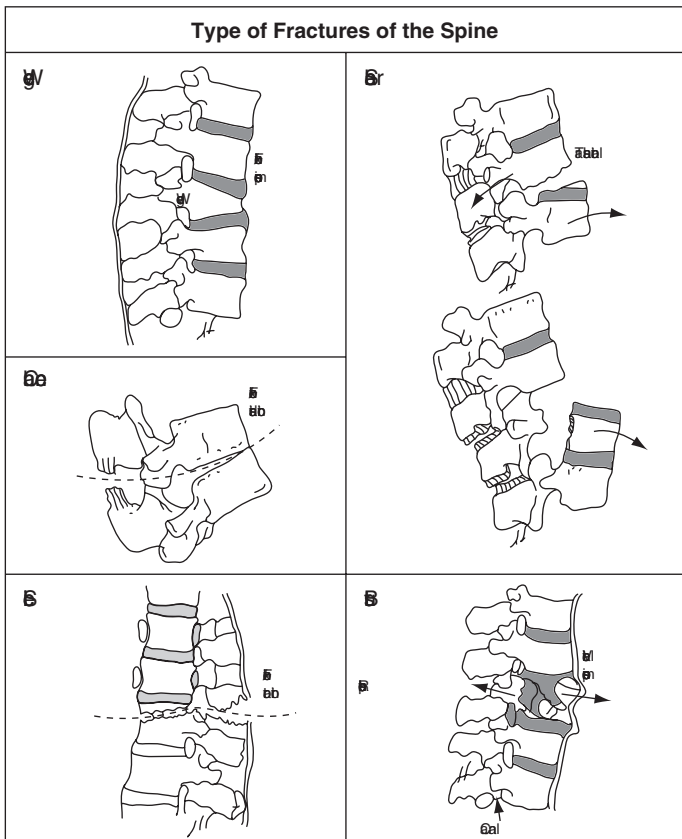
- Simple wedge fracture.*
Compression fracture of the *antero-superior* aspect of the vertebral body.
Generally *stable* unless associated with posterior ligamentous disruption.
- Tear-drop fracture.*
Fracture through the *antero-inferior* aspect of the vertebral body, often with anterior displacement of the fragment. Commonly associated with ligamentous disruption and hence the fracture is *unstable*. This differs from an extension tear-drop fracture in that the anterior height of the vertebral body is usually reduced, in keeping with the mechanism of injury.
- Clay shovellers' fracture.*
Spinous process fracture following direct trauma or ligamentous avulsion – *stable* injury.
- Atlanto-occipital and atlanto-axial dislocation.*
Highly unstable. May be associated with an odontoid fracture.
- Bilateral facet dislocation.*
Requires a large degree of force and is *highly unstable*. Best seen on a lateral view. The vertebral body above displaces anteriorly by at least 50% of the AP diameter of the vertebral body. The facets often appear 'locked'.
- Odontoid fracture* – subdivided according to site by Delonso and Anderson:
 - *Type 1* occurs at the tip and is *stable*.
 - *Type 2* involves the junction of the dens (=odontoid) and vertebral body. This is *unstable*.
 - *Type 3* occurs through the superior aspect of C2 at the base of the odontoid. This may be *unstable* if there is significant (>5 mm) fragment separation.
- Uncinate process fracture.*
Occurs secondary to lateral flexion. *Stable* injury.

Rotational injuries

- Unilateral facet dislocation.*
Usually secondary to a flexion/rotation injury. Superior facet dislocates anteriorly over the inferior facet. Considered a *stable* injury unless it occurs at the C1/C2 level.



Classification of odontoid peg fractures. From: *Sports Medicines: Problems and Practical Management* (Eds E. Sherry & D. Bokor); Greenwich Medical Media, 1997: page 117.



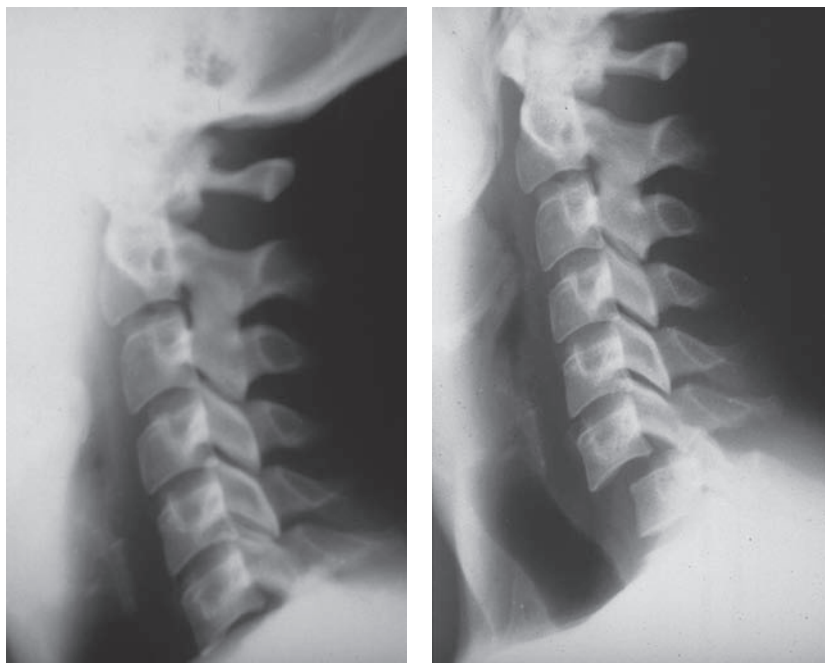
Types of fracture of the spine. From: *Sports Medicines: Problems and Practical Management* (Eds E. Sherry & D. Bokor); Greenwich Medical Media, 1997: page 120.

Extension injuries

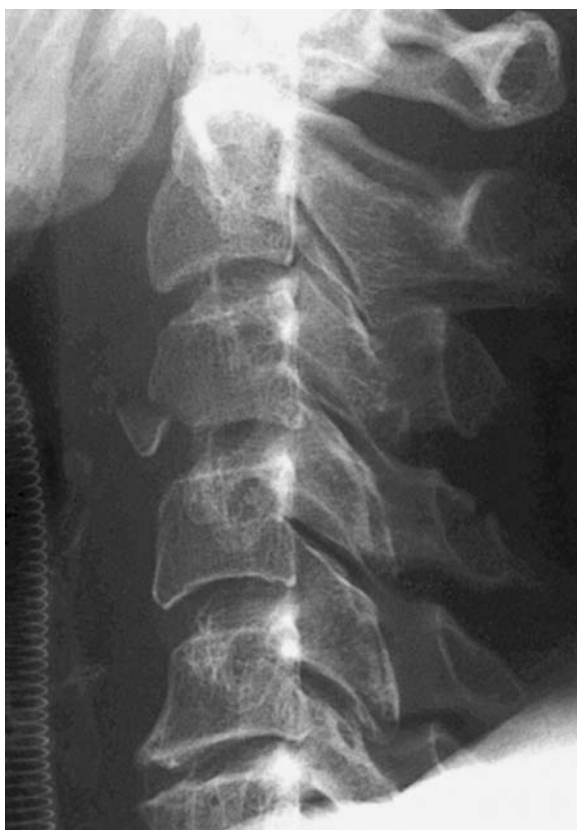- (a) *Fracture of posterior arch of the atlas.*
Occurs secondary to compressive force between axis and occiput.
- (b) *Tear drop fracture.*
The anterior longitudinal ligament avulses the *antero-inferior* corner of the vertebral body. Common at C2 and C5–C7. Vertebral body height preserved. This injury is *unstable in extension*.
- (c) *Hangman's fracture.*
Bilateral fracture through the pedicles of C2. A degree of subluxation of C2 on C3 occurs. Common in road-traffic accidents – an *unstable* injury. However, most fatal hangings result from a hyoid fracture and asphyxiation.

Vertical compression injuries

- (a) *Jefferson fracture.*
Occipital condyles force lateral masses of C1 laterally leading to fractures of the anterior and posterior arches with associated transverse ligament rupture – an *unstable* injury.
- (b) *Burst fracture.*
Intervertebral disc is driven into the vertebral body below. Fracture fragments may impinge on the cord and thus *should be thought of as unstable* even though the fracture itself is stable.



This demonstrates the importance of visualising the whole cervical spine down to the cervico-thoracic junction. Bilateral locked facets at C6/C7.



A tear-drop fracture at C3.

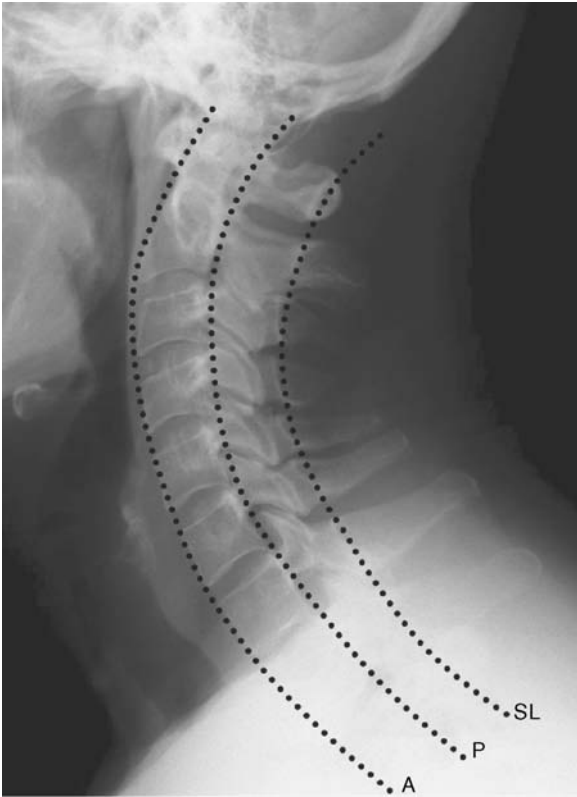Clinical features

- *All* patients with documented, or suspected, trauma above the level of the clavicles should be considered to have a cervical spine injury until proven otherwise. These patients should have cervical spine immobilisation until cleared both radiologically and clinically.
- Obtain an accurate history if possible prior to examination. The mechanism of injury will often reveal the suspected bony abnormality.
- Examine from 'top-to-toe' in a systematic way looking for signs of trauma. Speak to the patient, both to reassure and to localise a potential injury, e.g. painful hands can represent an unstable injury at C6/7, but in the presence of a fully conscious and cooperative patient, a C6/7 cervical spine injury will be painful and tender to examination.
- The cervical spine can be examined while immobilised. Palpate the neck for muscle spasm, mid-line bony tenderness, palpable steps and crepitus.
- Assess the neurological system carefully and document time and findings.

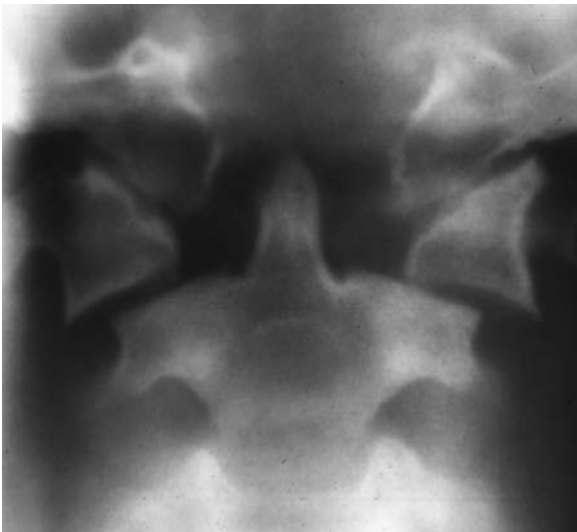- A *complete* spinal-cord lesion is defined as ‘complete loss of motor and sensory function below the level of a spinal-cord injury’. If symptoms persist greater than 24 hours, the chances of recovery are slim. **Spinal shock can mimic the symptoms although this usually recovers in less than 24 hours.**
- *Incomplete* lesions can generally be grouped into three syndromes – central-cord lesions, Brown-Sequard syndrome and anterior-cord lesions.

Radiological features

- A cervical spine injury is unlikely in an alert patient (i.e. not under the influence of alcohol or drugs) without neck pain, bony tenderness, focal neurological defect or a painful distracting injury.
- Obtain lateral, AP and an open-mouth peg view if a cervical spine injury is suspected.
- **Lateral view** – examine the **ABCs**
 - A. *Adequacy and alignment.* Visualise from base of skull to the C7/T1 junction. In-line arm traction, during the cross table lateral, or a swimmer’s views can be helpful in visualising C7/T1. Look for the normal smooth curve of the anterior vertebral, posterior vertebral and spino-laminar lines (see diagram). In a child, pseudo-subluxation of C2 on C3 can cause confusion. In these cases, examine the spino-laminar line from C1 to C3. If the bases of these spinous processes lie greater than 2 mm from this line an injury should be suspected. Correlate with soft-tissue findings (see below). The distance between the anterior arch of C1 and the odontoid peg should be less than 3 mm in an adult and 5 mm in a child.
 - B. *Bone.* Assess for normal bony outline and density. An increase in density may indicate a compression fracture.
 - C. *Cartilage.* The intervertebral spaces should be uniform. Widening of these or the interspinous distance may indicate an unstable dislocation. An increase in interspinous distance of greater than 50% suggests ligamentous disruption. Muscular spasm can make interpretation difficult.
 - S. *Soft tissues.* Retro-pharyngeal soft-tissue swelling may be the only sign of a significant injury; swelling takes time to build up and initial films if taken early may be misleading. Normal measurements are less than 7 mm C2–C4 (half a vertebral body at this level) and less than 22 mm below C5 (a vertebral body width). Air within the soft tissues suggests rupture of oesophagus or trachea/bronchus. Bulging of the pre-vertebral fat stripe is an early sign.
- *AP view.* The tips of the spinous process should lie in a straight line in the mid-line. Bifid spinous processes can make interpretation difficult. Again, assess the interspinous distances for ligamentous rupture.
- *Open-mouth view.* The distance between the odontoid and the lateral masses of C1 should be equal. Inequality may be due to head rotation. In such cases the lateral margins should remain aligned. Fractures may be mimicked by congenital anomalies and non-fusion in children.



Always assess the anterior vertebral (A), posterior vertebral (P) and spinolaminar (SL) lines.



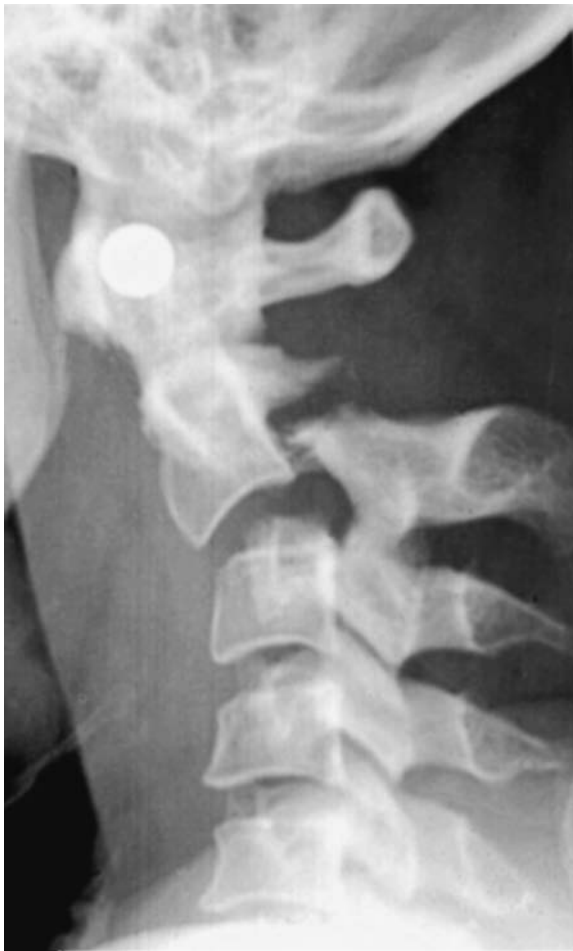A Jefferson's fracture.

Overlying soft tissues, the occiput and dentition may also mimic a fracture (attempt to trace the suspect line beyond the bony cortical margins).

- *Other views.* Oblique and flexion/extension views are useful. Flexion–extension view must be under active patient control so that pain and spasm will prevent significant movement in an unstable ligamentous injury.
 - Remember if a fracture is found, there are likely to be other abnormalities!
- *Spiral CT.* Used to further evaluate abnormalities and when plain films are inadequate. Technically superior to plain films in assessing fractures, soft tissues and the spinal canal.
- *MRI.* Used to assess soft tissues, ligaments and the spinal cord.

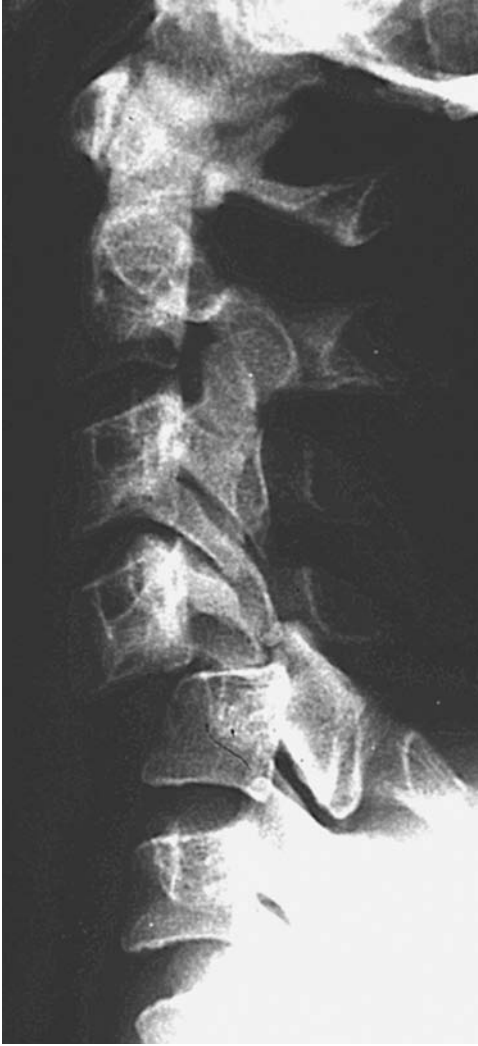Management

- ABCs, ATLS assessment and appropriate treatment.
- Continue triple in-line immobilisation when a C-spine injury documented.
- CT scans further assess stability of a potentially unstable fracture, confirm the diagnosis of fracture where uncertainty exists and delineate any retropulsed fragments in cases of neurological abnormality.
- If any abnormal neurology – obtain MRI – if there is persistent nerve root/cord compression, then this may be amenable to surgical decompression and stabilisation.
- *Aims of treatment.*
 - Prevent new or further neurological insult.
 - Decompress potentially reversible neurological deficits.
 - Reduce spinal deformity to normal alignment.
 - Hold the reduction over a period approximately 6–12 weeks to allow union.
 - Rehabilitate.
- Most fractures do not require internal stabilisation.
- When surgery is necessary, this is usually instrumented fusion to ‘bridge’ the unstable segments. This is the domain of specialist spinal surgeons from either a neurosurgical or orthopaedic background.
- Stable fractures:
 - Firm collar, e.g. Philadelphia C spine-brace.
 - SOMI (sterno-occipito-mandibular immobilisation) braces (also called ‘four-poster brace’) provides more reproducible immobilisation, but has poorer patient compliance.
- Unstable fractures:
 - Skull tongs and traction.
 - Halo vest immobilisation.
 - Fusion.
- Repeat CT to assess bony union at approximately 6 weeks initially.



A hangman's fracture.

- In unstable fractures consider flexion–extension lateral C spine views once bony union is documented to check ligamentous integrity prior to mobilisation.
- In cases of neurological injury consult local spinal-injuries centre early.



Bilateral locked facets at C4/5.

Characteristics

- Occurs when there is loss of continuity of a segment of chest wall with the rest of the thoracic cage.
- Usually traumatic with two or more ribs fractured in two or more places.
- Results in disruption of normal chest wall movements, and indeed paradoxical movement may be seen.
- Always consider underlying lung injury (pulmonary contusion).
- The combination of pain, decreased or paradoxical chest wall movements and underlying lung contusion are likely to contribute to the patient's hypoxia.

Clinical features

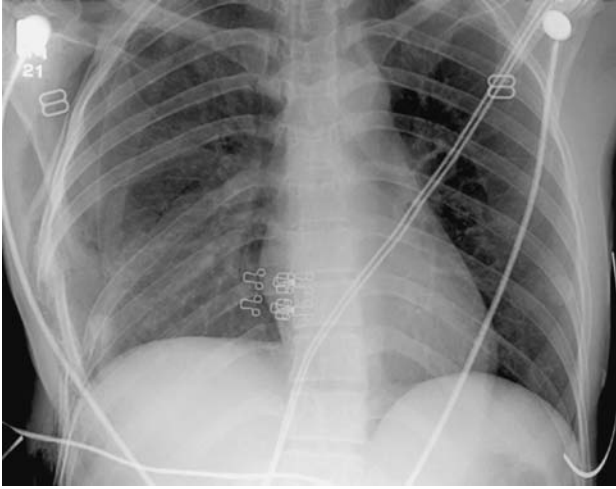
- Dyspnoea.
- Tachycardia.
- Cyanosis.
- Tachypnoea.
- Hypotension.
- Chest wall bruising \pm palpable abnormal movement or rib crepitus.
- The degree of hypoxia often depends on the severity of the underlying pulmonary contusion.

Radiological features

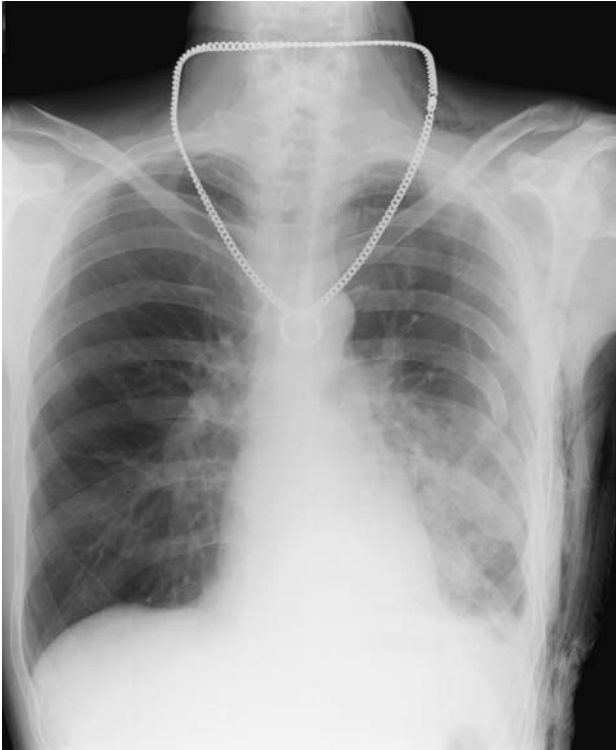- Multiple rib fractures.
- Costochondral separation may not be evident.
- Air-space shadowing may be seen with pulmonary contusion (often absent on initial films).

Management

- Initial management includes securing the airway and maximising oxygenation.
- In the absence of systemic hypotension judicious fluid replacement is required as the injured lung is susceptible to both under-resuscitation and fluid overload.
- Definitive treatment includes judicious fluid therapy, oxygenation and adequate analgesia to optimise ventilation/lung re-expansion.



Right flail chest.



Left flail chest.

Characteristics

- Accumulation of blood within the pleural space following blunt or penetrating trauma.
- Commonly associated with a pneumothorax and other extrathoracic injuries.
- Haemorrhage usually occurs from the lung parenchyma, and is often self limiting, rather than from a specific vessel injury. Intercostal and internal mammary vessels are more commonly injured than the hilar or great vessels.

Clinical features

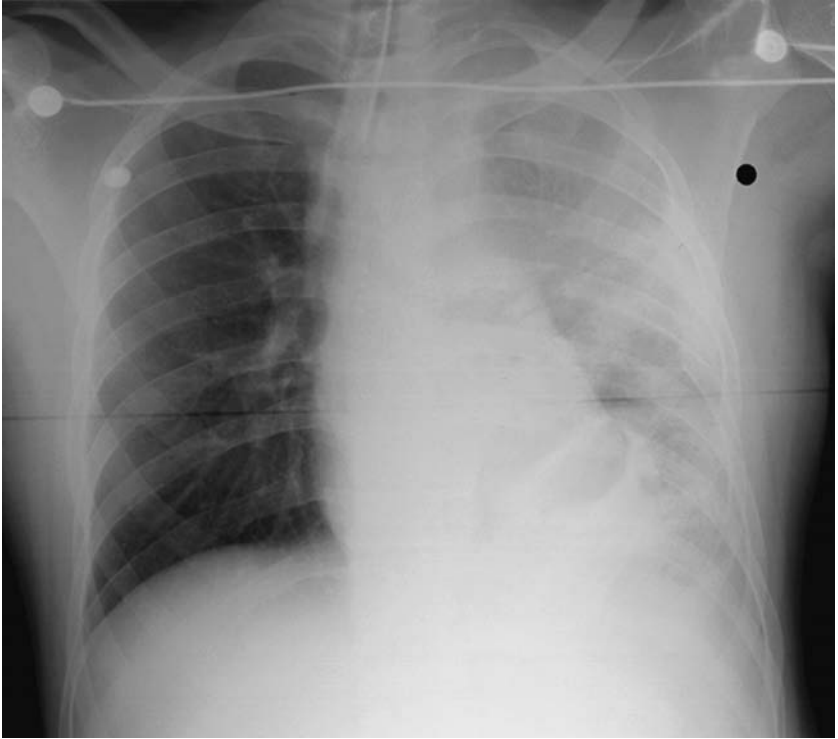
- Depends mainly on the amount of blood lost.
- Varying degrees of hypovolaemic shock.
- Breath sounds may be reduced or absent and/or dull to percussion.

Radiological features

- Erect chest radiograph is more sensitive than a supine film:
 - Blunting of the costophrenic angles – seen with approximately 250 ml of blood.
 - General increased opacification of the hemithorax is seen on a supine film.

Management

- Definitive management involves the placement of a large-bore tube thoracostomy. This allows both re-expansion of lung as well as estimation of initial and ongoing blood loss. Airway control and circulatory volume support are essential alongside definitive treatment.
- Initial drainage of 1500 ml or greater than 200 ml/hr are likely to require thoracotomy. Discuss with thoracic team and be guided by the patient's physiological status.
- ABCs with i.v. access prior to tube thoracostomy.



The opacification of the left hemithorax is secondary to a haemothorax. This patient has a traumatic transection of the aorta (see aortic rupture).

Characteristics

- A fracture which communicates with the outside environment.
- Originally termed 'compound' fractures.
- The severity of the injury is related to the energy imparted at the time of trauma.
- An assessment of the severity can be made by considering soft-tissue damage, fracture comminution/bone loss/periosteal stripping, level of contamination and vascular status. This is the basis of the *Gustillo and Anderson classification* – which is an intra-operative grading system:
 - I – small clean wound (<1 cm), no significant periosteal stripping or muscle damage.
 - II – larger wound but no significant periosteal stripping or muscle damage.
 - III – larger wound but with significant soft-tissue 'sleeve' injury. Farmyard contamination or gunshot injury with an open fracture raises the classification to III irrespective of wound/soft-tissue sleeve. Sub-divided as:
 - **A** Adequate soft-tissue sleeve coverage of the bone.
 - **B** Tissue transfer needed to cover the exposed **B**one.
 - **C** Open fractures with associated vascular injury (**C**irculation!) requiring repair.

Clinical features

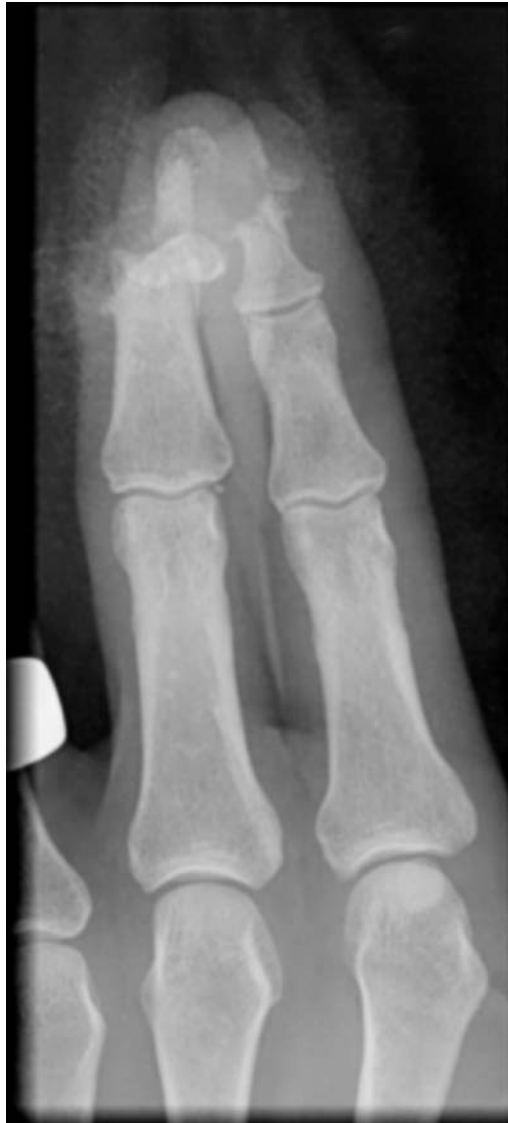- Commonly seen as part of a poly-trauma case with multiple injuries.
- Skin breakage in the presence of an underlying fracture = open injury.
- Pain, deformity, swelling – as any fracture. The deformity may be more pronounced with greater soft-tissue damage allowing more movement.

Radiological features

- AP/lateral X-rays to define the fracture with careful attention to the full extent of the injured bone, adjacent joints and often adjacent bones.
- In complex injuries that would benefit from further imaging prior to definitive treatment, this can be performed (e.g. CT scan) after the initial debridement and perhaps external fixation to temporarily stabilise the fracture.

Management

- ABCs.
- Assess neurovascular status.



Open fractures of the terminal phalanges. There is partial amputation of the terminal phalanges of the middle and index fingers, with associated soft-tissue loss.

- Assess wound ONCE, photograph and cover with –
 - Antiseptic dressing and immobilise.
- Antibiotics – broad-spectrum cephalosporin ± gentamicin in grade-III injury ± metronidazole with organic contamination – for 48 hours post-operatively.
- Analgesia.
- Arrange operating personnel for wound debridement.

- Temporary (soft-tissue protecting) external fixation vs. definitive early treatment with ORIF/intramedullary nail or external frame, varies with differing fracture personalities (patient, surgical, local unit and fracture factors).
- Delayed primary closure or reconstruction with tissue transfer at 48–72 hours.



Pelvic fracture

Characteristics

- Usually secondary to massive force such as a road-traffic accident or fall from a height.
- May be associated with vascular, soft-tissue and visceral injuries.
- If the ring is broken in two places the fracture is likely to be unstable – don't forget the sacroiliac joint as a site of disruption.
- Isolated ring fractures tend to be stable, e.g. an isolated pubic ramus fracture.

Tile classification –

- **A** – *stable* – Not involving the pelvic ring (e.g. avulsion fractures) or minimally displaced involving the pelvic ring (pubic rami fractures).
- **B** – *vertically stable, rotationally unstable* – AP compression (open book) and lateral compression (e.g. rami fracture with associated crushing injury of the sacroiliac joint).
- **C** – *unstable* – Disruption of the pelvic ring at two or more levels (e.g. bilateral rami fractures or pubic symphysis disruption).

Clinical features

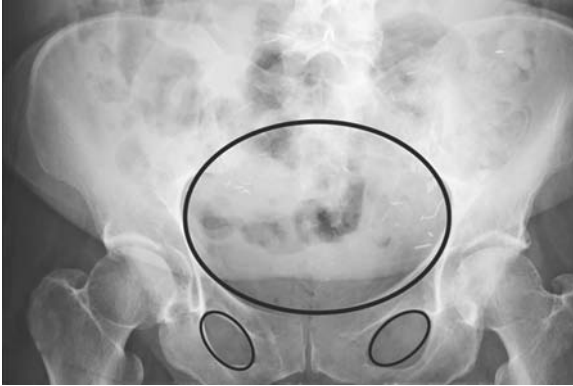- Suspect from history.
- Haemorrhagic shock is commonly seen due to vascular nature of the pelvic bones, closely related large vessels and large associated muscle groups.
- Shock is often compounded by haemorrhage from associated injuries in the thorax, abdomen and extremities.
- Beware urogenital and rectal disruption – look for perineal bruising, high or impalpable prostate and blood at the urethral meatus.
- *Gentle* pelvic testing may reveal instability. Avoid repeated examination.
- In the elderly, they may present similarly to suspected femoral neck fracture.

Radiological features

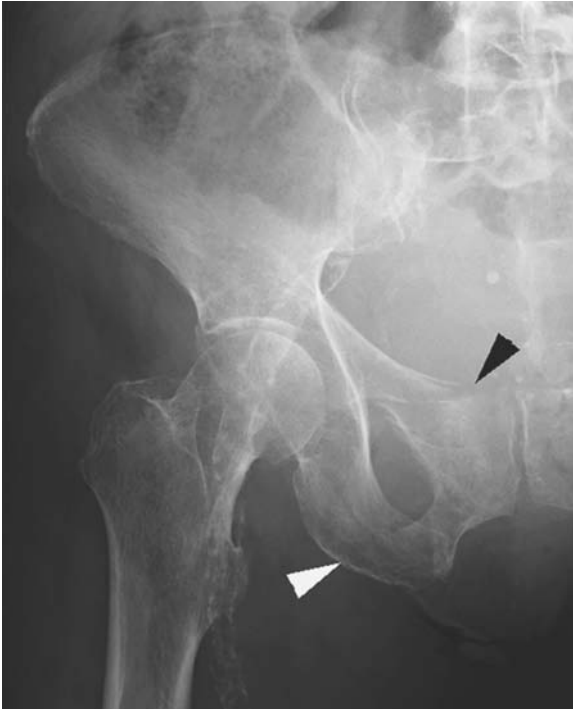- Obtain pelvic views in multiple trauma patients and with unexplained shock following trauma.
- Assess the pelvic 'rings' for steps or asymmetry.
- Compare like for like, bearing in mind rotational differences.
- Always closely examine the pubic rami and acetabulae in the elderly patient with a suspected neck-of-femur fracture.
- CT is a very useful modality to assess severity, reveal associated injuries and assist in the planning of surgery.

Management

- ABCs.
- Simple pubic rami fractures can often be discharged with analgesia following assessment of their home situation.

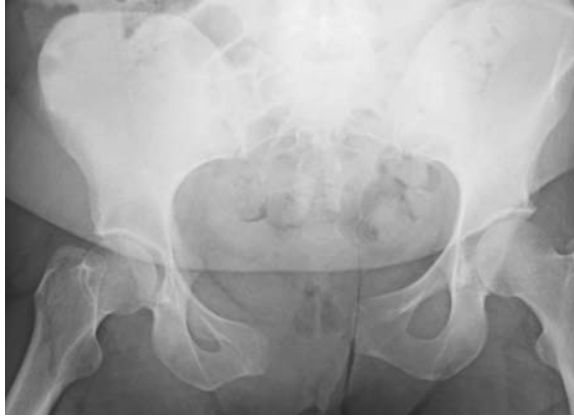

Remember to assess the pelvic 'rings' for steps and asymmetry.

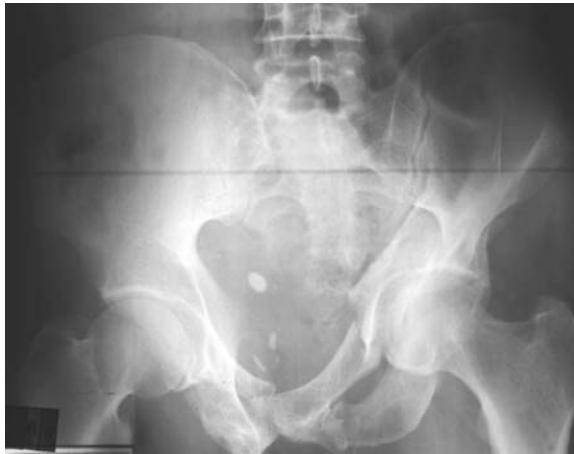

Superior and inferior pubic rami fractures.

- Unstable fractures require adequate fluid resuscitation and early fixation. External fixation within the A&E department has been employed, but the procedure is not always necessary and is far easier performed in the operating room.
- Emergency management of the unstable pelvis:
 - Internally rotate limbs – bind knees together.



Symphyseal diastasis.



Pelvic fracture following a road traffic accident.

- Patient draw sheets can be used to tie around the pelvis – cable ties useful.
- Commercially available binders to compress pelvis.
- Always consider other potential injuries such a urethral or rectal disruption.
- Discuss definitive management early with regional pelvic service.
- ORIF (and sometimes percutaneous fixation) provide good long-term outcome in displaced pelvic fractures.

Peri-physeal injury

Characteristics

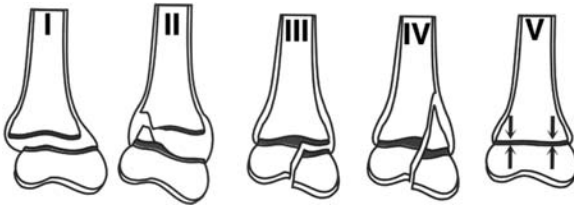
- Injury in close association with the physis (epiphyseal plate or growth plate).
- Classified by Salter–Harris.

Clinical features

- Immature skeleton.
- History of trauma.
- Tender, swollen extremity with reduced range of joint movement.

Radiological features

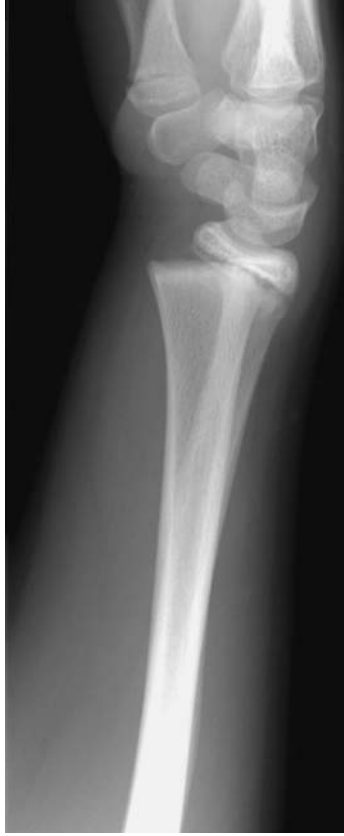- I Transverse through physis.
- II Through physis but with a metaphyseal fragment.
- III Through physis and epiphysis and therefore intra-articular.
- IV Through epiphysis, across physis and through metaphysis (II and III).
- V Physeal crush injury.



Salter–Harris Classification:

Management

- If clinical deformity or significant radiological displacement, likely to need reduction under anesthesia and POP.
- For minor angulation, POP alone.
- The majority of these will remodel if left alone, as long as sufficient residual growth in the child.
- In type V, watch for growth arrest due to physeal compression – may need completion epiphysiodesis, to fully close the physis and prevent angulated growth deformity.



Salter–Harris type II epiphyseal injury of the distal radius.

Characteristics

- Accumulation of air within the pleural cavity.
- A common complication of chest trauma (15% to 40%).
- Divided into three categories:
 - I. *Simple* – no communication with the atmosphere or mediastinum. No midline shift.
 - II. *Communicating* – associated with chest wall defect.
 - III. *Tension* – progressive accumulation of air under pressure within the pleural cavity. Leads to mediastinal shift with compression of the contra-lateral lung and great vessels.

Clinical features

- Chest pain and shortness of breath are common.
- Variable spectrum ranging from acutely unwell, with cyanosis and tachypnoea, to relatively healthy.
- Signs and symptoms not necessarily well correlated with degree of collapse.
 - Signs of a tension pneumothorax include:
 - Tachycardia.
 - Jugulo-venous distension.
 - Absent breaths sounds.
 - Hyper-resonance to percussion.
 - Tracheal and cardiac impulse displacement away from the affected side.
 - The patient may be acutely unwell with signs of cardio-respiratory distress.

Radiological features

Simple – visceral pleural edge visible. Loss of volume on the affected side (e.g raised hemi-diaphragm). A small pneumothorax may not be visualised on a standard inspiratory film. An expiratory film may be of benefit.

Tension – **This is a clinical not radiological diagnosis!** Associated mediastinal shift to the opposite side is seen.

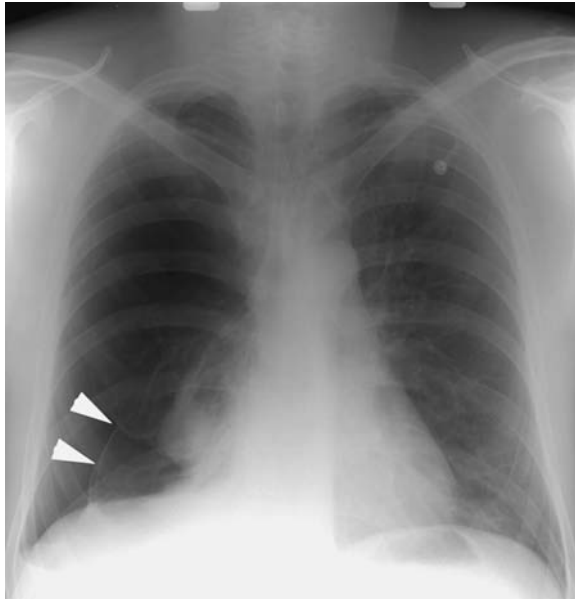Management

Simple – Depends on size and clinical picture.

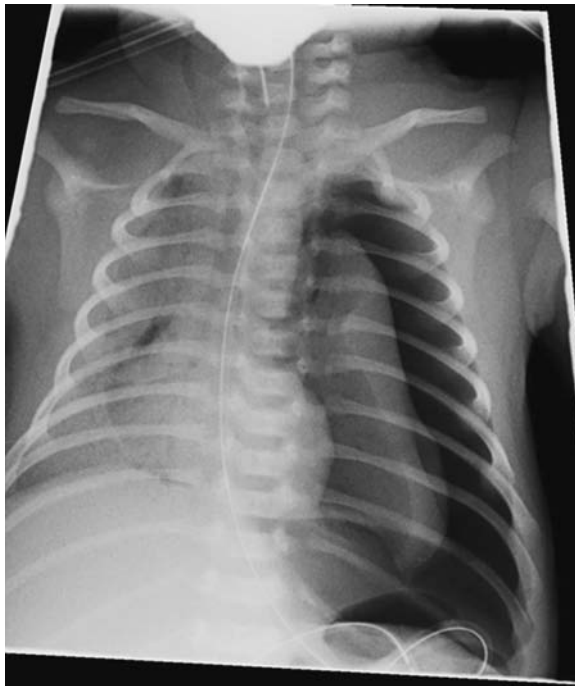- (i) Conservative treatment with follow up chest radiograph.
- (ii) Aspiration using a three-way tap may be adequate.
- (iii) Definitive management – tube thoracostomy.

Tension

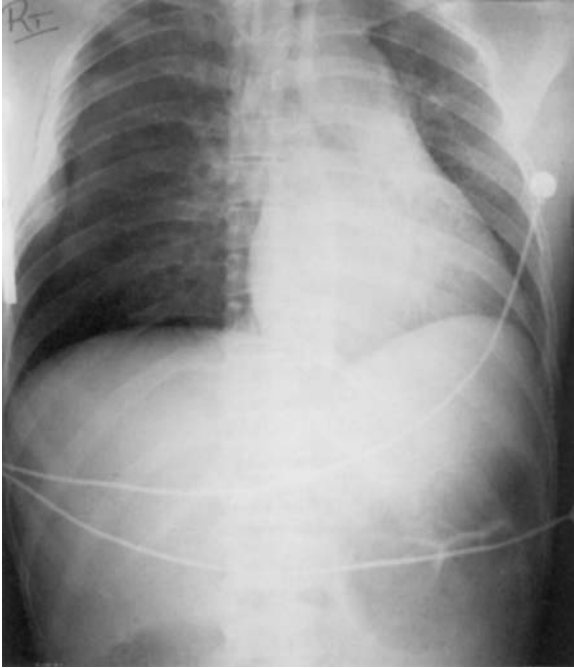
- (iv) A needle thoracostomy with a 14/16 g cannula in the second intercostal space (mid-clavicular line).



Simple pneumothorax: the edge of the right lung is clearly seen (arrows) devoid of peripheral lung markings. No mediastinal shift occurs.



Iatrogenic tension pneumothorax: this is secondary to the high intrathoracic pressures generated during ventilation resulting in rupture of a pleural bleb. There is progressive mediastinal shift to the right.



Traumatic tension pneumothorax: right-sided rib fractures and pneumothorax with mediastinal shift to the left.

Rib/sternal fracture

Characteristics

- Usually following direct trauma. May be pathological.
- Suspect with localised pain and tenderness which may be aggravated by deep inspiration or coughing.
- Consider associated injuries:
 - Clavicle/first or second rib fractures suggest a significant force of injury – often associated with great vessel, tracheo-bronchial or spinal injury.
 - Sterno-clavicular dislocation – posterior (rarer) associated with increased risk of major vessel damage.
 - Sternal injuries may be associated with myocardial contusion.
 - With lower-rib fractures, abdominal visceral injury such as liver, spleen or kidney may occur.

Clinical features

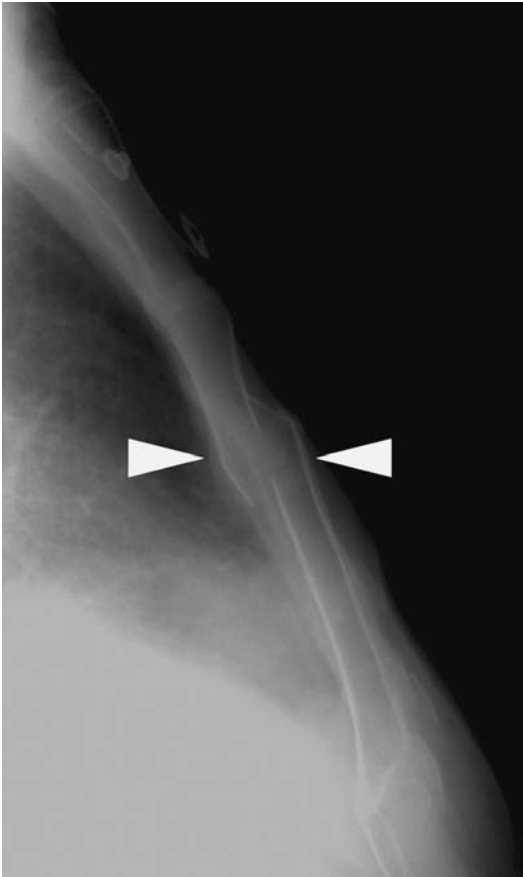
- Pain with limitation of inspiration.
- Often related to complications from any associated injury, e.g. cardiac arrhythmias or splenic rupture.

Radiological features

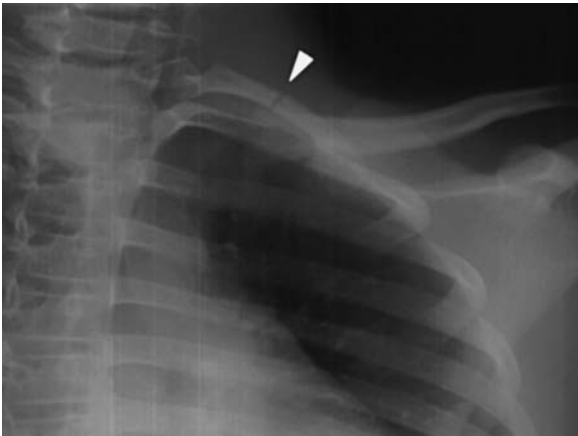- A chest radiograph/lateral sternal view are performed to assess for both complications and to identify any underlying fracture.
- Signs of complications – pneumothorax, haemothorax, pulmonary contusion, etc.

Management

- Simple rib or sternal fractures with a normal ECG and chest radiograph – the patient can usually be discharged with respiratory advice and good analgesia.
- Non-steroidal analgesia in combination with others is best unless contraindicated.
- Cardiac monitoring for suspected myocardial contusion.
- Surgical assessment/intervention for intra-abdominal visceral injury.



Sternal fracture.



Fracture of the left first rib. This injury requires significant force and is associated with an increased incidence of neurovascular injury, particularly the subclavian vein.

Skull fracture

Characteristics

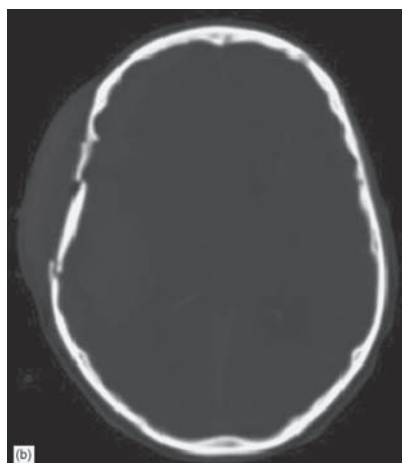
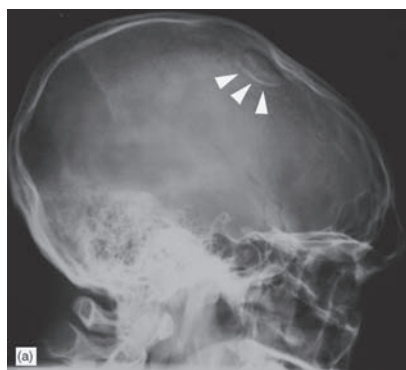- Caused by direct impact to the skull.
- Marker for underlying brain injury as this requires a substantial force.
- Classified as *linear*, *depressed* or *basal*.
- Type depends on amount of force and the ratio of force to the impact area.
- Clinically difficult to detect. If detectable there is likely to be underlying brain injury.
- Increased significance if open, communicate with an air sinus, are depressed or cross an artery or major dural sinus.
- Beware non-accidental injury. Commonest cause of skull fracture in an infant.

Clinical features

- *Linear*
 - Often no associated underlying brain injury and are thus relatively asymptomatic.
 - If fractures cross sinuses, sutures or dural/vascular grooves they have an increased risk of complications such as haemorrhage or infection.
- *Depressed*
 - A palpable bony depression may be felt. This can be difficult if overlying haematoma is present. With an open fracture the depressed fragment may be missed due to the mobility of the scalp.
 - The risk of brain injury increases with the depth of depression. Approximately 25% of patient will present with loss of consciousness. Neurological deficits depend on the underlying brain injury.
 - Increased risk of developing seizures and meningitis.
- *Basal*
 - Clinical signs include haemotympanum (or blood in the auditory canal), rhinorrhoea, otorrhoea, Battle's sign (retroauricular haematoma), racoon eyes (periorbital ecchymosis) and cranial nerve deficits (third, fourth and fifth).
 - Blotting paper is useful in a patient with a bloody nose to diagnose rhinorrhoea. Placed on blotting paper the CSF will extend further and appear as a lucent ring around the blood.

Radiological features

- Plain skull radiographs are the initial investigation with some progressing to CT.
- *Linear fractures* will appear as a deep black sharply defined line. May be mistaken for a suture line or vascular groove. A vascular groove often branches, has a sclerotic margin and has a typical site.
- *Depressed fractures* are often difficult to see. Look for increased or double density related to bones overlapping or being seen tangentially.

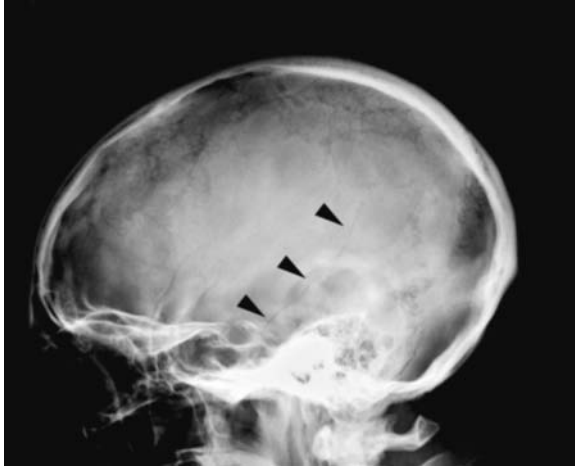

(a) Depressed skull fracture (arrowheads) with (b) CT correlation (different patient).

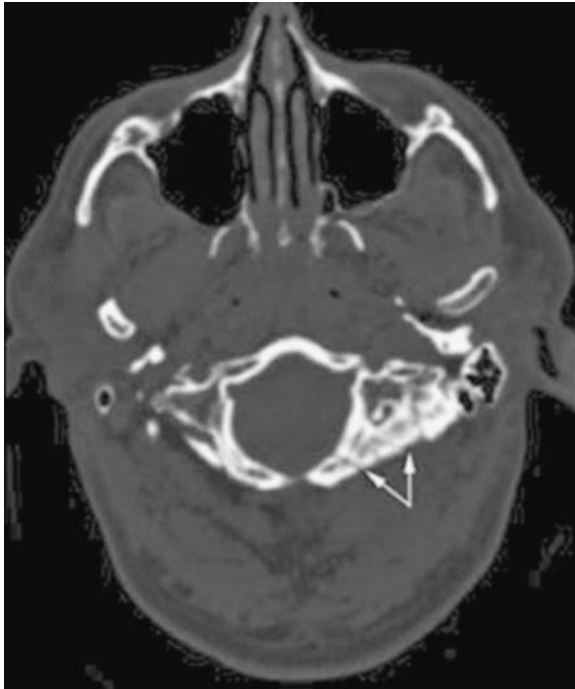
- *Basal skull fractures* are not well seen on plain radiographs. Look for fluid level within sphenoid sinus. If suspected the patient should have a CT.
- CT will often demonstrate skull fractures when viewed on bony windows. More useful for visualisation of secondary complications.

Management

- ABCs. Prevent secondary brain injury.
- Admit for observation. Discuss the management of the fracture, and subsequent complications, with a neurosurgeon.
- Most CSF leaks spontaneously resolve within one week without complications and thus prophylactic antibiotics should not be given during this time.
- If a fracture segment is depressed below the inner table, elevation is usually required.



Simple vault fracture (arrowheads).



Base of skull fracture (arrows).

Thoraco-lumbar spine fractures

Characteristics

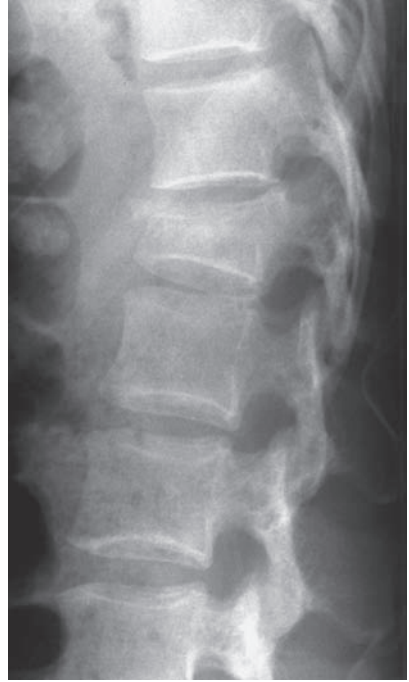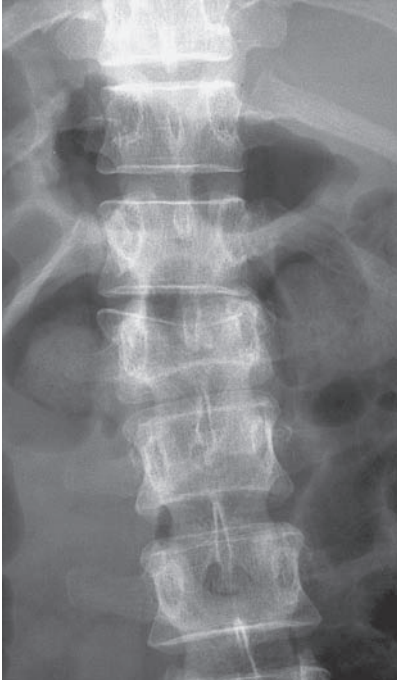- Thoraco-lumbar junction is the transition between the stiff thoracic kyphotic spine and the mobile lumbar lordotic spine.
- 50% of vertebral fractures and 40% spinal-cord injuries occur at T10-L2.
- Mechanism of injury:
 - *Axial compression* – burst fractures.
 - *Flexion* – anterior compression and posterior distraction.
 - *Lateral flexion* – lateral compression injuries.
 - *Flexion/rotation*.
 - *Translation* – antero-posterior or medio-lateral shear forces.
 - *Flexion-distraction* injuries – Chance fractures – bony or soft tissue.
 - *Extension* – anterior distraction with posterior compression.
- Classification:
 - Three columns of Denis – anterior, middle and posterior.
 - Two columns – anterior (vertebral body) and posterior (all elements behind the vertebral body).
 - AO – Magerl – identifies the area of the spine (bone group 5) as thoracic (5–2) or lumbar (5–3) and then considers mechanism of injury which is simplified to:
 - A Compression.
 - B Distraction.
 - C Combination of A/B with rotation, i.e. complex injuries.
- Spinal instability – an evolving concept – now used as defined by White & Panjabi as ‘the loss of the ability of the spine under physiological loads to maintain its pattern of displacement so that there is no initial or additional neurological deficit, no major deformity and no incapacitating pain’.

Clinical features

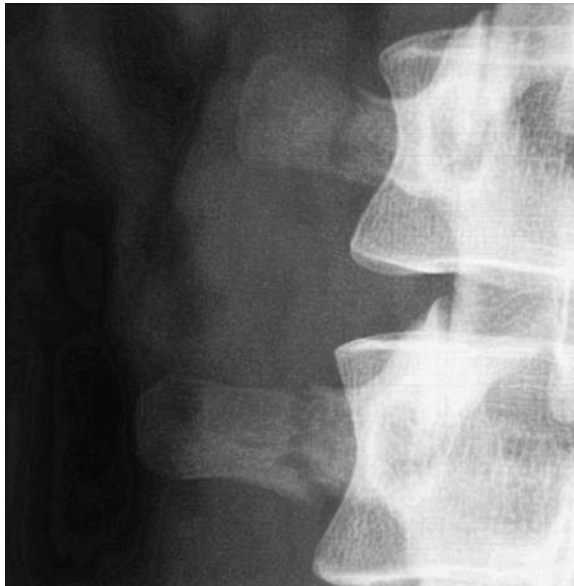- History of trauma – often falls from a height or RTAs, but in the elderly osteoporotic population the trauma may be minimal.
- Look for a cause for the fracture – significant trauma or pathological fracture. The spine is a common site of metastasis.
- Pain, localised tenderness, bruising may develop late.
- Careful neurological examination.
- Associated injuries with falls from height – chest/abdominal trauma, os calcis, tibial plateau, wrist and scaphoid fractures.

Radiological features

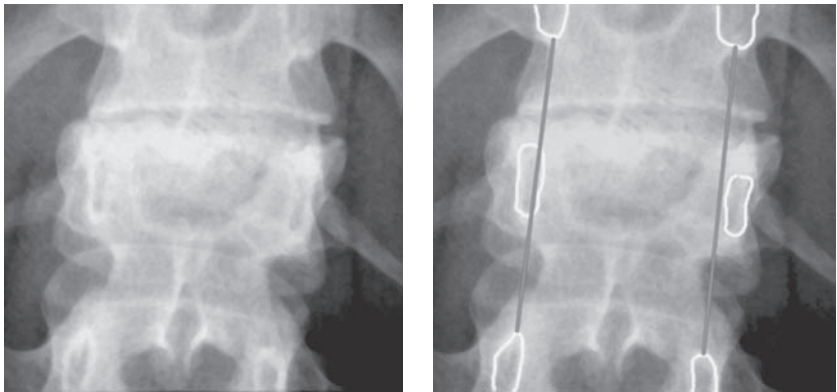
- AP/lateral:
 - Loss of vertebral alignment (AP or lateral) – look at spinous processes on AP.
 - Loss of vertebral body height, wedging and kyphosis.
 - Interpedicular widening on AP radiograph.



Post-traumatic wedge compression of L2.



Transverse process fractures: this type of injury is associated with significant soft-tissue trauma.

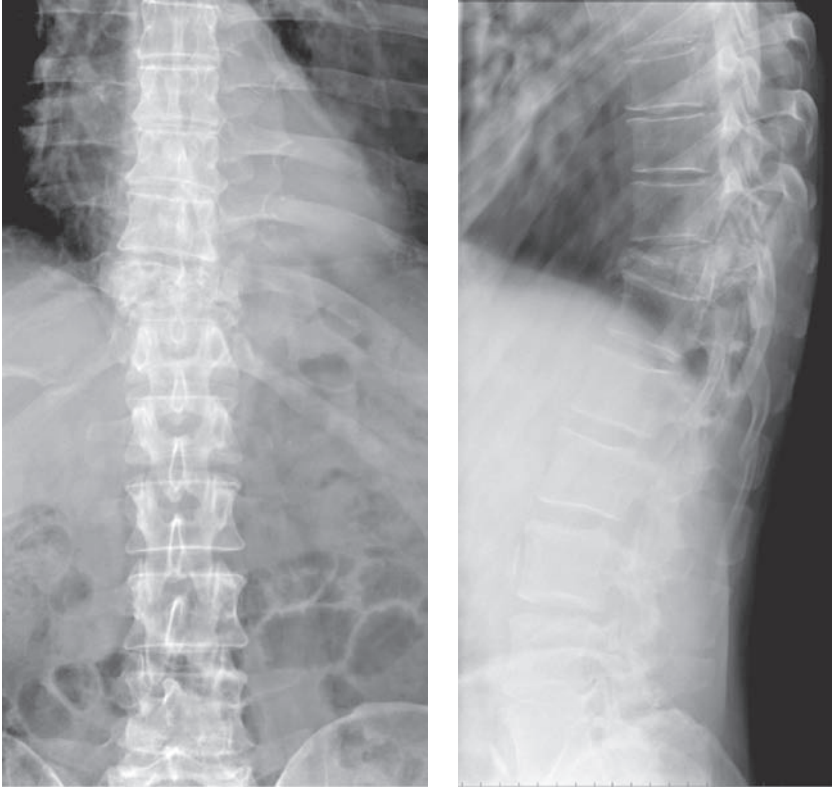


Widened interpedicular distance.

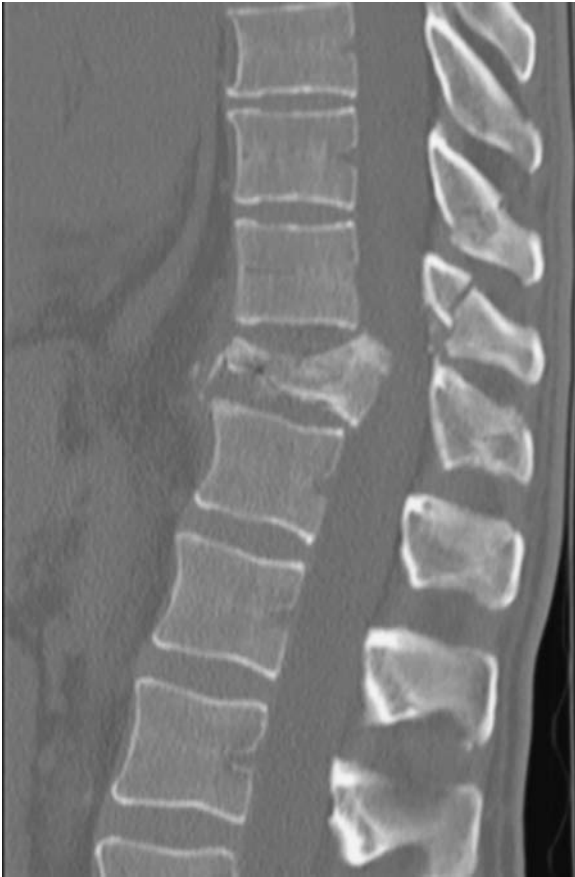- Fractures through the body, posterior spinous or transverse processes.
- Interspinous widening because of ligamentous disruption.
- Standing (sitting if not able) lateral X-ray helps to identify significant collapse.
- CT demonstrates the fracture well and can carefully assess for the presence of retropulsed fragments.
- MRI is most useful to assess any spinal-cord damage and ligamentous disruption.

Management

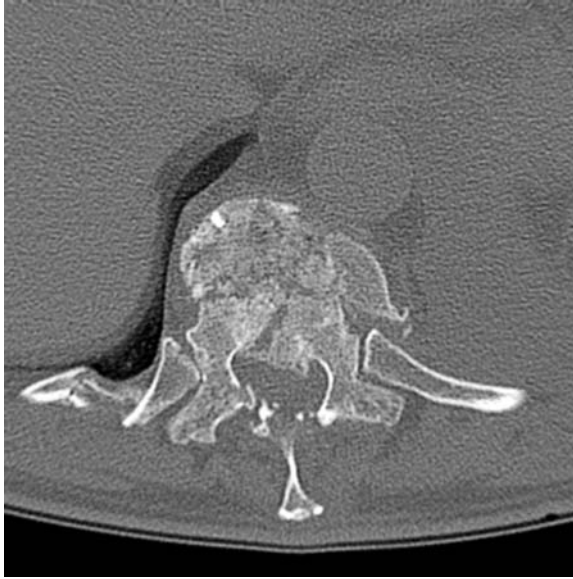- ABCs.
- Careful neurological assessment.
- Determine stability of the fracture – using the two-column theory. If both columns are injured the fracture is unstable. A pure anterior compression fracture, with <50% reduction in vertebral height, is likely to be stable.
- Non-operative treatment of stable fractures varies from full mobilisation to bracing (such as a TLSO – thoraco-lumbosacral orthosis) to plaster jackets for approximately 6 weeks.
- Non-operative treatment of unstable fractures involves prolonged (approximately 6 weeks) bed-rest with careful attention to DVT prophylaxis, pressure care etc.
- Indications for operative treatment, are:
 - Neurological injury – early decompression and stabilisation allows better rehabilitation and possible (partial) neurological improvement.
 - Both columns are injured.
 - Contiguous-level compression fractures.
 - Fracture – dislocations.
- Operative treatment should be by a specialist spinal surgeon/unit with decompression of the spinal cord and either anterior or posterior instrumented fusion.



Burst fracture of T11: AP and lateral radiograph.



Burst fracture of T11: sagittal CT reformat.



Burst fracture T11: high resolution CT. The complexity of the fracture and retropulsed fragments within the spinal canal are clearly demonstrated.

Acromioclavicular joint injury

Characteristics

- Mechanism of injury commonly involves a blow to the point of the shoulder with the arm adducted. Contact sports are often involved.
- The acromioclavicular ligaments rupture first followed by the coracoclavicular ligaments and the muscular attachments of deltoid and trapezius.
- With a fall onto the outstretched hand, only the acromioclavicular ligaments will be involved.
- Classified simply as follows:
 - I. *Sprain of ligaments*. Anatomical relationships preserved.
 - II. *Subluxation*. Rupture of the acromioclavicular ligaments. The distal clavicle rides upwards, usually by less than half its width. Coraco-clavicular ligaments intact.
 - III. *Dislocation*. Rupture of the acromioclavicular and coracoclavicular ligaments. Trapezius and deltoid insertions avulsed. The coraco-clavicular distance is greatly increased as the clavicle rides upwards.
- Other classifications are used such as the six-grade Rockwood classification.

Clinical features

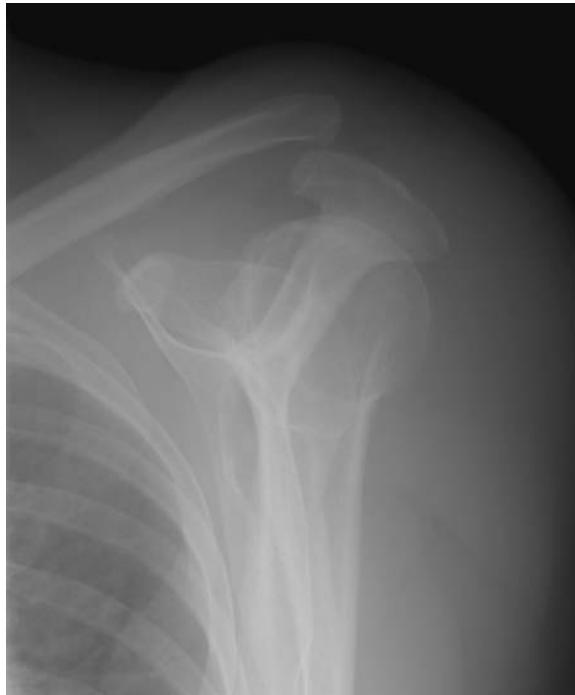- Suspect from the history and ask the patient to point to the site of pain – classically the patient will use one finger directly over the ACJ.
- Examine the patient standing as this may allow asymmetry to be seen.
- With minor sprains, the patient will often complain of precisely localised pain and tenderness but a full range of movement is often possible.
- As the severity of sprain progresses the functional loss is more pronounced with a clinical deformity obvious.

Radiological features

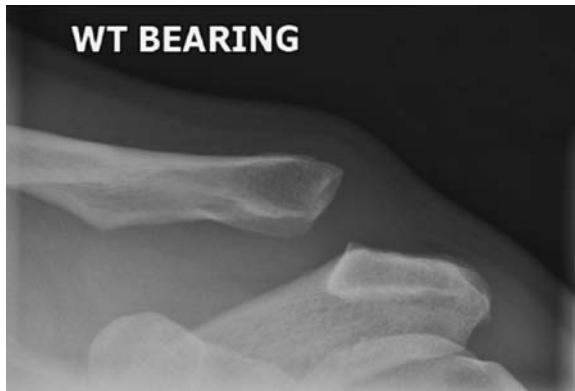
- Recommended views include AP, 15° cephalic tilt and axial views.
- Specific AC joint views should be specified as the beam direction and exposure is different from gleno-humeral shoulder views.
 - Grade I are radiographically normal.
 - Grade II show widening of the joint with upward displacement of the clavicle.
 - Grade III have a widened coracoclavicular space (greater than 13 mm or a difference of >5 mm between sides) and complete disruption of the acromioclavicular joint (normal distance <8 mm).
- Stress views were commonly requested but cannot be recommended due to the discomfort caused and the high rate of false negatives seen from muscular spasm.

Management

- *Grade I* Analgesia and broad arm sling/polysling for comfort.
- *Grade II* As above. Physiotherapy for mobilization if needed.
- *Grade III* Adequate analgesia and broad arm sling. Controversy exists as to the best management of these cases, i.e. operative vs. non-operative; a safe approach is non-operative management initially with surgical reconstruction (e.g. Weaver Dunn) for the symptomatic Grade III patients after 6 months.



Acromio-clavicular joint dislocation.



Stress views are sometimes performed to draw attention to the subluxation/ dislocation.

Carpal dislocation and instability

Characteristics

- Occurs following wrist/hand trauma or with degenerative instability, e.g. rheumatoid wrist.
- Spectrum of injuries produced by wrist hyperextension, ulnar deviation and intercarpal supination.
- Classified into four (Mayfield) categories with sequential ligamentous damage:
 1. *Scapholunate dislocation* – scapholunate ligament tear.
 2. *Capitolunate dislocation* – capitolunate ligament tear.
 3. *Lunate-triquetral dislocation* (midcarpal or peri-lunate dislocation) – luno-triquetral ligament tear.
 4. *Lunate dislocation* – radiolunate ligament tear.

Clinical features

- Pain and carpal swelling.
- Limited wrist movement.
- Localised tenderness especially in the scapholunate region.
- Often present late as missed injuries or persistent pain after supposed 'minor' trauma.

Radiological features

- Postero-anterior (PA) and lateral views essential.
- Comparison with the opposite side often helpful.
- On the lateral view look at the relationship between the distal radius, lunate and capitate (often described as saucer, cup and apple).
- With *scapholunate dislocations*, there is an increased (3 mm) gap between scaphoid and lunate on the AP view. This is described as the Terry Thomas sign after the aforementioned British comedian's front teeth!
- With *perilunate dislocations*, the capitate is dislocated dorsally in relation to the lunate. The alignment of lunate and distal radius (saucer and cup) appears normal.
- In *mid-carpal dislocations*, appearances are similar to above except the triquetrum is dislocated. This is best seen on the PA view as it overlaps the lunate or hamate.
- With *lunate dislocations* the lunate dislocates forwards, i.e. the 'cup tips forwards spilling its contents' on the lateral view. The capitate remains aligned in relation to the radius. On the AP view, the lunate has a characteristic triangular appearance due to volar tilt.

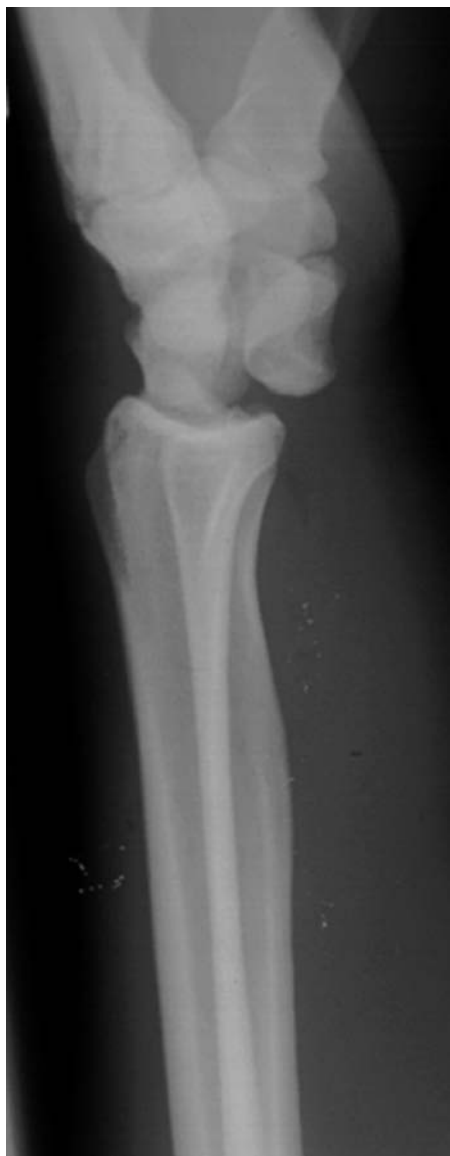DISI = dorsal intercalated segmental instability (also known as rotatory subluxation of the scaphoid) is dorsal angulation of the lunate relative to the scaphoid and the radius, because of scapholunate dissociation – either from fracture or scapho-lunate ligament

injury. Look for the ‘cortical’ or ‘signet’ ring sign because a flexed scaphoid appears in axial profile on the AP projection.

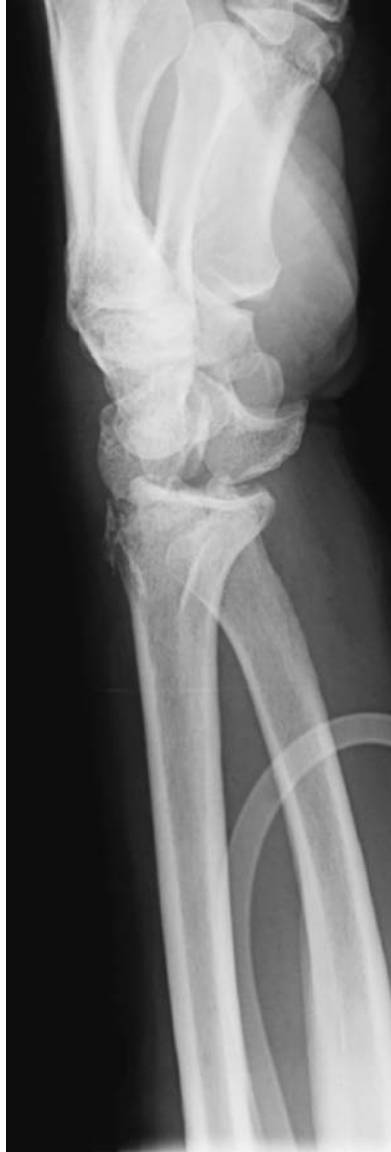VISI = volar intercalated segmental instability, where the lunate is flexed thus decreasing the scapholunate and radiolunate angles, is much rarer.

Management

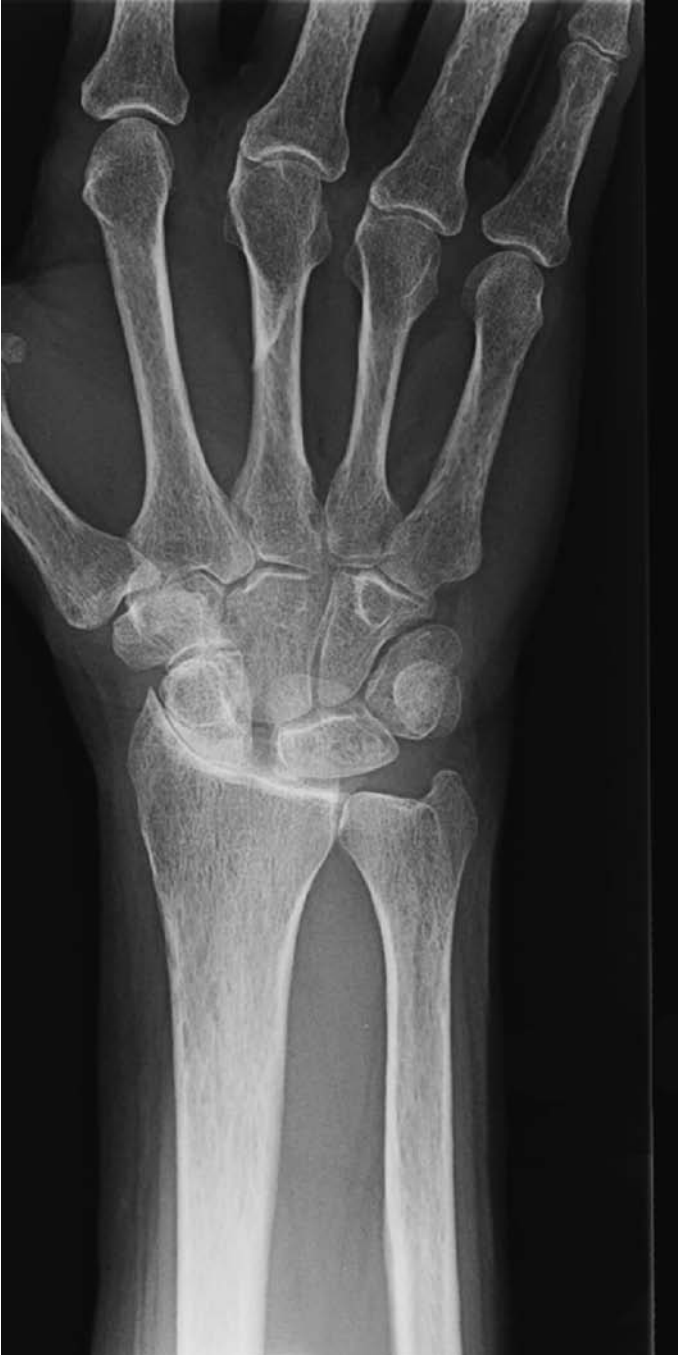- Analgesia and reduction – as soon as possible in the acute situation.
- Often requires open reduction and ligamentous repair, with temporary stabilising k-wires or ORIF.



Lunate dislocation.



Perilunate dislocation.



'Terry Thomas' sign. Degenerate scapholunate ligament disruption.



Clavicular fractures

Characteristics

- The majority are caused by direct force to the shoulder, e.g. fall. Less commonly the fracture is secondary to transmitted force from falling onto an outstretched hand.
- The most common site is the junction of middle and outer third (80%).
- May be associated with a sternoclavicular or acromioclavicular dislocation.

Clinical features

- Patients will complain of pain at the site of the fracture and will be reluctant to move their shoulder or arm.
- There may be anterior, inferior and medial displacement of the shoulder in mid clavicular fractures due to the action of attached muscles.
- A palpable step and fracture crepitus can often be felt.
- Rarely these are open injuries.
- Occasionally the skin can be tethered on fracture ends; as long as the skin is not jeopardized it is safe to treat this as a closed fracture. The skin usually separates off from the fracture ends, as a sling is applied.
- Pressure necrosis of the overlying skin is a rare but serious complication.
- Rarely there may be an associated pneumothorax or neurovascular injury.

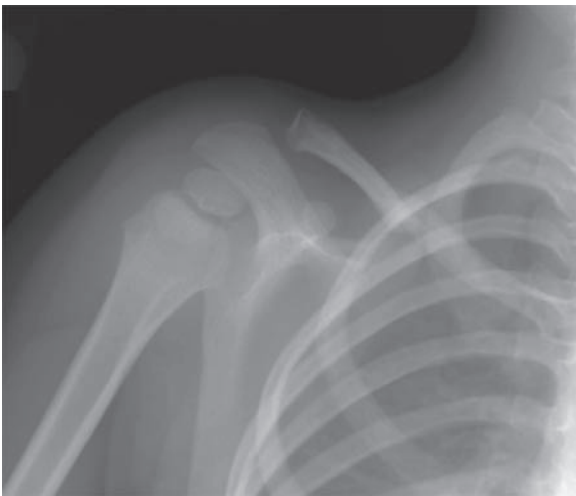
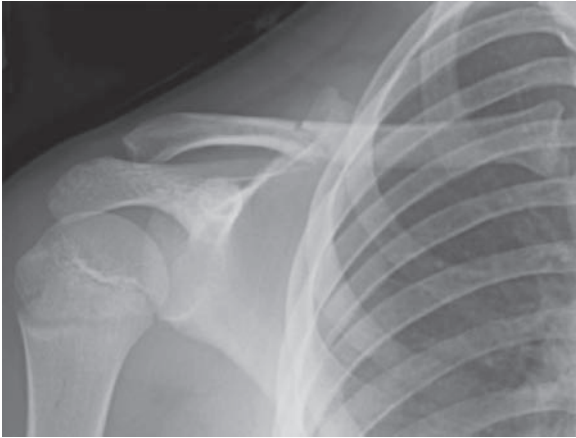
Radiological features

- A single AP view is usually adequate.
- Often the fracture line is obvious, although in children a greenstick fracture can be difficult to see, but treat as below and review at 2 weeks will distinguish the fractures.
- Beware subtle pneumothorax secondary to a bony fragment.
- In a patient with a history of malignancy, or when the history does not support the presence of a traumatic injury, a pathological fracture should be considered.
- This may be secondary to recurrent disease but always ask for a history of radiotherapy as radionecrosis can mimic metastasis.

Management

- ABCs, assess soft tissues and neurovascular status and immobilise.
- Open injuries need urgent wound excision, washout and ORIF.
- The principles of management include analgesia and support of the arm, for example with a broad arm sling/polysling. Some surgeons (particularly in mainland Europe) advocate braces/modified collar and cuff constructs to adduct the scapulae, thus lengthening the clavicles as the shoulders are 'set back'.

- Growing evidence for early ORIF in widely (3 cm) displaced fractures.
- Supports should be discarded as pain settles.
- Physiotherapy useful to maintain glenohumeral movement.
- Chance of non-union should be discussed with the patient and persistent pain investigated with repeat radiographs \pm CT if no evidence of callus.
- Non-unions generally managed with ORIF and bone graft.



Two examples of subtle fractures of the middle third of the right clavicle.

Elbow injuries and distal humeral fractures

Included in this group are fractures of the capitellum, trochlea, medial and lateral condyles (the pillars or columns) and epicondyles.

Capitellum fractures

Characteristics

- Fall onto outstretched hand.
- Often associated with radial-head fractures.

Clinical features

- May present late.
- Limited flexion and localised tenderness.

Radiological features

- The fracture may be obvious with displacement of the capitellum.
- Subtle undisplaced fractures will have an associated effusion with elevation of the anterior and posterior fat pads.
- Beware associated radial-head fractures.

Management

- ABCs and initial management with posterior splint and elevation.
- If displaced or fragment acting as intra-articular loose body, surgery is required.
- CT useful to exclude intra-articular lesions and to assess possible reconstruction.
- ORIF with intra-articular (buried) screws or posterior lag screw.

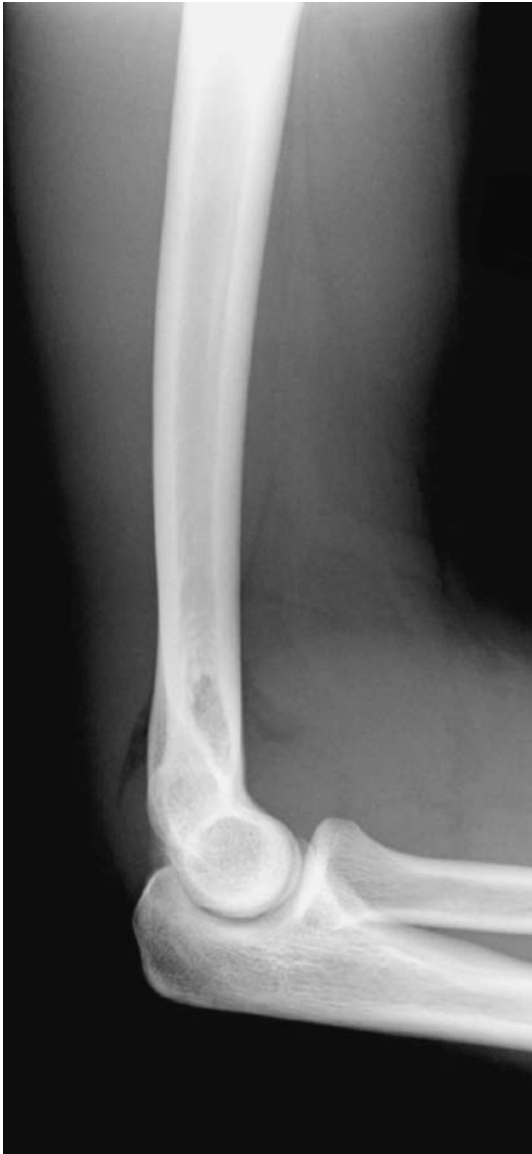Trochlea fractures

- This is a variant of a one (ulnar/medial) column injury of the distal humerus.
- Intra-articular displacement >2 mm should be reduced if possible with ORIF using lag screws.
- For larger, more proximal medial-column injury, ORIF with medial contoured plates is the standard treatment.

Fractures of the distal humerus (see paediatric supracondylar fracture – below)

Characteristics

- Divided into single or both column injuries, or epicondylar fractures.
- The supracondylar region is particularly at risk because of the thin nature of the olecranon fossa.



An underlying bony injury must always be carefully sought when a significant joint effusion is identified in the context of trauma. Note the elevated anterior and posterior fat pads.

- The support is provided by the medial (ulnar) and lateral (radial) columns culminating in the trochlea and capitellum respectively.

Clinical features

- In children and elderly patients moderate trauma alone is sufficient to damage the distal humerus.

- Careful neuro-vascular assessment is always required and meticulous intra-operative protection of such structures.
- Pain, swelling, deformity \pm elbow dislocation.
- Open injury not unusual.

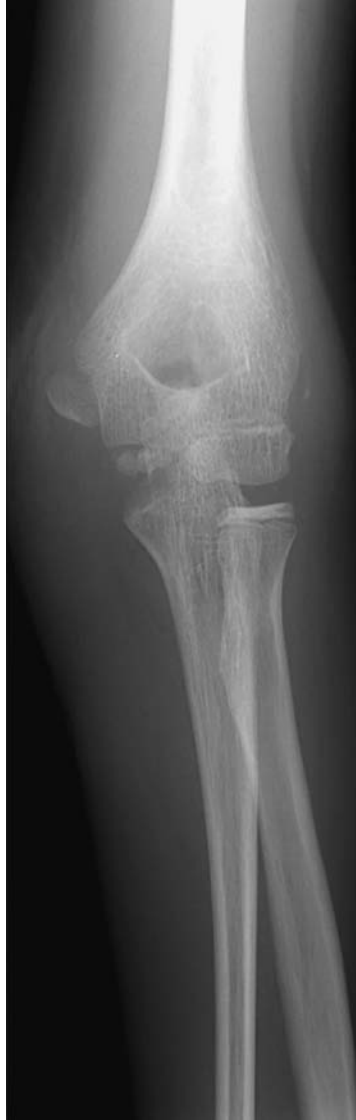Radiological features

- AP and lateral films should be obtained – occasionally oblique films are useful e.g. to assess radio-capitellar alignment – remember that a line from the radial head should always transect the capitellum in whatever plane of X-ray.
- Often difficult in children because of multiple ossification centres. Compare with opposite side if suspicion. CT or examination under anaesthetic with arthrography may be useful to determine intra-articular steps and loose fragments.
- Typically, the epiphyses start to ossify as follows: – Capitellum – 1 yr, Radial head – 3 yrs, medial (Internal) epicondyle – 5 yrs, Trochlea – 7 yrs, Olecranon – 9 yrs, Lateral epicondyle – 11 yrs. This is usefully remembered by ‘CRITOL’ 1, 3, 5, 7, 9, 11 years.
- Whilst the CRITOL principle does not strictly apply in all patients, the trochlear centre invariably ossifies after the internal epicondyle. In other words, if the trochlear ossification centre is present then the centre for the internal epicondyle *must* be present. **Beware missing the avulsed medial epicondyle apophysis!**
- CT is useful for consideration of ORIF and its surgical planning.

Management

- *Epicondylar fractures.*
 - Medial epicondyle frequently fractured in children in association with a posterior elbow dislocation – most fragments will unite with non-operative management. Beware the ‘lateral epicondylar fracture’, which is in fact a lateral condylar injury.
 - Associated elbow dislocations should be reduced as soon as possible under sedation or general anaesthetic and then careful assessment is needed – for any intra-articular fragments such as the remnants of the epicondylar avulsion fragment.
- *One-column injury.*
 - In children: lateral $>$ medial condyle – usually requires manipulation and k-wire fixation or ORIF.
 - In adults undisplaced fractures should be immobilised with relaxed muscles on the relevant side to prevent displacement – thus pronation for medial column and supination to relax the lateral common extensor origin.
 - Displaced fractures require ORIF – with contoured/medial plate fixation or lag screws alone for very distal fractures.
- *Two-column injury.*
 - *Children* – this represents the supracondylar fractured humerus – see separate section.

- *Adults* – two-column injury is fortunately rare in adulthood. Significant displacement is managed by ORIF with two plates (lateral dynamic compression plate and medial contoured reconstruction plate). Exposure of the fractures simultaneously may require a posterior approach and olecranon chevron osteotomy.



Partial avulsion of the medial epicondyle.

Hand injuries – general principles

Characteristics

- Included in this group are phalangeal/metacarpal fractures, small-joint subluxation/dislocations and ligament injuries, tendon and nerve injuries.
- Hand injuries are common, e.g. industrial/agricultural trauma, domestic DIY and kitchen-knife injuries, glass injuries, sporting trauma and the ubiquitous road trauma.
- All ages are afflicted by hand injury.

Clinical Features

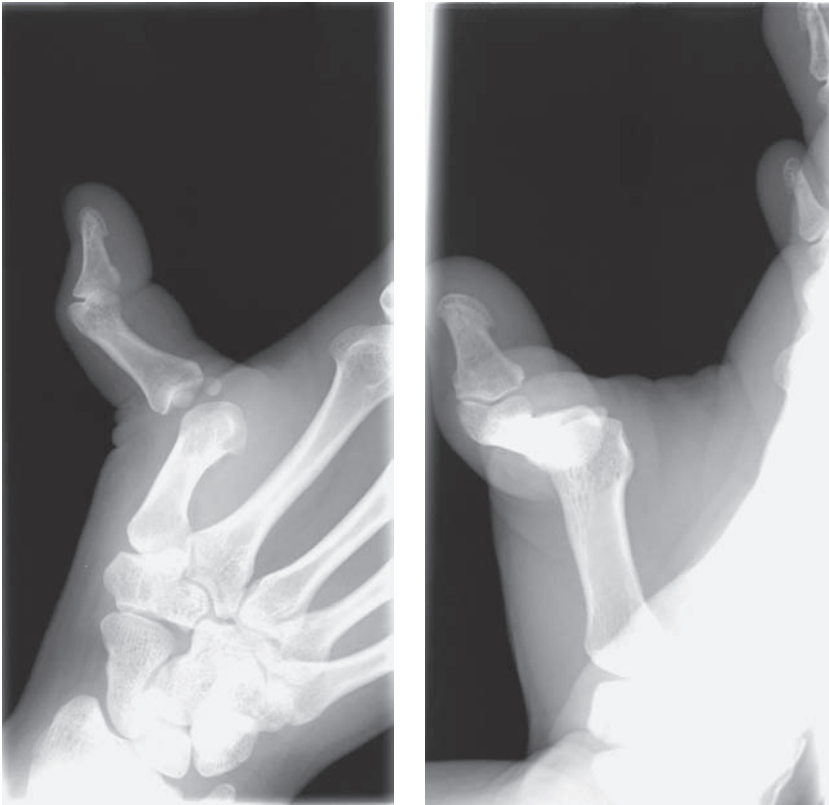
- Swelling, bruising, deformity, reduced range of movement, fracture crepitus and compartment syndrome are possible findings.
- The clinical history and examination should separate soft tissue from bony pathology and also joint from bone injury.
- Comparative examination (with contralateral side) particularly useful in one-side injuries, e.g. normal rotation, capillary refill and sensation.

Radiological features

- AP and lateral view centred on the appropriate bone/joint with adjacent joint essential.
- Look for fractures, including small avulsion fractures indicative of tendon, ligament or volar plate injury.
- Look at alignment – assessing joint subluxation/dislocation – usually obvious on the lateral but look for bony overlap on the AP film.
- Soft-tissue swelling can also be seen on radiograph.
- Assess the articular surface carefully for fractures, depression and loose bodies.

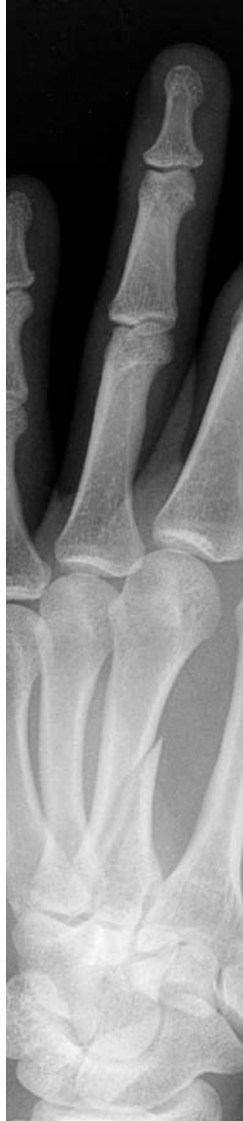Management

- Assess soft tissues, neurovascular status and (after any reductions) immobilise initially.
- Metacarpal block ('ring block') with local anaesthetic into the web space either side of the injured digit, gives good analgesia (up to 8 hours if bupivacaine used) for initial assessment and the emergency treatment of injury.
- Dislocated joints and displaced fractures should be reduced, and stability assessed, and open fractures should be irrigated as soon as possible and a dressing applied.
- Non-operative treatment for undisplaced fractures and stable joints after reduction of a dislocation.
- Operative treatment for displaced or unstable fractures, intra-articular injury with a visible step, recurrent dislocations or subluxation, some missed injuries, e.g. mallet deformity presenting late.



Dislocated first MCPJ.

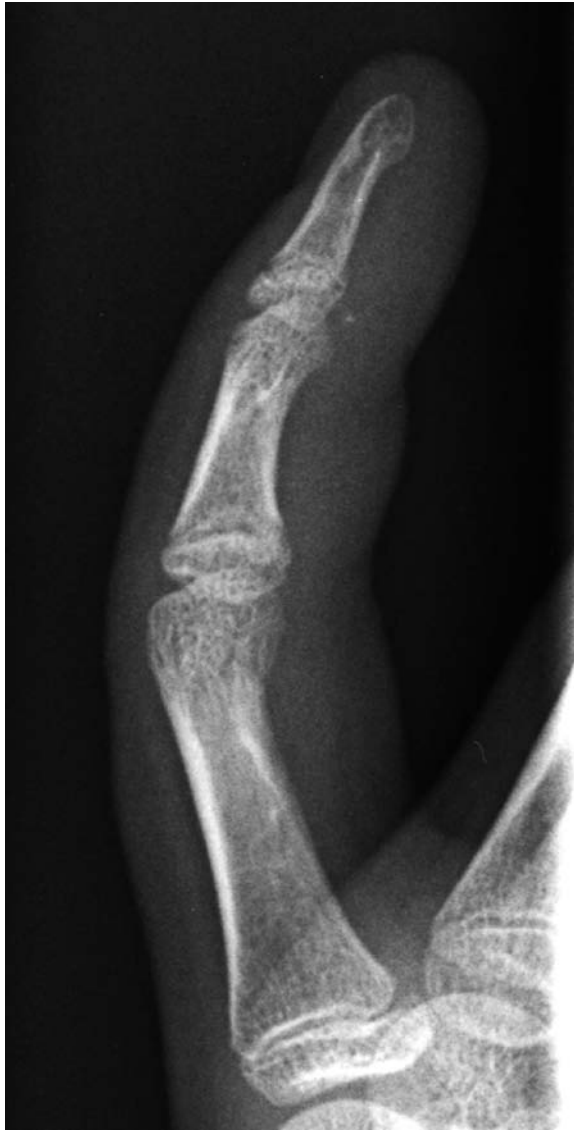- All hand injuries require elevation – pillows or Bradford sling – to reduce existing and potential swelling.
- Where possible, active movement should be encouraged to promote blood supply and venous drainage – again reducing swelling.



Spiral fracture of the middle or long finger metacarpal.

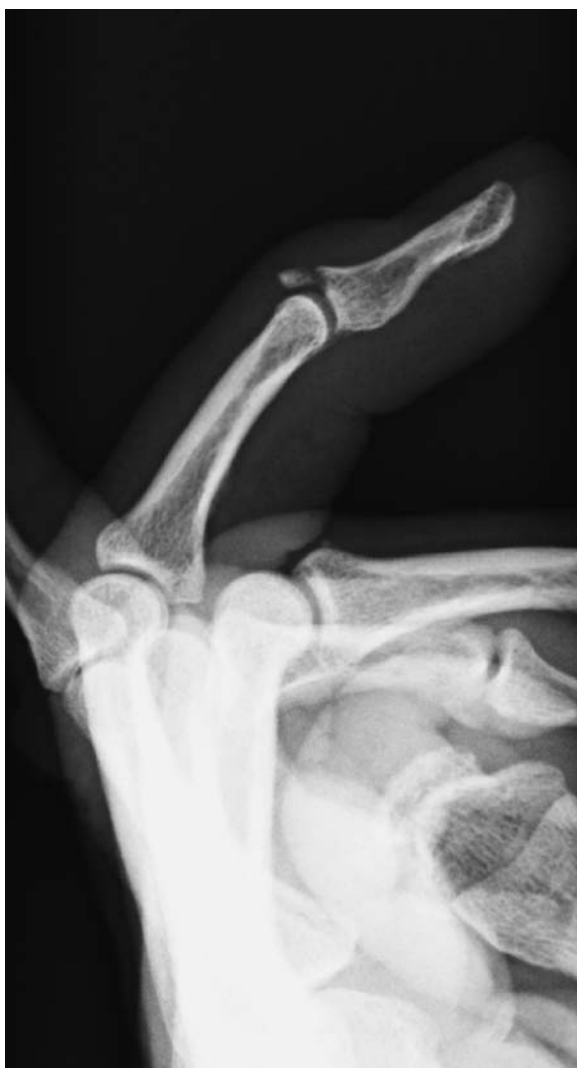Joint injuries

- *MCP* = metacarpophalangeal joint.
 - Dorsal dislocations:
 - Forced hyperextension.
 - Usually thumb, index or little fingers.
 - Simple – clinically obvious and easily reduced in the Emergency Dept.
 - Complex – less deformity, frequently volar skin dimpling and entrapment of volar plate – often seen on lateral X-ray as a sesamoid/loose body in the MCPJ – most require open reduction.
 - *Collateral sprains*.
 - Forced ab/adduction of the fingers (see below for thumb).
 - May be an avulsion from the metacarpal head of the collateral origin – possibly visible on the lateral X-ray.
 - Most treated non-operatively with neighbour strapping/mobilisation.
 - Operative intervention if >20% articular surface avulsed.
- *PIP* = proximal interphalangeal joint.
 - Collateral sprains:
 - Radial > ulnar collaterals.
 - Index finger most significant because of importance in key grip.
 - Most treated non-operatively with splintage (approximately 1–2 weeks) and mobilisation in neighbour strapping.
 - *Volar plate*.
 - See below.
 - *Dorsal dislocation*.
 - Common injury caused by hyper-extension.
 - Most reduce closed with metacarpal block, although sometimes an open injury requiring irrigation, reduction and repair.
 - Beware rotated digits in which the middle phalanx may be lodged between the lateral band and the central slip of the extensor. These often require open reduction.
 - *Volar dislocation*.
 - Uncommon injury – may have spontaneously reduced.
 - Carefully assess the central extensor slip (resisted extension) which is frequently ruptured and blocks reduction forcing operative intervention. Look for an avulsion fragment/pit on the lateral X-ray.
 - *Fracture–dislocation*.
 - Serious injury jeopardising the PIPJ – look carefully at the lateral X-ray not to miss associated fractures with any dislocation.
 - Operative management most common with closed/open reduction and k-wiring, ORIF or dynamic external fixation with modified k-wires.



Volar plate fracture IPJ.

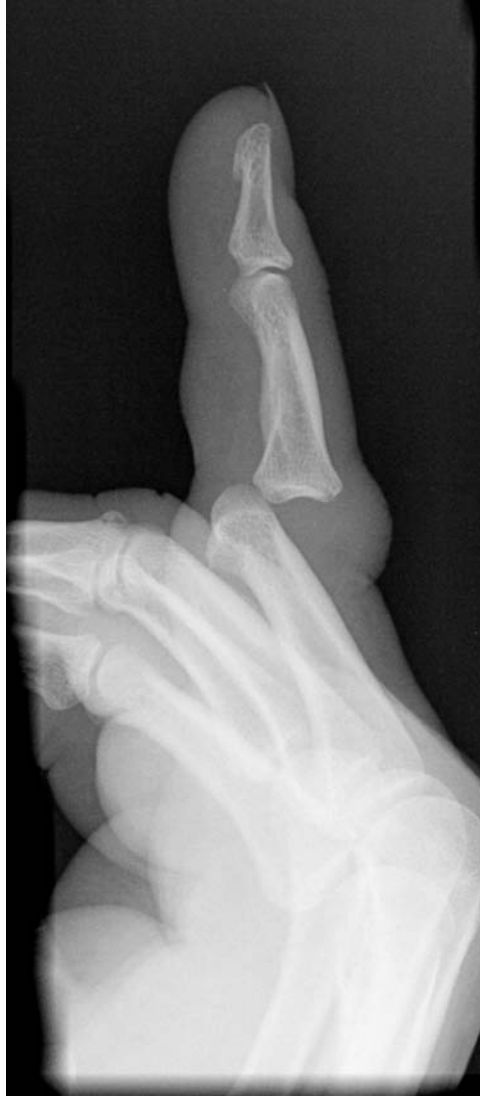- *DIP/TIP = distal or terminal interphalangeal joint.*
- Mallet deformity:
 - Very common injury following forceful DIPJ flexion.
 - May be closed, open, with soft-tissue loss or with associated peri-physeal fracture in children.
 - Extensor tendon is avulsed from the distal phalanx alone or with a small avulsion fracture.
 - Majority managed with DIPJ extension splints, e.g. Zimmer padded aluminium strip secured in slight hyperextension on the



Mallet deformity with an associated avulsion fracture DIPJ.

dorsum of the DIPJ for 6 weeks, followed by 6 weeks' night splintage.

- Operative intervention for fragments >30% of the articular surface of the distal phalanx, those with a significant articular step and the missed diagnosis presenting late.
- *Dorsal dislocation.*
 - Common injury with forced hyper-extension of the tip of the finger.
 - Frequently open on the volar surface (60%) where the volar plate was avulsed and the skin is adherent to bone.
 - Most treated with closed reduction after irrigation of the open injuries.

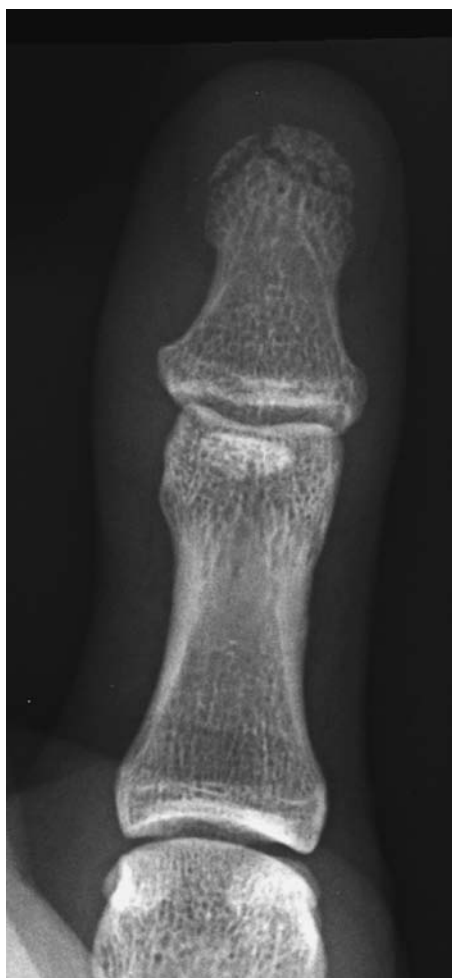

Dorsal dislocation PIPJ.

- Volar plate, avulsion fragments and the flexor profundus tendon can all interpose in the DIPJ necessitating open reduction.

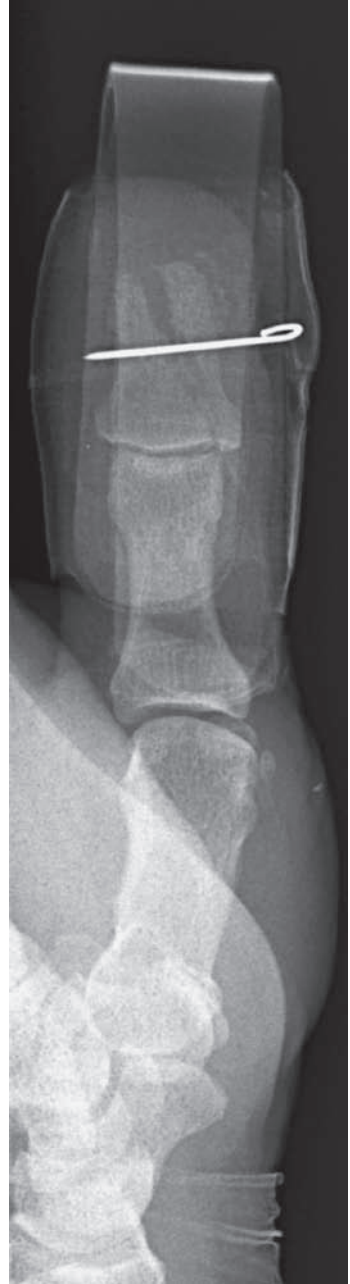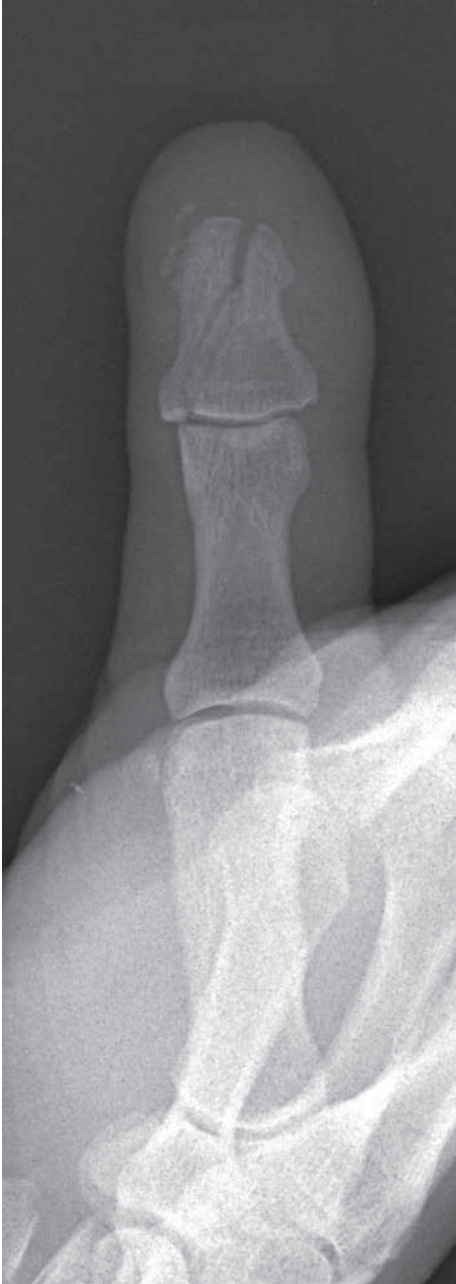Ligament injury

- *Thumb ulnar collateral.*
 - ‘Skier’s thumb’ (acute) caused by forced abduction of the thumb (against the ski pole as the body weight continues forward) and ‘game-keeper’s thumb’ (chronic) caused by repetitive injury by ‘wringing’ necks.
 - Tenderness over the ulnar collateral ligament (UCL) origin.



Tuft fracture.

- Fullness in the UCL may indicate a Stener lesion = interposition of the adductor pollicis preventing the UCL from re-attaching to the metacarpal.
- Assess UCL in slight flexion and compare sides. Use a metacarpal block and see how much the joint opens – $>30^\circ$ is complete UCL incompetence and requires exploration (to exclude the Stener lesion) and reattach the UCL to the metacarpal head, e.g. by suture anchors or suture tunnels.
- Stable UCL sprains are treated with splintage for analgesia and early mobilisation.
- This is a frequently missed injury which can result in persistent instability and post-traumatic arthrosis.
- *Thumb radial collateral.*
 - Less common and often missed.



Intra-articular fracture of the terminal phalanx of the thumb treated with k-wire fixation – this provides support for the soft tissues.

- Most treated with splintage/POP unless significant volar subluxation requiring operative repair.
- *Volar plate injury*
 - Avulsion of the volar plate from the middle phalanx following hyperextension of the PIPJ.
 - Consider dorsal subluxation.
 - Most treated with splintage in slight flexion for 1–2 weeks, then active mobilisation with neighbour strapping.

Fractures

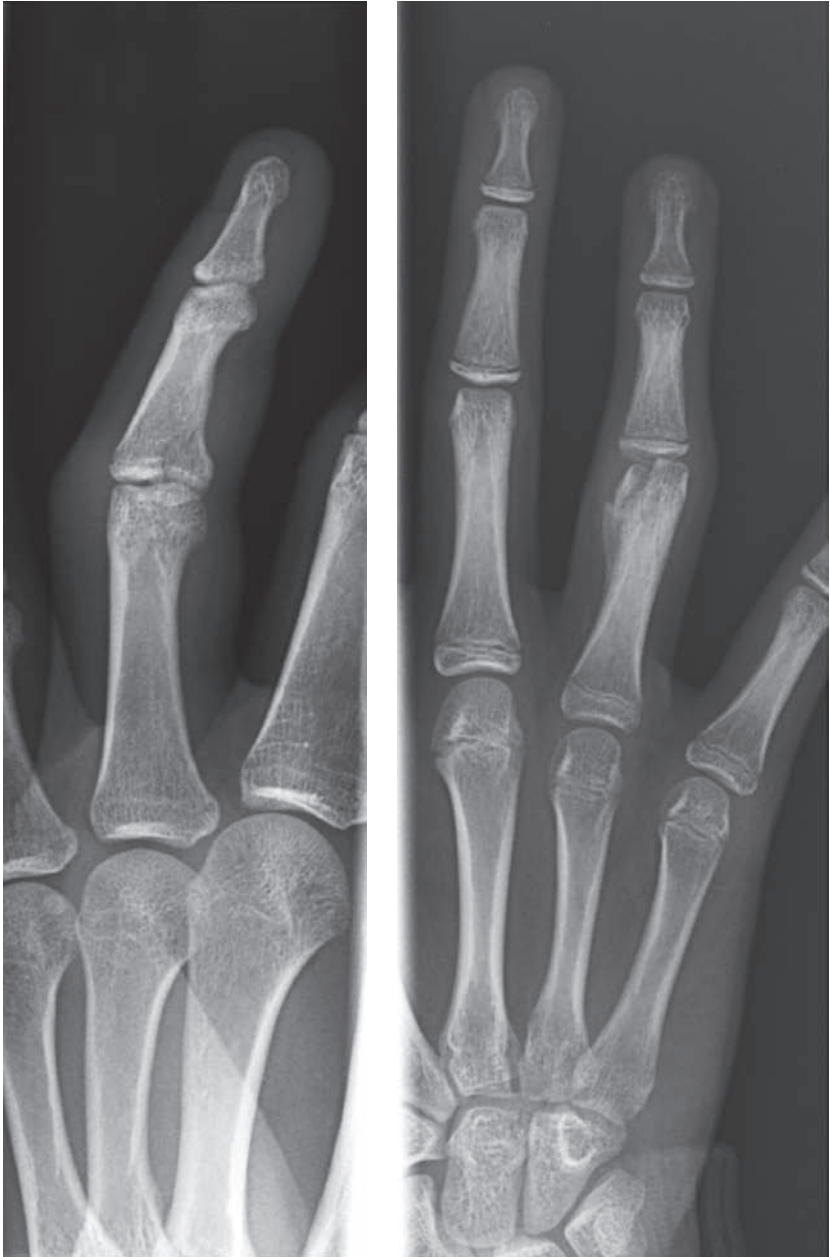- *Metacarpal fractures.*
 - *Base fractures:*
 - Significantly displaced fractures require MUA and k-wire, otherwise these are treated with mobilisation as pain allows.
 - Ulnar sided lesions tolerate greater displacement because of greater ulnar carpo-metacarpal mobility.
 - *Shaft fractures:*
 - Direct blow is the usual mechanism.
 - Manipulation and POP slab is the treatment of most, followed by mobilisation as pain allows.
 - Angulation and particularly rotational deformity in oblique and spiral fractures is an indication for operative treatment with either closed k-wires/POP or ORIF and early mobilisation.
 - *Neck fracture:*
 - Boxer's fracture.
 - Volar angulation (apex dorsal) $<40^\circ$ can be accepted, therefore most are treated non-operatively.
 - Manipulation and k-wiring $>40^\circ$ angulation.
 - *Head fractures:*
 - Displaced fractures require k-wire/ORIF.
 - Otherwise mobilise with neighbour strapping.
- *Phalangeal fractures.*
 - Undisplaced fractures should be mobilised with buddy strapping.
 - Displaced fractures may be manipulated alone under metacarpal block, manipulated and k-wired \pm POP, or ORIF and early mobilisation.
 - Intra-articular fractures require anatomic reduction of the joint surface.
 - The PIPJ should be allowed to mobilise as much as possible as it is the most sensitive joint to immobilisation.
 - Dynamic external fixation via modified k-wires has a role in the management of intra-articular DIPJ, PIPJ, or both joint fractures particularly where there is an element of volar subluxation.

Tendon injury

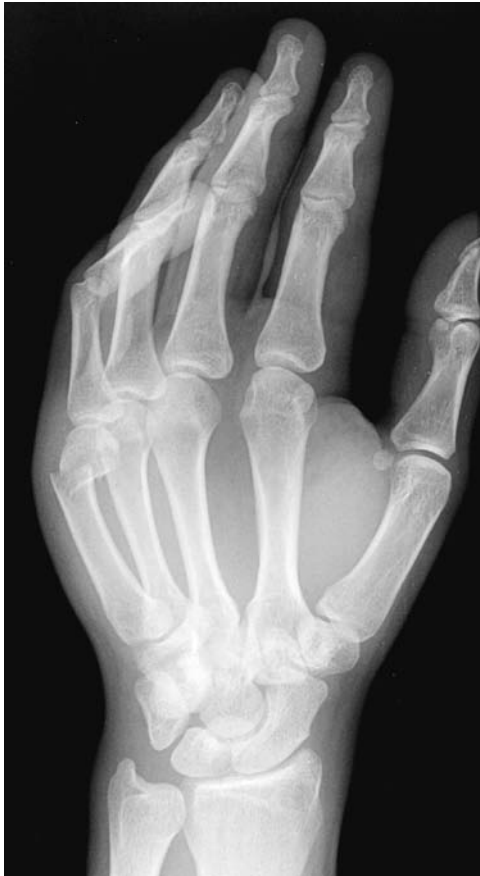- *Extensor.*
 - Operative repair.
- *Flexor.*
 - Operative repair.

Neurovascular injury

- *Ulnar/radial digital nerves.*
 - Operative repair – provides protective sensation at best, but decreases neuroma formation.



Two examples of intra-articular fractures of the PIPJ ring fingers.

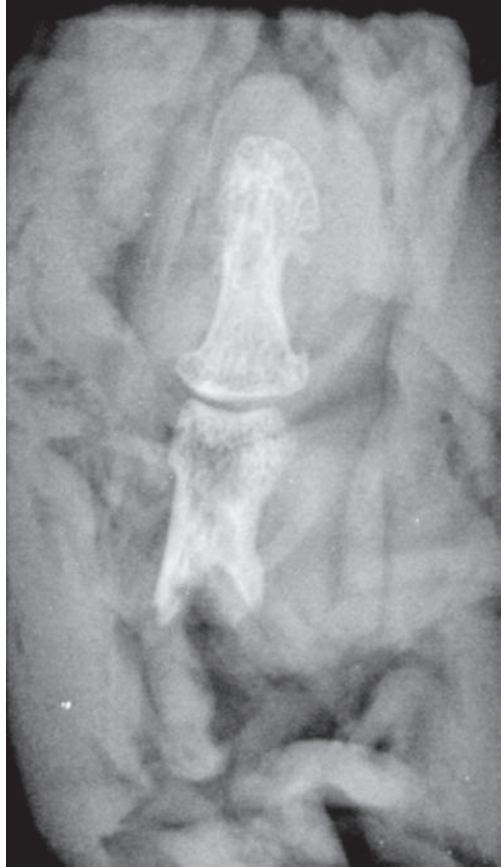
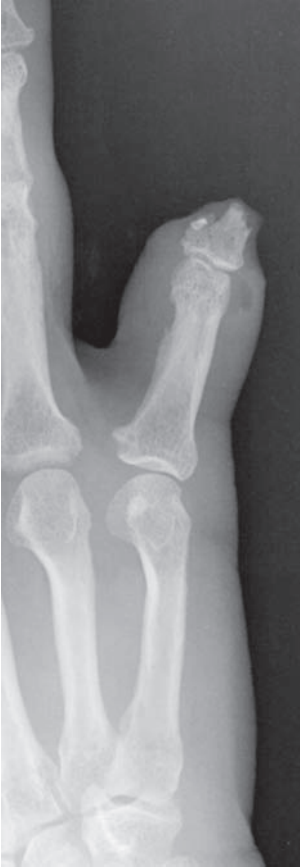
Angulated fracture of the neck of fifth metacarpal (Boxer's fracture).

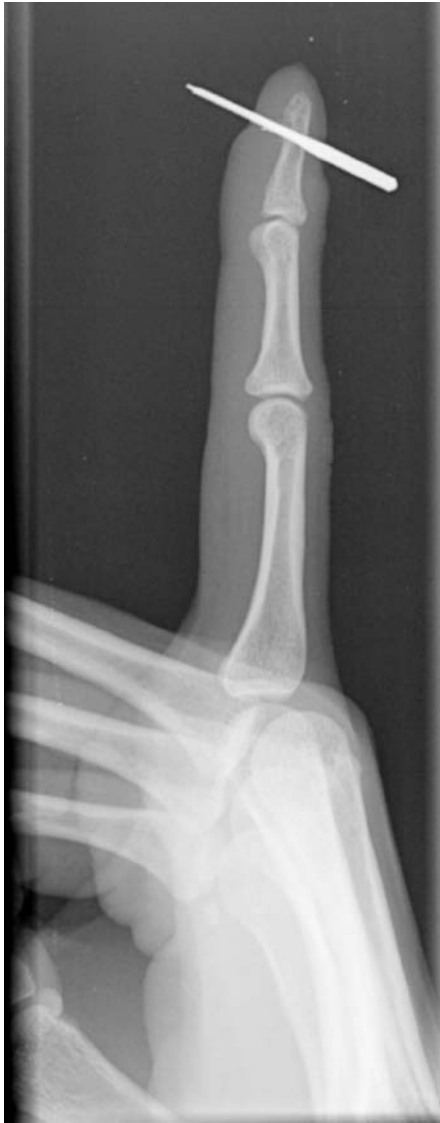- *Ulnar/radial digital arteries (UDA/RDA).*
 - If the finger is viable, then repair of one vessel is not required.
 - Injury to the artery from a volar wound implies nerve damage as the artery is dorsal to the nerve.
 - For injury to both the UDA and RDA, repair is indicated if possible.

Soft-tissue injury

- The list is extensive and beyond the scope of this book, but we have listed the more significant hand conditions not previously mentioned:
 - Infection – flexor-sheath infection must be considered and treated urgently.
 - Foreign body – from small splinters to injection of paint/oil.
 - Traumatic skin loss.
 - Burns.
 - Partial amputations and nail-bed injuries.
 - Crush injuries and compartment syndrome.



Traumatic amputation of the little finger through the base of the middle phalanx. The amputated digit accompanied the patient wrapped in cloth.



Foreign body (in this case a needle) through the terminal phalanx.

Thumb metacarpal fractures

Characteristics

- Most fractures involve the base of thumb and are classified as intra or extra articular fractures.
- Intra-articular injury is important as malunion preferentially impairs the important functions of key grip and opposition.
- The common types of intra-articular fracture have been described by Bennett and Rolando.
- Common secondary to forced abduction of the thumb.

Clinical features

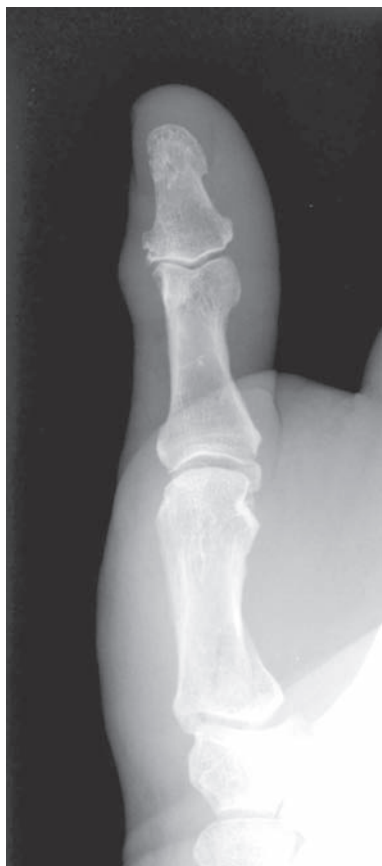- Pain, swelling and thenar bruising often evident.
- Thumb deformity/malalignment and reduced range of movement.

Radiological features

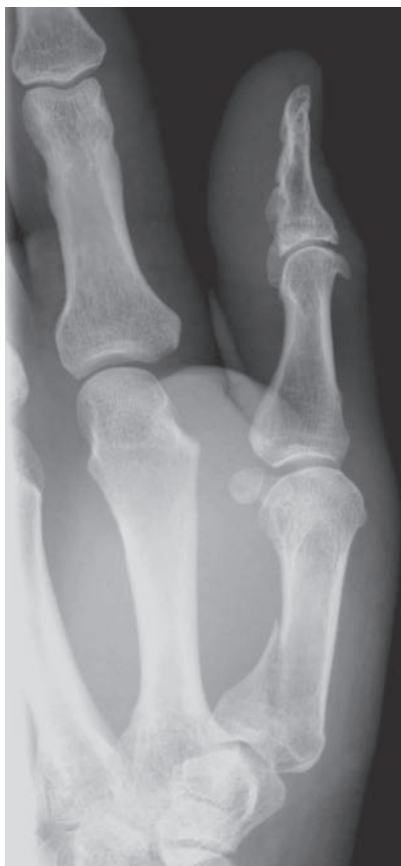- AP and lateral views essential – oblique view may be beneficial.
- *Bennett's fracture* – a distinctive small ulnar-sided fragment is seen to maintain its alignment with the trapezium. The thumb metacarpal is dislocated dorsally and radially due to the action of abductor pollicis longus.
- *Rolando fracture* – a fracture of the base of thumb extending into the carpo-metacarpal joint. The fracture line has a V or a T configuration.
- *Extra-articular fractures* are basal (transverse or oblique fractures just distal to the CMC joint) or pure shaft injuries.

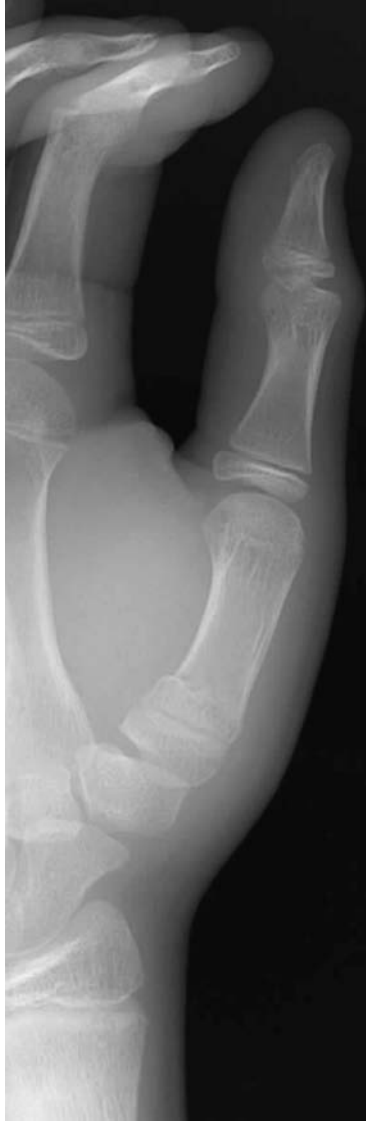Management

- Assess soft tissues, neurovascular status and immobilise initially.
- *Bennett's fracture* – Reduce with traction while abducting the thumb and applying pressure to the radial aspect of the base. K-wiring will usually suffice, but occasionally ORIF with large ulnar-sided fragments.
- Maintain position in a thumb spica and watch carefully in the hand/fracture clinic with weekly radiographs.
- *Rolando fracture* – Reduce and immobilise if undisplaced. ORIF for displaced fractures to restore CMC joint congruity.
- *Extra-articular fractures* – usually managed non-operatively as the thumb can tolerate 20° to 30° of angulation without functional impairment, because of adjacent joint mobility.



Rolando fracture.





Extra-articular fracture of the first metacarpal.

Humerus fracture – proximal fractures

Characteristics

- Common in the elderly osteoporotic population following a fall onto the outstretched hand.
- In the general population requires a more significant force, unless metastatic deposits are present in the proximal humerus.
- Depending on the forces applied, dislocation can occur concomitantly.
- Classified by Neer depending on the number and displacement of segments. The four segments described are: head, greater tuberosity, lesser tuberosity and shaft. Displacement is defined as separation of >1 cm or >45 degrees of angulation.

Clinical features

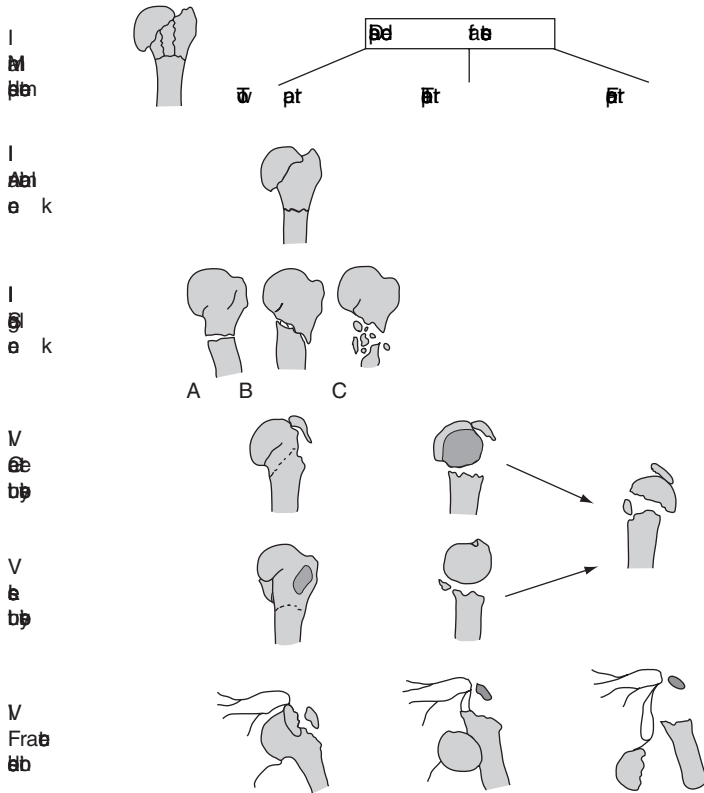
- The patient will complain of pain and be reluctant to move the arm, often supporting the elbow with the contralateral hand.
- Deformity may be present with associated bruising and/or fracture crepitus.
- Check and document axillary-nerve sensorimotor function – look/feel for a flicker of isometric deltoid contraction by asking the patient to try and abduct their arm, but with the examiner's hands stabilising the humerus so no movement occurs, thus minimising pain.

Radiological features

- AP gleno-humeral joint and axillary view is the best combination; however in the acute situation a Velpeau view (oblique axial view with the patient leaning backwards over the film and the arm abducted, e.g. holding an i.v. pole on the trolley) is far more useful than a lateral scapular 'guessogram'.
- Fracture line should be assessed according to Neer's classification.
- A lipo-haemarthrosis may be visible as a fat/fluid level inferior to the acromium.
- A significant haemarthrosis may displace the humeral head downwards resulting in a pseudo-subluxation – this is exacerbated by the lack of deltoid tone to minimise pain.
- Look for associated dislocation (anterior or posterior) – best seen on the axial/axillary view – look for the coracoid to orient Anterior.

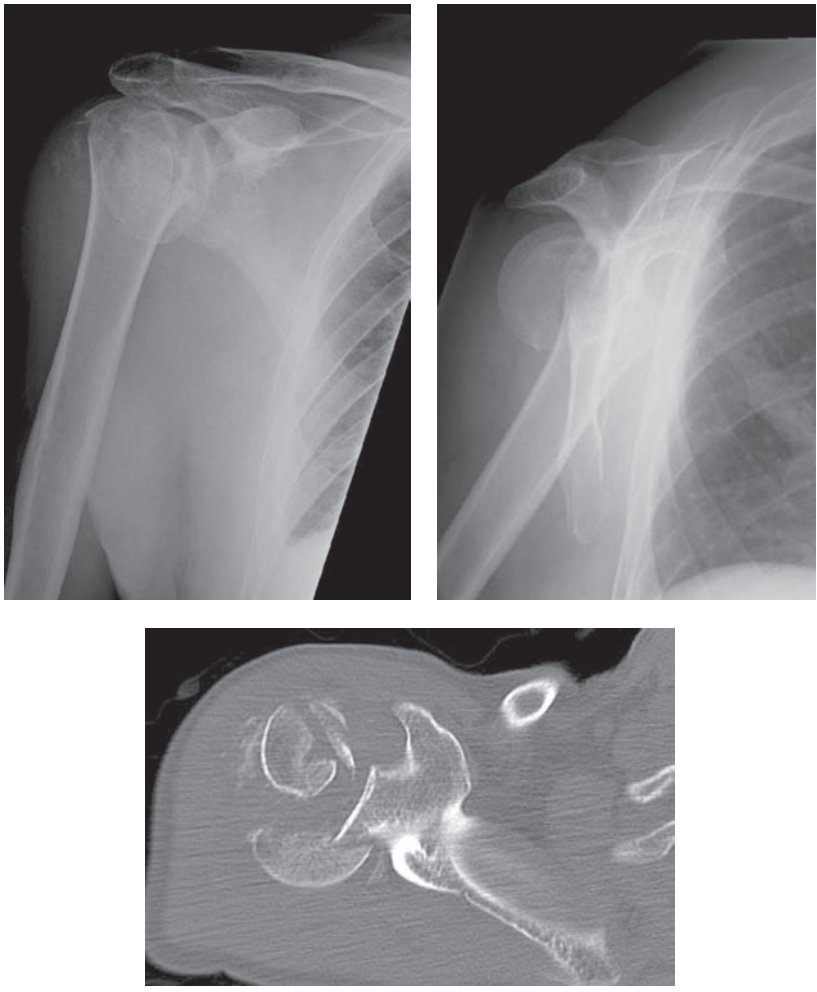
Management

- Initial treatment consists of good analgesia and immobilisation in collar and cuff, allowing gravitational correction of an angulated deformity.
- When pain allows, gravity-assisted pendular exercises should be started, followed by more active exercises once clinical union has occurred.
- One-part fractures, i.e. less than 1 cm displacement, or 45° angulation are managed non-operatively as above.



Neer's classification of proximal humeral fractures and dislocations. From: *Surgery Facts and Figures*; Greenwich Medical Media, 2000: page 345.

- Two-part fractures – often in association with GHJ dislocation – anterior with greater tuberosity (GT), and posterior with lesser tuberosity (LT).
 - *LT/GT/surgical neck* – displaced fragments require ORIF, occasionally percutaneous fixation being used for neck fractures.
- Three-part fractures:
 - ORIF with tension-band techniques often using Ethibond-type sutures. More modern plates with low-profile design allow multiple proximal screws, often with the ability to interlock to the plate thus creating a fixed-angle device. Alternatively, nailing is possible with Polarus-type short IMN with multiple proximal screw holes. In the elderly consideration of hemiarthroplasty.
- Four-part fractures:
 - ORIF in young patients but considerable AVN rate because of the fracture pattern jeopardising the major humeral head blood supply.
 - Hemiarthroplasty in the elderly population.
 - Head-splitting fractures incur an even higher risk of AVN, but again attempts at ORIF are probably indicated in the young patient.
- Associated acute GHJ dislocations should be reduced as soon as possible and the resultant fracture treated in the standard manner.



A four-part proximal humeral fracture with head split – best appreciated on the CT.

- Complications:
 - Non-union – usually treated with ORIF/and bone graft.
 - AVN of the humeral head – related to severity of fracture and surgical trauma of ORIF – the major humeral head blood supply is from the anterior circumflex humeral artery which is vulnerable at the surgical neck.

Humerus fracture – shaft fractures

Characteristics

- Usually direct trauma, sometimes with a fall, or twisting motion, on an outstretched hand.
- Occasionally reported after strenuous exercise caused by violent muscle contraction, e.g. arm-wrestling.
- If fracture occurs above pectoralis major, the proximal fragment abducts. If between pectoralis major and deltoid, the proximal fragment will adduct. If distal to deltoid insertion, the proximal fragment will abduct.

Clinical features

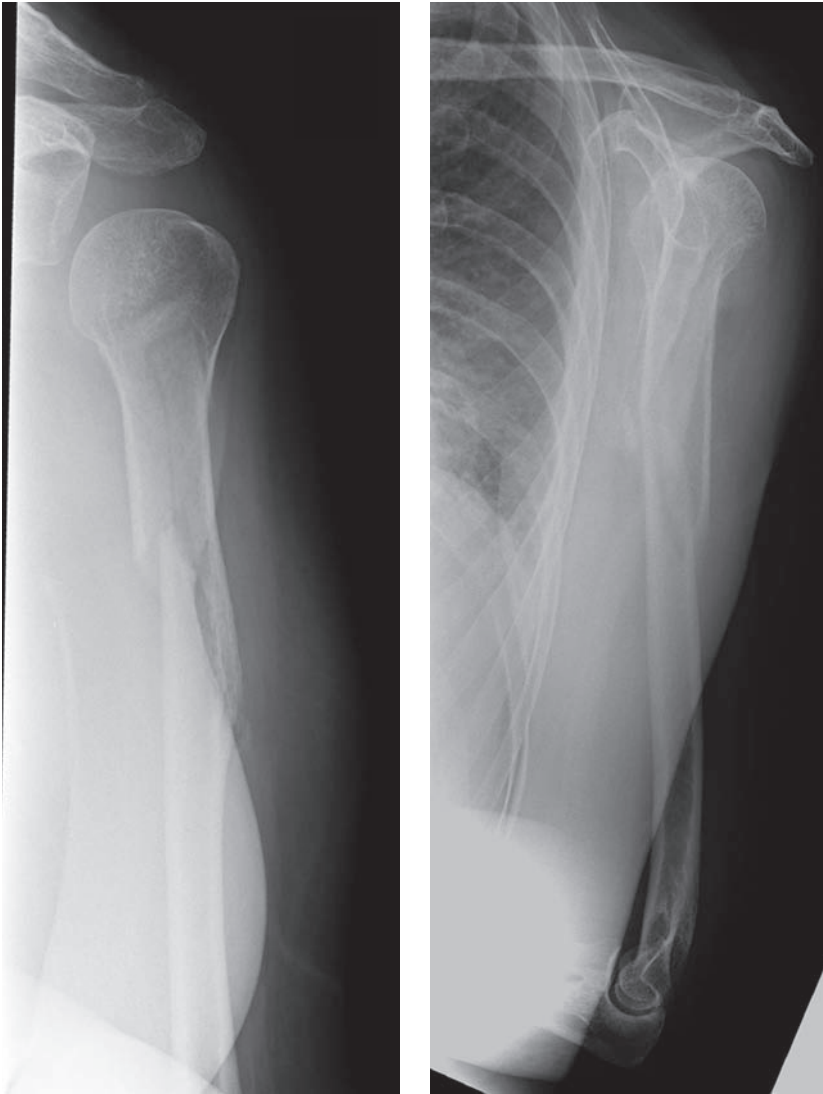
- Pain, bruising, shortening, rotation and angulation are often present.
- The arm is usually supported by the contralateral arm.
- Fracture crepitus is common with complete fractures.
- Suspect radial-nerve damage (Holstein-Lewis fracture = spiral distal third humeral fracture) if wrist-drop or sensory impairment in the first web space dorsally.

Radiological features

- An AP and lateral to include elbow and glenohumeral joints are essential.
- Incomplete fractures can be subtle. Look for cortical breaks at the site of maximal tenderness.
- Look for pathological lesions – particularly in low-energy trauma.

Management

- ABCs, analgesia and immobilise – plaster U-slab or just collar and cuff.
- Most closed fractures are best treated non-operatively, exchanging the U-slab as soon as possible (3–14 days) for a functional Sarmiento-type brace.
- The functional brace relies on compression to maintain intra-compartmental pressure to align the fragment ends, and active elbow flexion–extension.
- A hanging cast is rarely needed, but is worth remembering for grossly displaced or comminuted fractures. The patient must remain upright or gravity will produce extension at the fracture site in the supine/semi-recumbent position.
- Careful, weekly follow-up initially.
- Indications for operative treatment include:
 - Open injury.
 - Neurovascular damage.
 - Pathological fracture.
 - Segmental fracture.
 - Multiple trauma – and bilateral humeral fractures.
 - Floating elbow.



Multifragmentary fracture of the middle third of the humeral shaft.

- Failure of non-operative treatment, e.g. loss of position, often in a patient of raised Body Mass Index, or in the management of non-union with bone grafting.
- Methods of operative intervention:
 - ORIF – plate fixation.
 - IMN – antegrade (or retrograde) locked nails, flexible nails in children.
 - External fixation – usually temporary for open injuries.

Humerus fracture – supracondylar fractures – paediatric

Characteristics

- Occur in the distal humerus, proximal to the epicondyles.
- Peak incidence 5–8 years of age. Commoner in boys and left > right!
- Usually secondary to a fall on an outstretched hand.
- Classified as an extension (90%) or flexion (10%) fracture depending on the angulation/displacement of the distal fragment – capitellum is angled 45° anterior in normal anatomy.
- Majority are of the extension type – classified by Gartland as:
 - I Undisplaced.
 - II Displaced – hinged posterior cortex.
 - III Completely displaced.

Clinical features

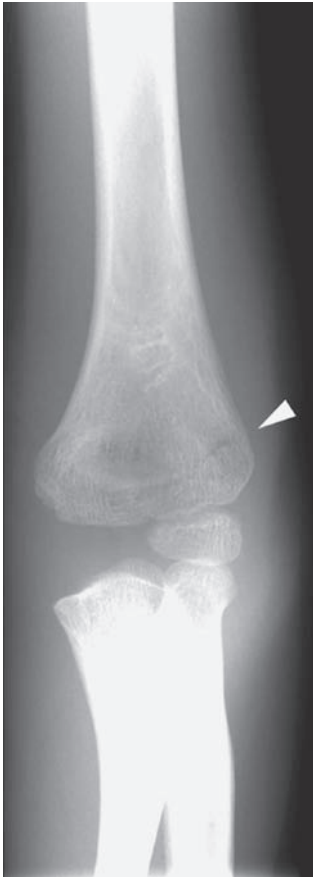- Suspect from the history.
- The child will complain of pain and be reluctant to move the arm.
- Obvious deformity and bruising may be present.
- Unlike a dislocation, the relationship between the olecranon, medial epicondyle, and lateral epicondyle will be preserved.
- The brachial artery is at risk from the proximal fragment – assess the pulse.
- All nerves around the elbow can be damaged by supracondylar fractures and their treatment – 7%–15% of supracondylar fractures have neurological injury – radial > median > ulnar nerves.

Radiological features

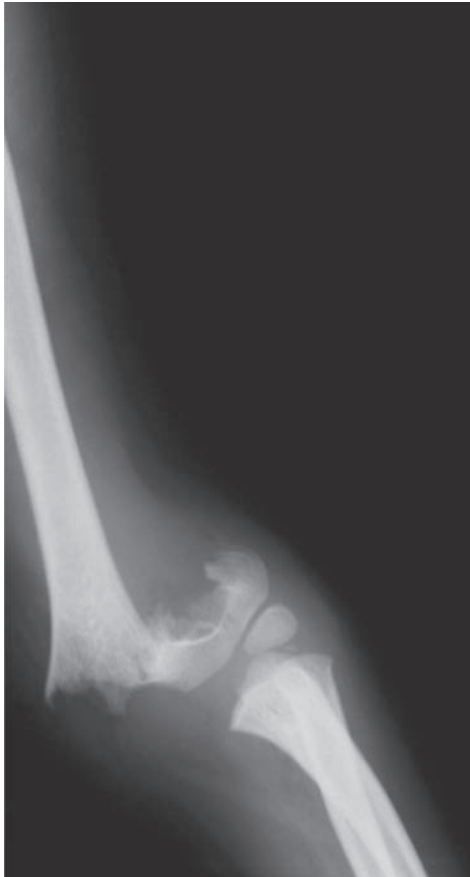
- AP and lateral view of the elbow.
- Often only a subtle fracture line will be seen – possibly with some overlap.
- Look for the presence of a posterior fat pad, prominent anterior fat pad or disruption of the anterior humeral line. **The anterior humeral line normally passes through the middle third of the capitellum on a lateral elbow X-ray.**
- Beware the normal epiphyseal appearance in the child. In general, the ossification centres typically appear as follows (≈ every 2 years): – Capitellum – 1 yr, Radial head – 3 yrs, medial (Internal) epicondyle – 5 yrs, Trochlea – 7 yrs, Olecranon – 9 yrs, Lateral epicondyle – 11 yrs. (CRITOL 1, 3, 5, 7, 9, 11 years)

Management

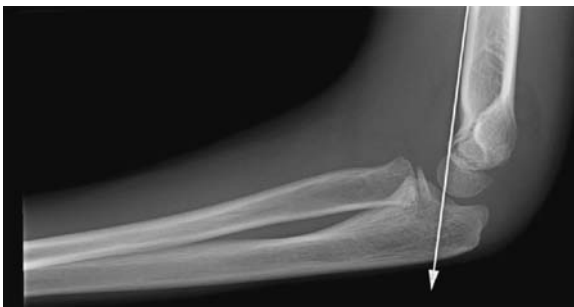- ABCs, careful neurovascular assessment, POP backslab.
- With non-displaced fractures, immobilise in a splint or cast flexed at 90 degrees.
- Manipulation ± open reduction and crossed k-wire fixation for the displaced (Gartland II and III fractures). Some authors suggest straight arm traction for unreducible displaced fractures.
- Exploration of any injured nerves not showing signs of recovery.



Undisplaced supracondylar fracture.



“Off-ended” supracondylar fracture.



Supracondylar fracture (lateral view). The anterior humeral line passes through the anterior third of the capitellum due to dorsal displacement of the capitellum secondary to the fracture. Note the associated significant joint effusion.

Radius fracture – head of radius fractures

Characteristics

- Typically force transmitted along the radius with a fall onto out-stretched hand.
- Capitellum and collateral ligament injuries common.
- Classified by Mason
 - I undisplaced.
 - II displaced.
 - III comminution/joint depression.
 - IV (added later for radial neck fractures).

Clinical features

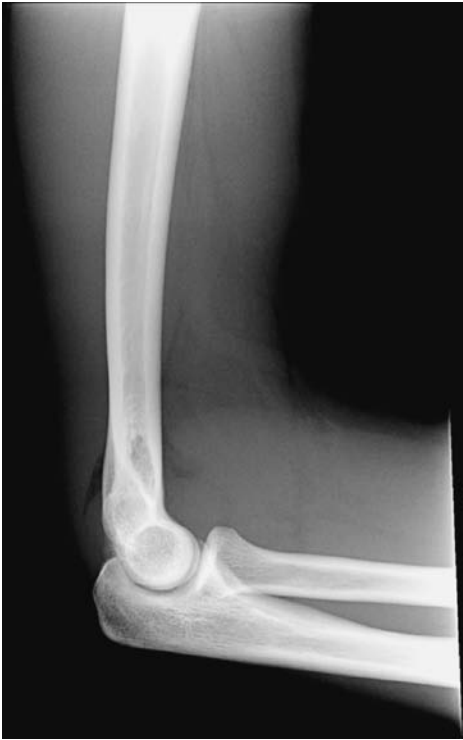- Painful elbow with localised radial-head tenderness.
- Decreased pronation/supination.
- Limited elbow flexion and particularly extension.

Radiological features

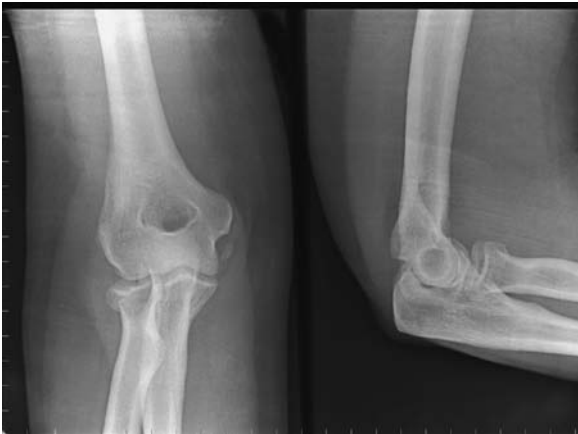- Often, the fracture line will be difficult to identify – trace out the radial head and its relationship to the capitellum.
- Suspect if history suggestive and joint effusion (displaced anterior or visible posterior fat pad).
- An easily seen comminuted or significantly displaced radial-head fracture is uncommon.

Management

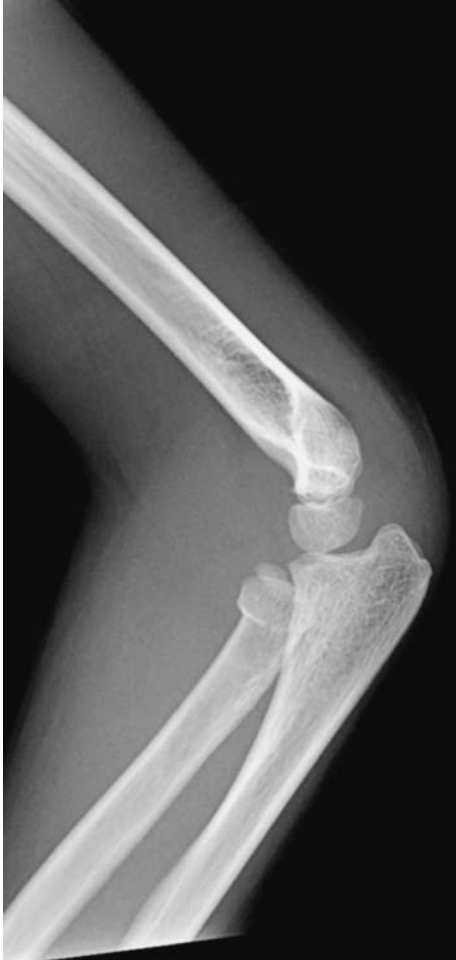- Analgesia, immobilisation and ice initially.
- Undisplaced fractures are best managed non-operatively.
- If the patient has a good range of pronation/supination then a collar and cuff is helpful for 10–14 days followed by physiotherapy.
- If pronation/supination are significantly reduced, then aspiration of haemarthrosis, and instillation of local anaesthetic is a useful technique to improve pain relief and allow early mobilisation so that the radial head ‘remoulds’ on the capitellum.
- For significantly displaced fractures (Mason II) ORIF with cannulated intra-articular screws should be considered.
- For grossly comminuted and depressed fractures (Mason III) ORIF may be possible but radial-head replacement is more likely – there has been a trend away from radial-head excision for such fractures because of delayed distal radio-ulnar joint pain. However, there is also an incidence of elbow pain after radial-head replacement requiring removal of the prosthesis.



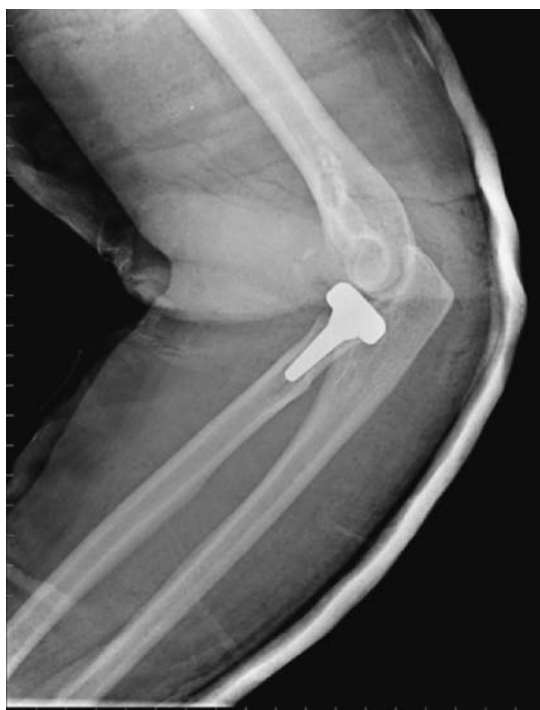Large post-traumatic joint effusion (elevated anterior and posterior fat pads). No fracture is visible, but there is a high probability of an occult fracture.



Intra-articular fracture of the radial head and radial neck fracture. Note the slight depression in the articular surface of the radial head and the associated effusion.



Radial head fracture in a child.



Prosthetic radial head seen *in situ*.

Radius fracture – shaft fractures

Characteristics

- Fall on out-stretched hand or direct trauma.
- May be in isolation or with associated ulna fracture, or with dislocation of the distal radio-ulnar joint – Galeazzi pattern – see below.
- Seen in both the adult and paediatric population.

Clinical features

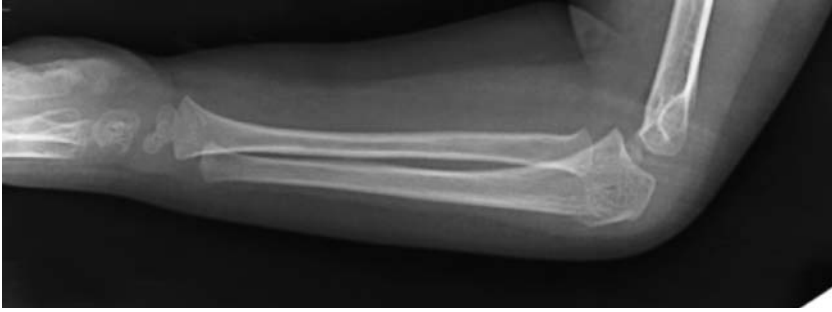- Pain, deformity, swelling, bruising and crepitus.
- Possible associated distal (Galeazzi) or proximal joint subluxation.
- Neurovascular injury possible.
- Compartment syndrome possible – look at passive stretching of dorsal and volar compartments.

Radiological features

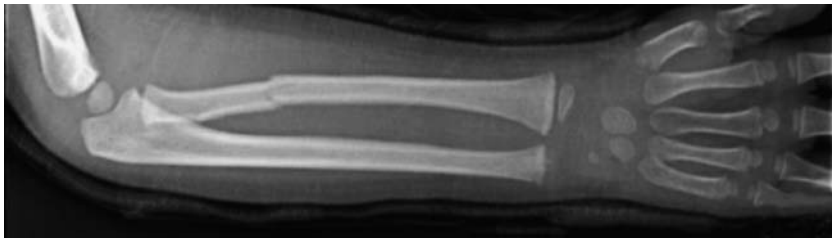
- AP and lateral views – including the joints above and below should suffice.
- Displaced fractures have $>10^\circ$ angulation (risking future pronation/supination), or $>50\%$ displacement.

Management

- ABCs, analgesia, immobilisation with above-elbow backslab initially.
- Undisplaced fractures are treated non-operatively with closure of the backslab at approximately 7 days when the swelling has subsided, and changing to short arm cast at approximately 4 weeks until union.
- Displaced fractures require ORIF with a compression plate.
- In children MUA \pm flexible ‘Nancy’ intramedullary nails should be performed.



Undisplaced fracture of the proximal third of the left radius.



Undisplaced right radial fracture, at the junction of proximal and middle thirds.



Galeazzi fracture dislocation

Characteristics

- Defined as a fracture of the radius with associated dislocation of the distal radio-ulnar joint.
- Relatively rare fracture occurring in approximately 1 in 14 forearm fractures.
- Occurs in falls onto the outstretched extended hand in which the forearm is forcibly pronated.
- As with Monteggia fractures, it may occur secondary to a direct blow.

Clinical features

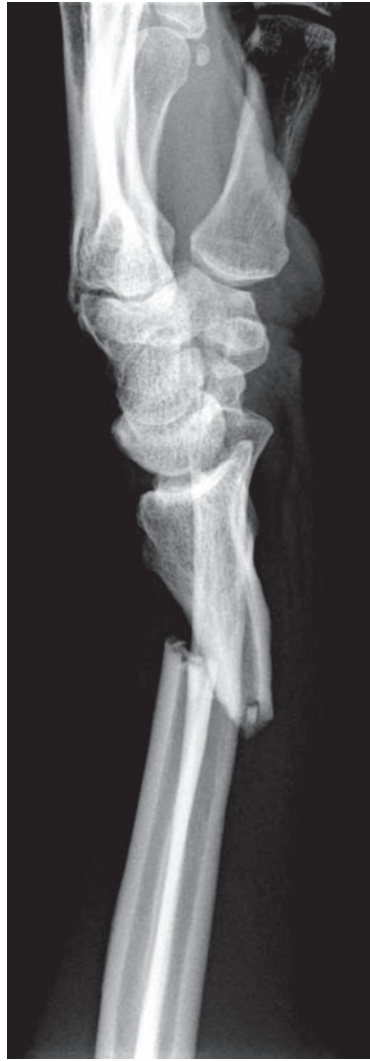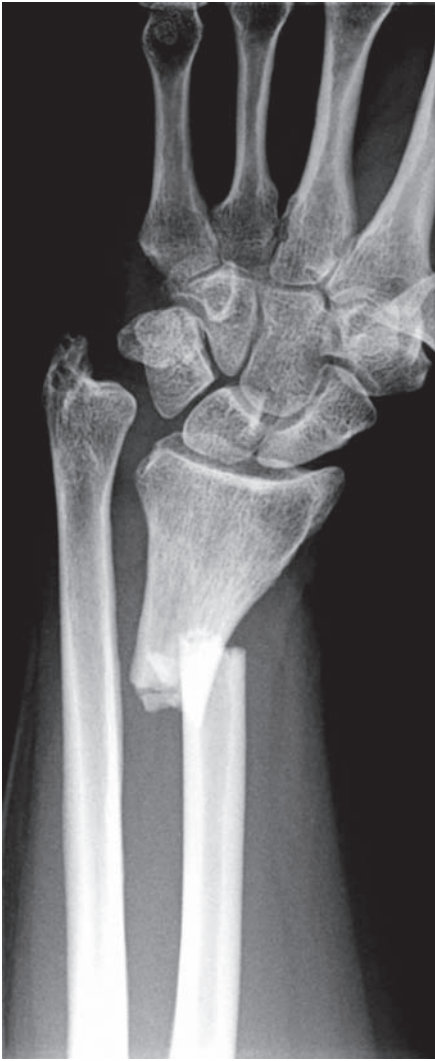- The patient will complain of pain and be reluctant to move the forearm or wrist.
- Obvious deformity at the site of radial fracture may be apparent.
- Tenderness \pm fracture crepitus along the distal radius will be present.
- On comparison with the unaffected side, the ulnar head will be prominent with associated soft-tissue swelling.

Radiological features

- Obtain AP and true lateral views of the forearm including the wrist.
- The radius will commonly be fractured at the junction of middle and distal thirds.
- The radius will often appear shortened.
- Carefully assess the distal radioulnar joint (DRUJ) for widening.
- On the lateral view, the head of the ulna will be displaced dorsally.
- Dorsal angulation of the distal radial fragment (apex volar) most likely.
- Ulna styloid fractures are common and act as a marker for distal radio-ulnar joint disruption.
- A useful way of remembering this type of forearm fracture is with the acronym '**GFR**' – **G**aleazzi **F**ractured **R**adius.

Management

- ABCs, analgesia and immobilisation initially.
- In adults likely to require ORIF of the radial fracture, which normally corrects the DRUJ abnormality.
- In children, closed reduction under GA will usually suffice, but careful follow up with true lateral radiographs of the wrist are required.
- With late missed injuries, the DRUJ needs stabilisation – such as the Suave-Kapandji procedure – distal ulna osteotomy, partial ulna excision and arthrodesis of the ulnar styloid to the distal radius.



Galeazzi fracture.



Radius fracture – distal radial fractures

Colles' fracture

Characteristics

- Originally described in 1814 and is the commonest adult wrist fracture.
- Fall onto outstretched hand commonest cause.
- Mainly seen in middle aged to elderly females with osteoporosis.
- Classically a transverse fracture within 2 cm of the articular surface, with dorsoradial angulation and displacement. The fracture is impacted and often associated with an ulnar styloid fracture.
- Currently used classifications include:
 - Frykmann – (I–VIII) according to radiocarpal/ulnar joint involvement.
 - Melone – (I–V) according to the intra-articular fracture fragment orientation.
 - AO – universal: A = extra-articular, B = partially articular, C = complex articular.
 - Fernandez – (I–V) according to the mechanism of injury.

Clinical features

- The patient will complain of pain at the wrist.
- Classically a 'dinner fork' deformity is seen.
- Marked swelling with associated bruising common.
- May be an open injury.
- Neurovascular deficit – median nerve neurapraxia most common.

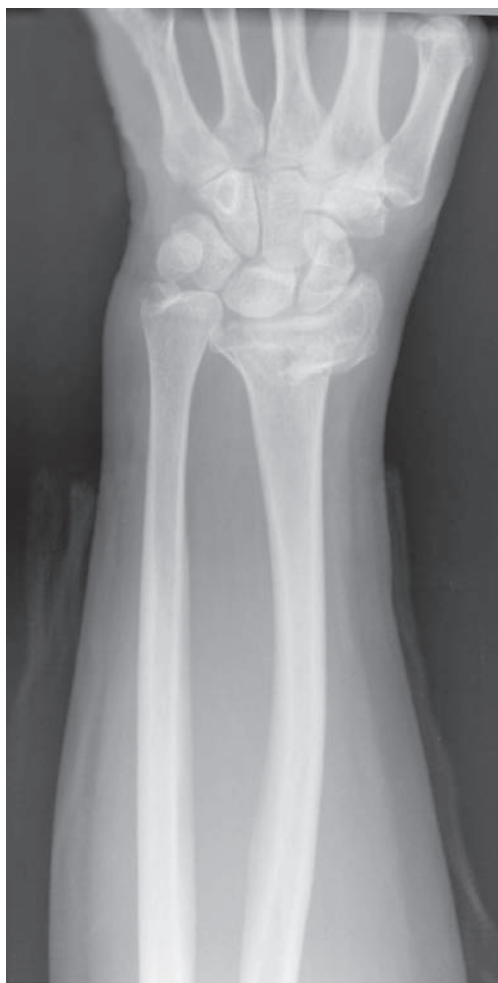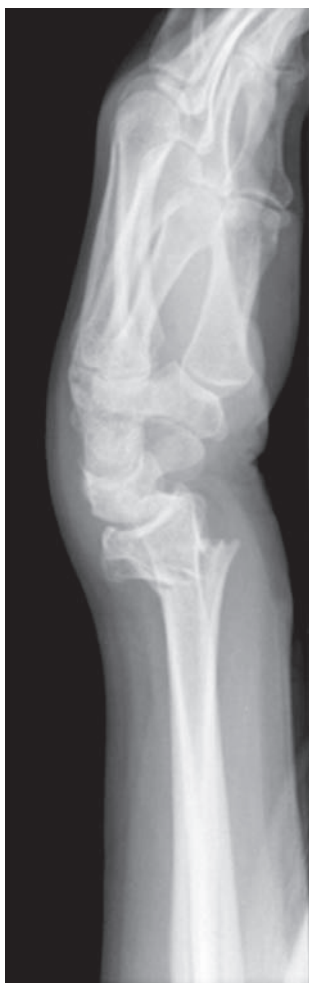Radiological features

- AP and lateral views essential – ideally radio-carpal views (slight elevation of the hand off the film, allows for the distal radial inclination (23°) and the volar tilt (11°)).
- The five commonly seen deformities are:
 1. Dorsal angulation (loss of the normal 11° volar tilt) of the distal radial articulation.
 2. Dorsal displacement of the distal fragment.
 3. Impaction – with loss of radial length – normally 12 mm distal to ulnar styloid.
 4. Radial displacement of the distal fragment.
 5. Radial tilt of the distal fragment into radial angulation.
- The pronator quadratus fat pad will be elevated.

Management

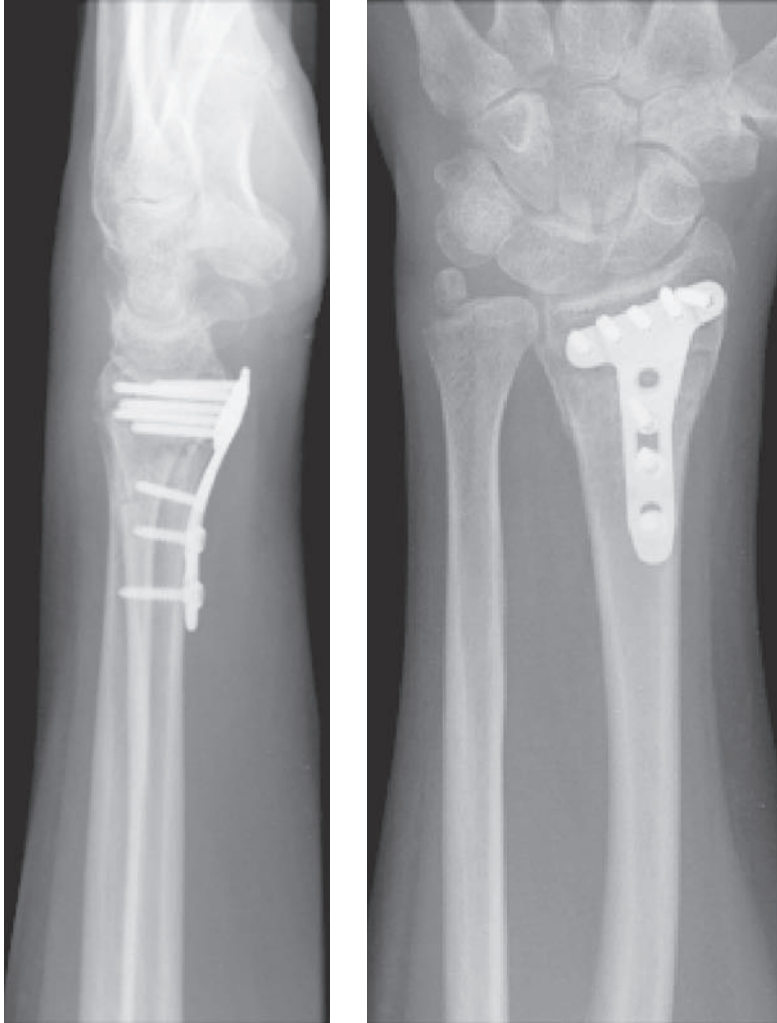
- Analgesia, assess neurovascular and open or closed status and then immobilise.

- Reduction is generally indicated if there is marked radial angulation or dorsal tilt greater than 10° .
- Reduction should be performed as early as possible by suitably experienced personnel – usually within the Emergency Department – with either haematoma or Bier's block.
- The aim is to restore length and correct the dorsal angulation.
- Following reduction, maintain position with a backslab (dorso-radial) or split plaster.
- Repeat radiographs ideally after closure of the cast once the swelling has subsided at approximately 5–7 days.
- Loss of position, or inadequate initial reduction are indications for further manipulation and k-wiring.



Colles' fracture.

- Alternatives to k-wiring include external fixators (ideally radio-radial non-bridging) or ORIF.
- Particular advances in plate technology (such as the volar locking plate) allow the stabilisation of dorsal fragments from the volar approach – this may promote more aggressive management of the distal radial fracture.



Post-ORIF of Colles' fracture using a locking volar plate.

Related wrist fractures

Smith's fracture

- Often described as a reverse Colles' fracture.
- AP and lateral views essential as may appear similar to Colles' fracture if an AP view alone is examined.
- Transverse fracture through the distal radius metaphysis with associated volar angulation and volar shift.
- Look for median nerve symptoms.
- Most Smith's fractures are treated with volar buttress plating and early mobilisation.

Barton's fracture

- The fracture line is *intra-articular* and runs obliquely as compared to the transverse fracture seen in Smith's type.
- Originally described as two types: dorsal and volar Barton's,
- Today the label of 'Barton's fracture' tends to be reserved for a fracture involving the volar distal radius with subluxation of the wrist and distal radio-ulnar joint.
- Tends to occur following high-velocity impact injuries.
- AP and lateral views required. Carpal displacement best seen on the lateral views.
- Treatment is with ORIF using volar buttress plating and early mobilisation.

Chauffeur's (Hutchinson) fracture

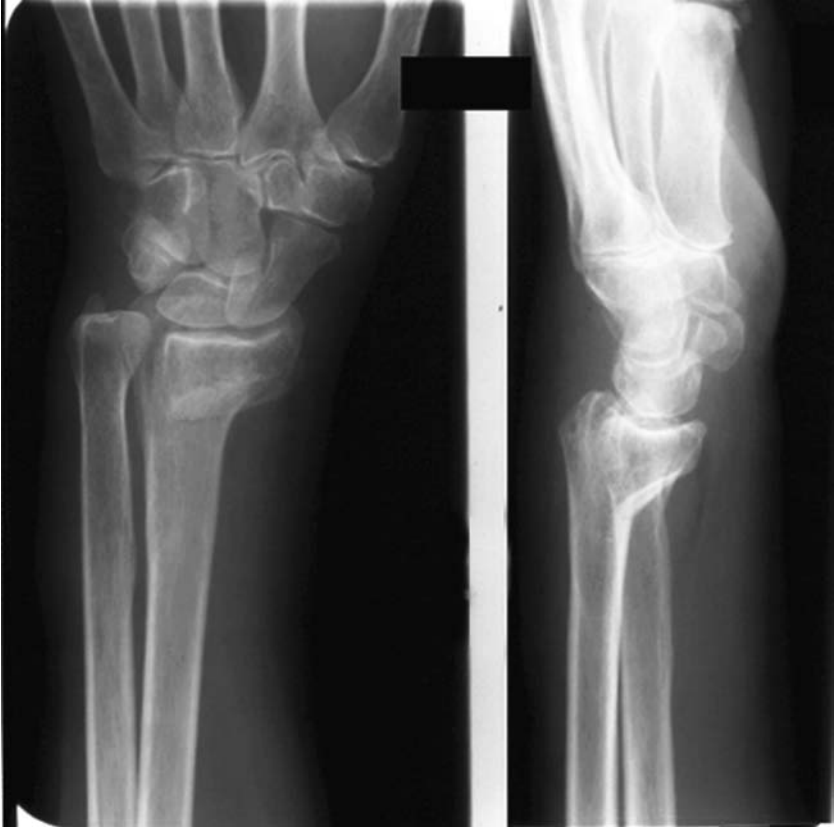- Intra-articular fracture of the radial styloid.
- Usually secondary to a direct blow to the ulnar aspect of wrist.
- Best seen on the AP view.
- Treated with MUA and k-wire, percutaneous screw or ORIF.

Greenstick fracture

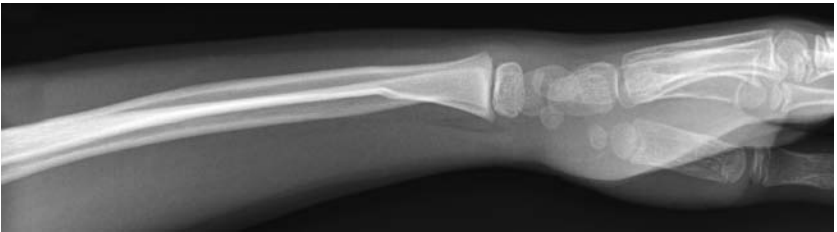- Incomplete metaphyseal fractures seen as disruption of the cortex on one side with angulation or bowing on the opposite.
- If angulated such that a clinical deformity exists this may require reduction and immobilisation; this depends on the child's age/remodelling potential and the surgeon's and parents' preferences. Most greenstick deformities will remodel but they take time and much parental anxiety can be avoided with a simple manipulation at the outset.

Physeal injuries – see Salter–Harris classification under peri-physeal injury

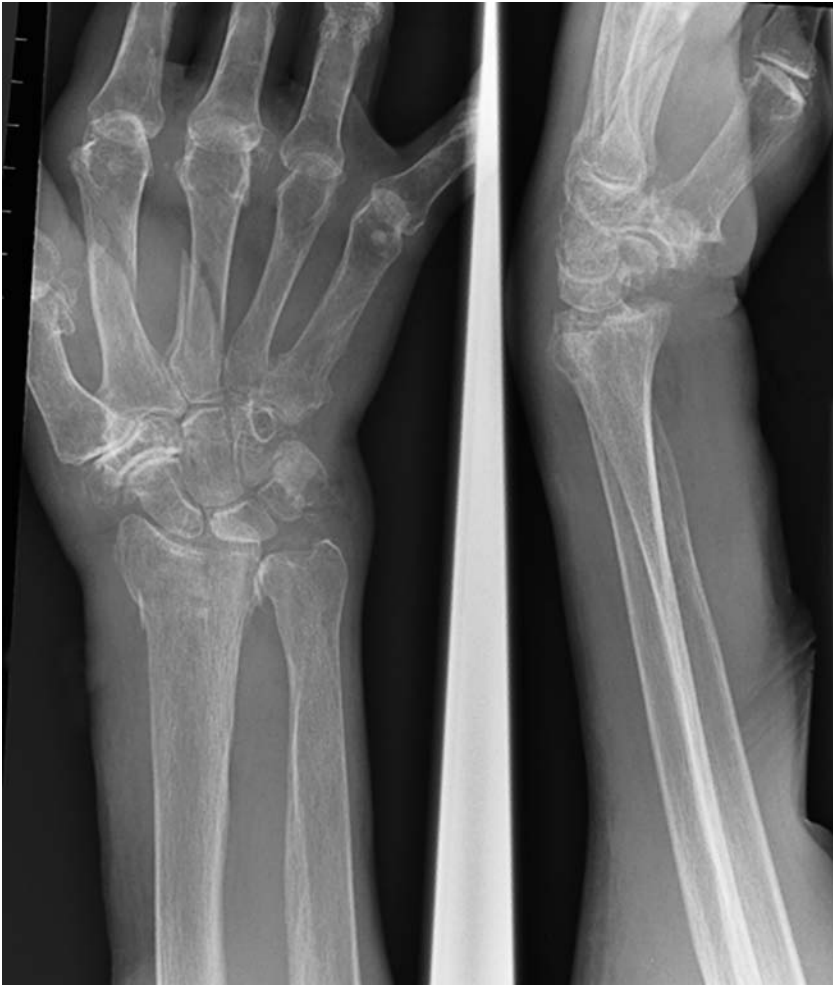- Salter–Harris II injuries of the distal radius are the juvenile Colles' fracture.
- Most are managed non-operatively and remodel – the physis not being damaged as the zone of fracture does not affect the vascularity of the growth plate.
- With significant displacement/angulation, or with median-nerve symptoms these need a manipulation and plaster under general anaesthetic.



Smith's type fracture.



Greenstick fracture of the right radius.



Intra-articular fracture of the distal radius.

Scaphoid fracture

Characteristics

- Commonest carpal fracture accounting for roughly 60% of all carpal fractures.
- Seen in young adults (M > F) following a fall onto out-stretched hand, particularly with radial and dorsal angulation of the wrist.
- Classified according to site:
 - A tuberosity and distal pole.
 - B waist.
 - C proximal pole.
- Fractures through the waist of scaphoid are by far the commonest.
- The major scaphoid blood supply enters distally and thus in waist fractures, vascularity may be compromised risking proximal fragment AVN.

Clinical features

- The patient will complain of pain (wrist/hand) with limitation of wrist movement.
- Examine for tenderness in the anatomical snuff box, over scaphoid tubercle (volar – base of thenar eminence), axial compression of thumb/telescoping, resisted supination of the wrist and thumb movement, particularly opposition.
- Tenderness may be due to a fracture of an adjacent structure such as base of thumb metacarpal, trapezium or radial styloid.

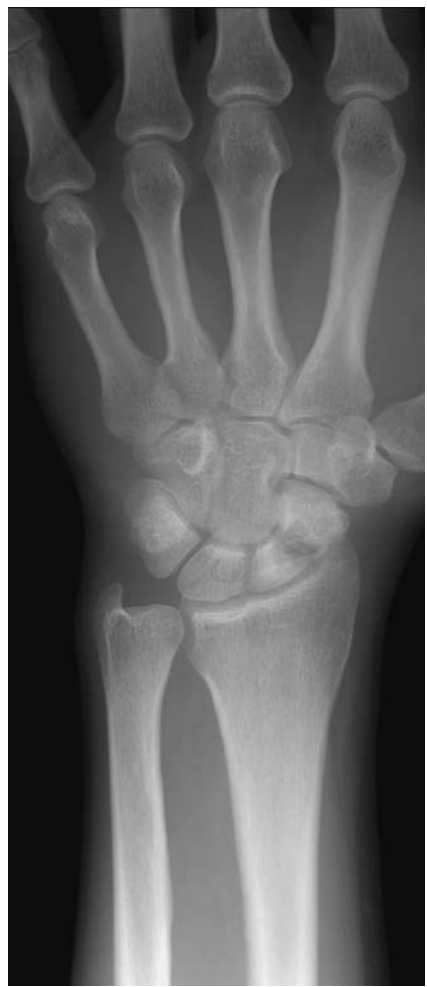Radiological features

- PA, lateral and oblique carpal views centred on the scaphoid (or simply request 'scaphoid views').
- The fracture is often difficult to see and hence the concept of the 'clinical scaphoid fracture' or occult fracture.
- Repeat X-ray at 2 weeks, acute MRI, CT and bone scans have all been used for diagnosis of occult fractures.
- Beware accessory ossicles as these may be mistaken for fractures. An os centrale may be seen adjacent to the distal pole and may be small, large or double.
- 'Bi-partite' scaphoid probably represents an old un-united injury. These are best differentiated from acute fractures by the rounded smooth surfaces of adjacent fragments on radiographs or by CT/MRI scanning.

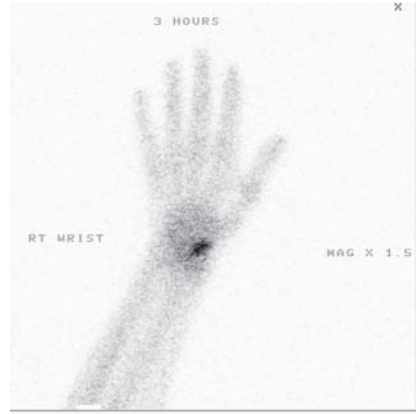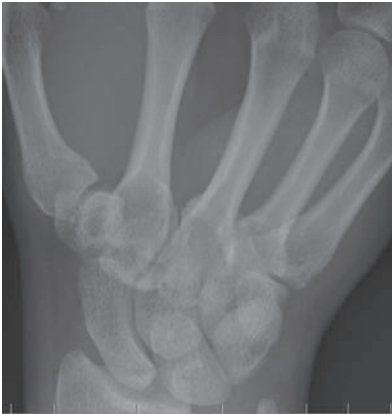Management

- Assess soft tissues, neurovascular status and immobilise – scaphoid cast if a fracture is seen on X-ray, or Futura splint if radiographically unproven.

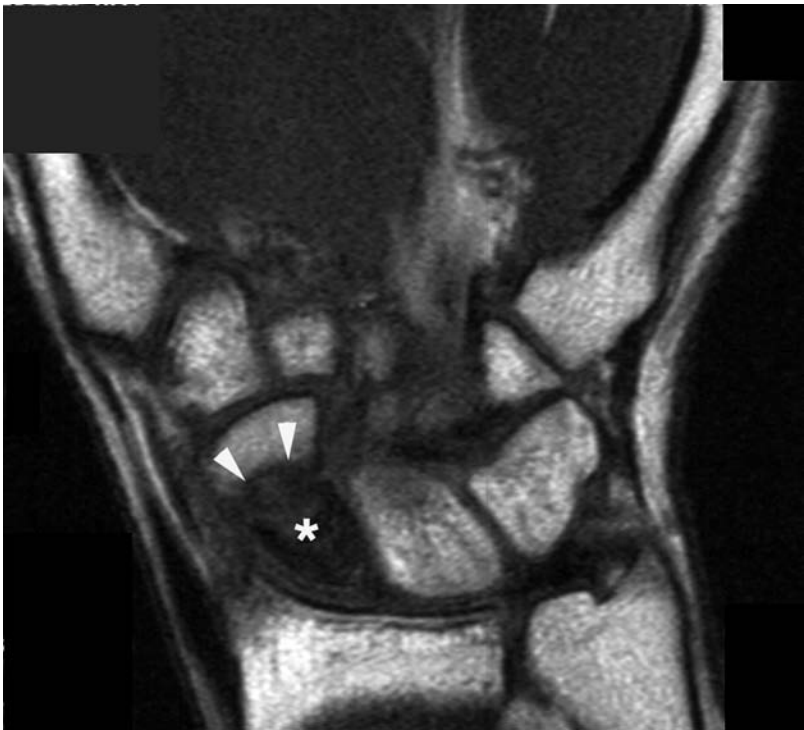- Repeat radiographs at 2 weeks will show some occult fractures, but acute MRI is the current gold standard and can also demonstrate ligamentous injury.
- Non-displaced fractures usually unite between 6 and 12 weeks, although proximal pole fractures often take longer.
- If markedly displaced, assess for carpal dislocation.
- If displacement exceeds 1 mm or angulation >15 degrees, ORIF using an intra-articular differential pitch screw, e.g. Herbert/Acutrak.
- Non-union occurs in up to 10% of undisplaced fractures and 90% of displaced proximal pole fractures. These require bone grafting, e.g. Matti–Russe inlay corticocancellous strut grafting.



Fracture through the waist of scaphoid.



Patient with post-traumatic anatomical snuff-box tenderness. Normal scaphoid view radiographs. Bone scan demonstrates focal isotope uptake over the scaphoid confirming an occult fracture.



AVN left scaphoid: coronal T1 MRI. The normal 'bright' T1 marrow signal, proximal to the fracture (arrowheads), is lost (asterisk), consistent with avascular necrosis.

Scapular fracture

Characteristics

- Uncommon as mobile and coated in muscle.
- Peak incidence 35–45 years.
- Mechanism – fall from height or high-velocity force, usually road-traffic accidents.
- Force may be direct or indirect to the scapula, being transmitted through the upper limb.
- In direct injuries think of associated chest injury (up to 50%), and for indirect trauma remember careful neurological assessment. Ipsilateral clavicle fractures occur in 25% and approximately 10% have a brachial plexus lesion.
- *Classified according to site by Zdravkovic:*
 - I – involves body or spine of scapula.
 - II – acromium or coracoid process fracture.
 - III – involves scapular neck or glenoid fossa.
- *Glenoid fractures subdivided by Ideberg:*
 - I – anterior avulsion.
 - II – transverse/oblique inferior glenoid fracture.
 - III – transverse superior fracture.
 - IV – transverse glenoid fracture which extends into the scapula body.
 - V – inferior and transverse glenoid fracture extending into the body.

Clinical features

- The alert patient will complain of pain and hold the arm adducted.
- Fracture crepitus and tenderness at the fracture site.
- May mimic a rotator cuff tear.
- In the poly-trauma patient look for associated injuries with scapular fractures.

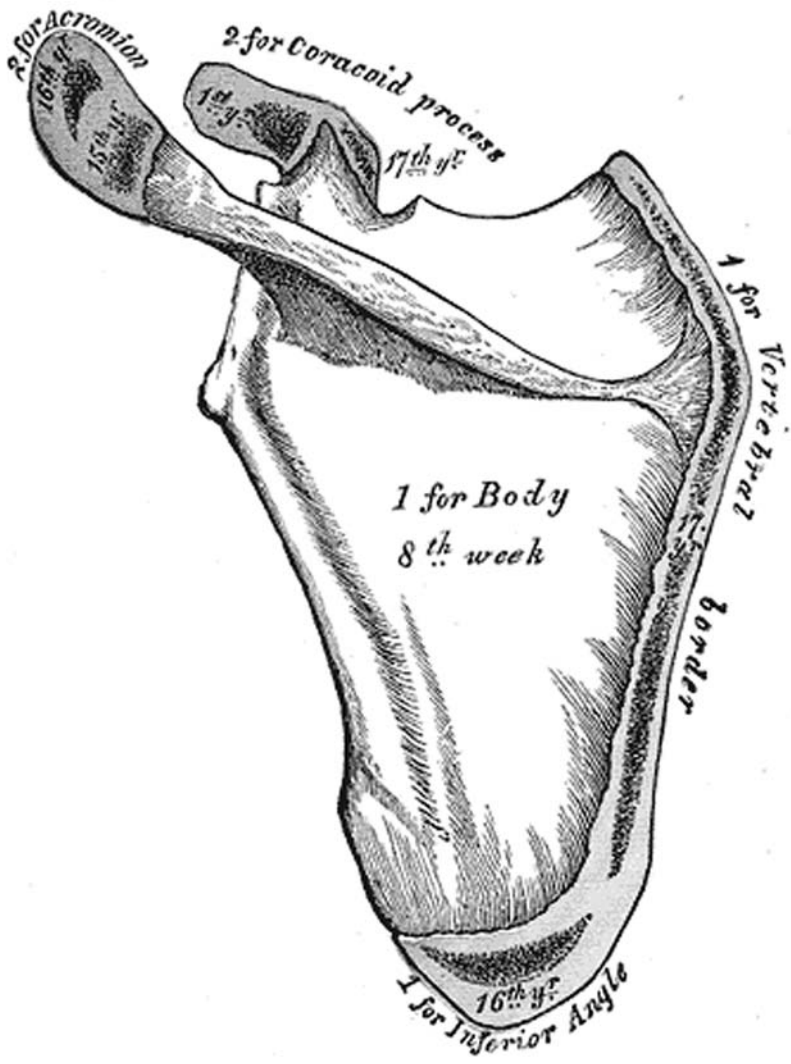
Radiological features

- An AP chest film will often show the fracture.
- AP gleno-humeral joint, lateral scapular and axillary lateral views.
- CT is useful in fractures of the scapular neck and glenoid – to assess displacement.
- **Beware ossification centres (shown below).**
- In 3% of the population an unfused acromial epiphysis (os acromiale) is seen and can be mistaken for a fracture of the acromium. Comparison of the unaffected side useful as bilateral in 60%.

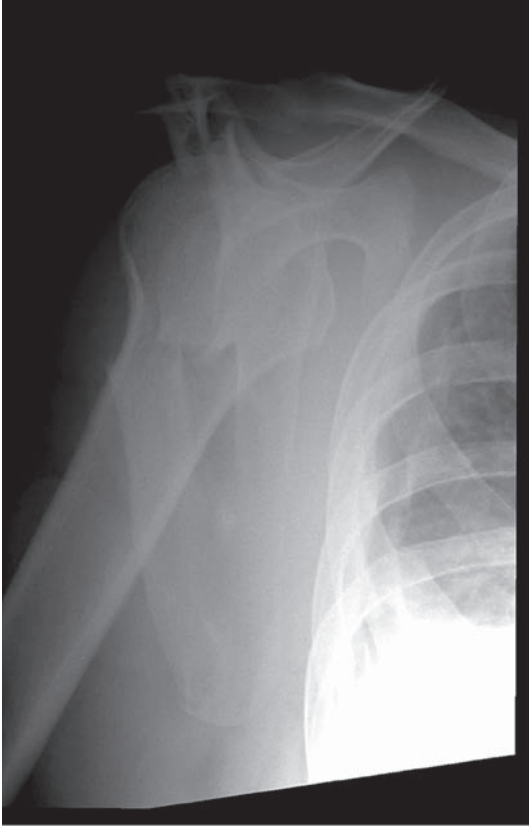Management

- ABCs, assess soft tissues, neurovascular status and immobilise.
- Most fractures of the scapular spine, body and neck do very well with non-operative treatment. Broad arm sling combined with analgesia and early mobilisation, once the acute symptoms have settled.

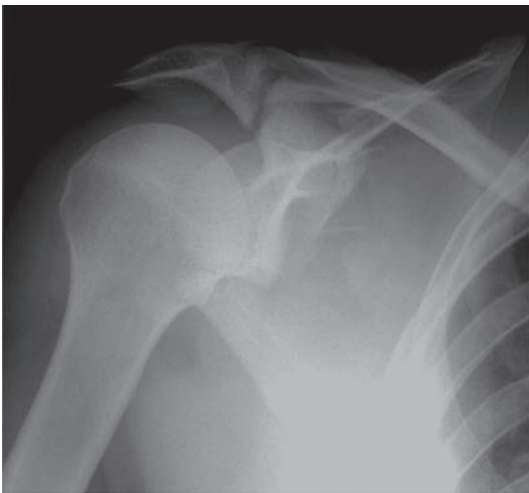- The same is true of mildly angulated scapular neck/undisplaced glenoid fractures.
- Floating shoulder (scapular neck and ipsilateral clavicle fracture) and significant glenoid displacement (>5 mm articular step or glenoid angulation $>40^\circ$), involving $>25\%$ of the glenoid surface, should be treated with ORIF for the best outcome.



The scapula is ossified from seven or more centres: one for the body, two for the coracoid process, two for the acromion, one for the vertebral border and one for the inferior angle (from Gray's Anatomy online edition).



Fracture through the scapular blade.



Complex scapular fracture with a 'floating' glenoid and fractured coracoid process.

Shoulder dislocation

Characteristics

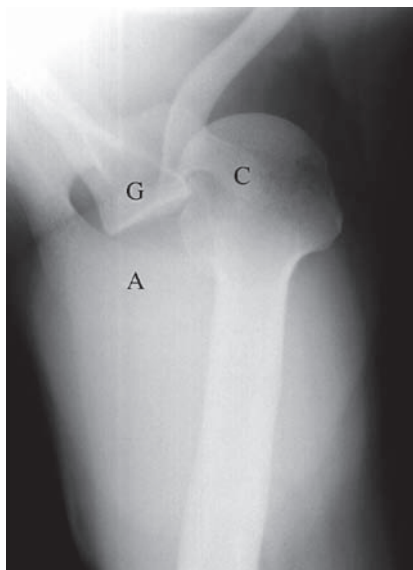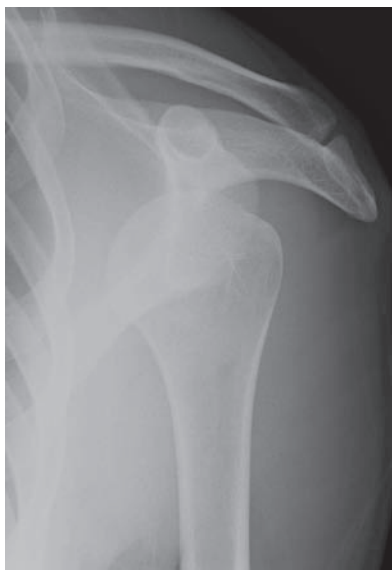- The glenohumeral joint is the commonest in the body to dislocate.
- Related to lack of bony constraint responsible for enormous range of movement.
- Bimodal age distribution of 20–35 and 60–80 years.
- Anterior, posterior and inferior dislocations in order of frequency.
- Anterior dislocation occurs secondary to fall, contact sports or RTA. The labrum detaches allowing the humeral head to dislocate antero-inferiorly.
- With posterior dislocation (5% GHJ dislocations), the head is displaced directly backwards and is usually secondary to a direct blow or fall onto an internally rotated hand. Can be missed following a difficult obstetric delivery. Posterior dislocations are also more common in epileptic fits.

Clinical features

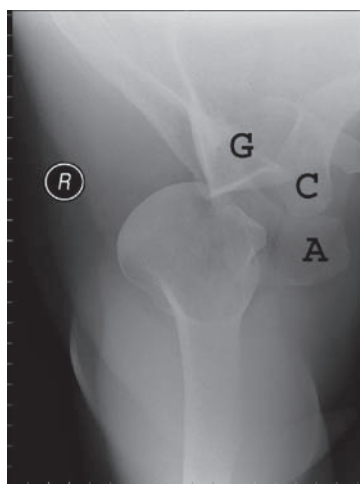
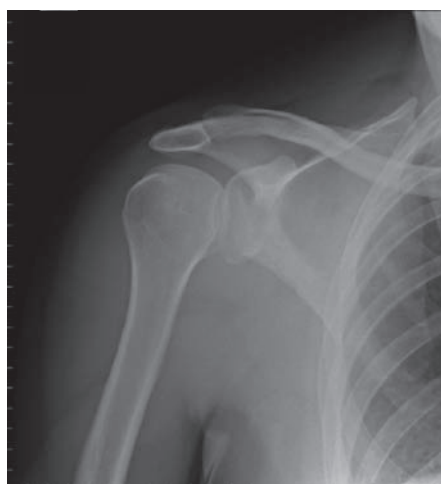- Pain, deformity and reluctance to move the arm. The arm is often stabilised at the elbow by the patient.
- Vascular injury to the axillary artery is possible with anterior dislocation, particularly in the elderly.
- Axillary nerve palsy is the commonest neurological injury (5%–30% GHJ dislocations) and thus assessment of the ‘regimental badge’ area and isometric deltoid contraction is essential.
- Distinguish two main groups in the young:
 - TUBS = **T**raumatic, **U**nidirectional, **B**ankart, **S**urgery.
 - AMBRII = **A**traumatic, **M**ultidirectional, **B**ilateral, mostly treated with **R**ehabilitation, surgery includes **I**nferior capsular shift and rotator **I**nterval capsular reconstruction.

Radiological features

- *Anterior.*
 - AP glenohumeral and modified axial (Velpeau) view should be obtained. Lateral scapular views are difficult to interpret.
 - Greater tuberosity and inferior glenoid (bony Bankart) fractures should be considered.
 - Hill–Sachs lesion – a depression of the posterolateral aspect of humeral head common with recurrent dislocation, where the head hits the glenoid as it sublucates anteriorly.
 - Bankart lesion – anterior glenoid labrum defect best seen on MRI arthrogram.
 - Loss of the ‘Shenton’s line’ of the shoulder = medial humeral and inferior glenoid cortical line.



Anterior dislocation of the shoulder. Axial view confirms the anterior position of the humeral head. A: Acromion process, G: Glenoid fossa, C: Coracoid process.



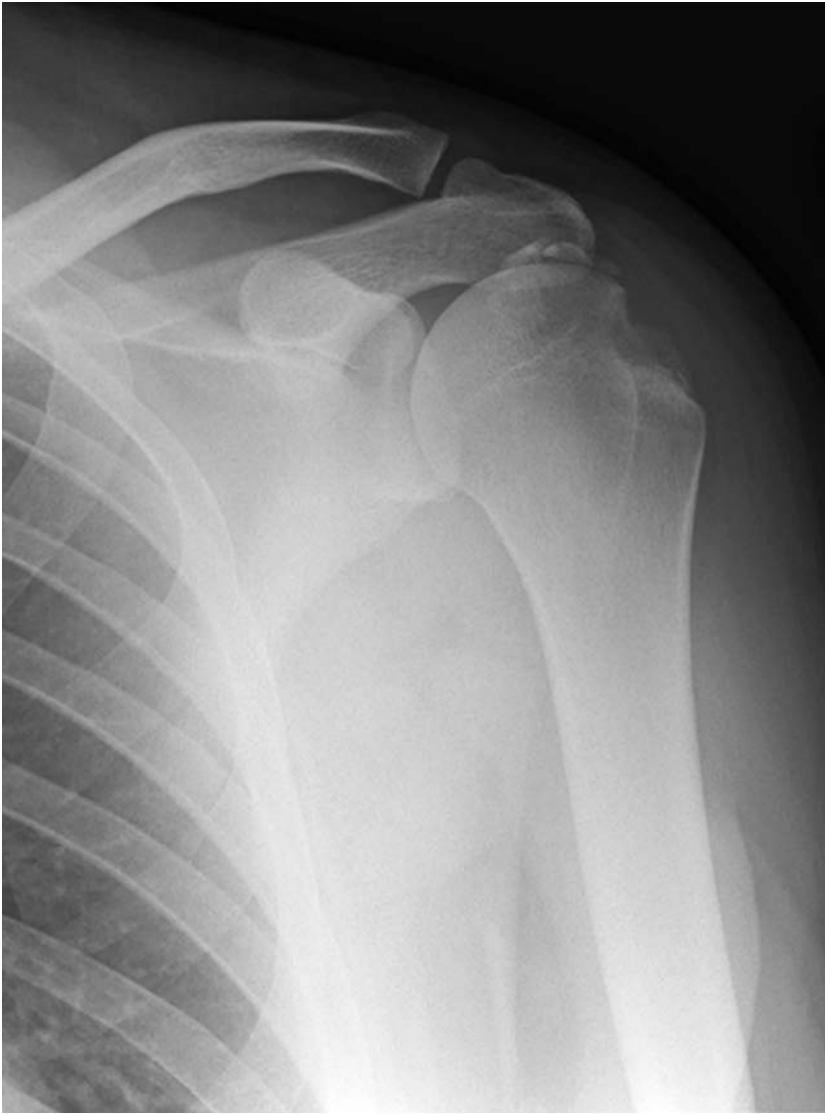Posterior dislocation on the shoulder. The axial view confirms the posterior position of the humeral head.

- *Posterior.*
 - Best seen on the axillary view.
 - 'Light-bulb' sign on AP view and widened gleno-humeral space (>6 mm).
 - The scapulohumeral arch may have an abnormally sharp angle.

- *Trough sign* – an associated compression fracture of the antero-medial humeral surface, known as a reverse Hill–Sachs lesion – seen as a sclerotic line parallel to the articular surface.

Management

- ABCs, assess soft tissues, neurovascular status, reduce and immobilise.
- Position of immobilisation is contentious – ‘gun slinger’ braces try to hold the shoulder in external rotation so that the labrum is held back down onto its bed on the anterior glenoid. Compliance can be a problem as even temporary loss of external rotation allows the labrum to separate from its bed.
- *Anterior* – careful gentle reduction under sedation with analgesia. Kocher’s, Hippocratic or modified Stimson (gravitational pull with load on flexed arm with prone patient) methods useful. Failure to reduce under sedation is an indication for GA. Check radiographs, neurovascular status and short-term immobilisation.
- Early mobilisation with physiotherapy supervision does not increase recurrence rates, although the outcome of external rotation immobilisation is still awaited.
- In the elderly early mobilisation forms the majority of treatment.
- In the young patient group, distinguishing between TUBS and AMBRII:
 - TUBS are very likely to require reconstruction with open/arthroscopic Bankart repair \pm capsular shift.
 - AMBRII group generally respond to prolonged physiotherapy.



Hill–Sachs lesion of the humeral head, with associated calcification of the rotator-cuff tendon.



Ulna fracture – proximal and olecranon fractures

Characteristics

- Usually secondary to a fall on an outstretched hand or a direct blow.
- Less commonly caused by triceps contraction with a flexed elbow.
- Extra-articular avulsion fractures less common than intra-articular ‘true’ olecranon fractures.
- Undisplaced fractures are defined (Colton) as having <2 mm displacement, active flexion to 90° and active extension.

Clinical features

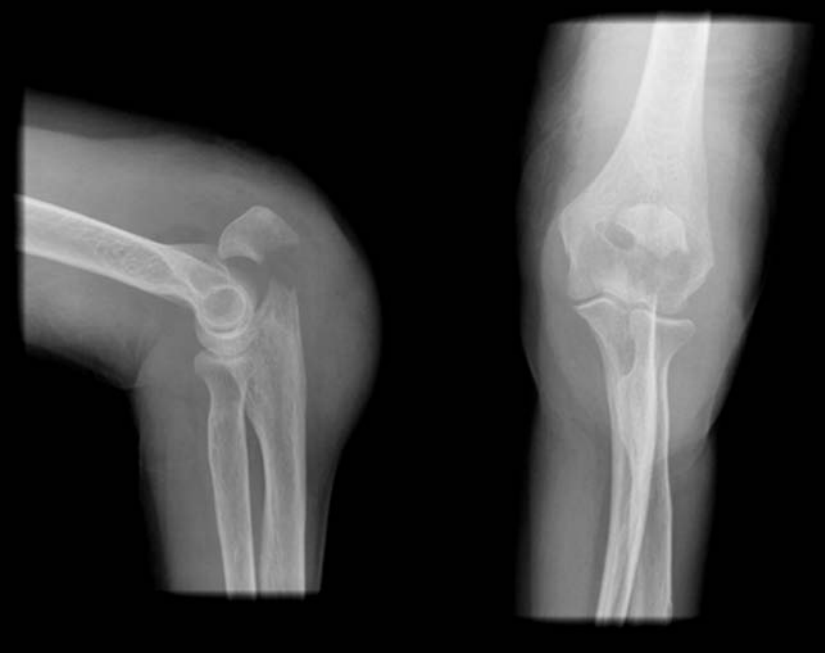- Localised pain, bruising crepitus over the olecranon.
- A palpable separation may be felt.
- Inability to extend the elbow against gravity indicates complete disruption of the extensor mechanism.
- Assess ulna and anterior interosseous nerve function as injury can occur at the time of trauma and in treatment with ORIF.

Radiological features

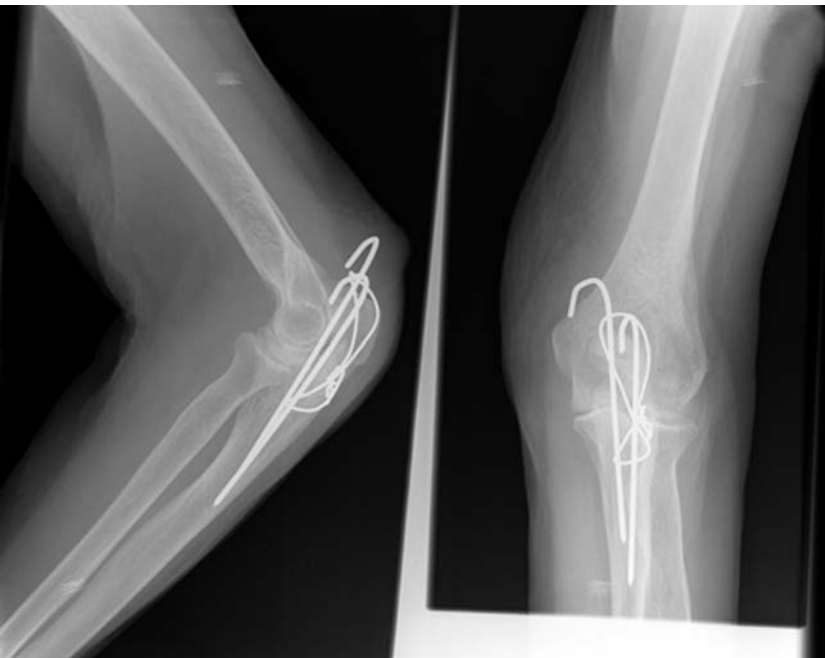- AP and true lateral flexed elbow. Displacement best evaluated on the lateral.
- Again be aware of epiphyseal appearances. A bifid epiphysis is normal although fusion should occur by 14 years. Rounded calcification within the triceps tendon can also be misleading.
- Important to assess the size of the proximal fragment – may require excision – and the degree of fragmentation – which may determine treatment modality.

Management

- Assess soft tissues, neurovascular status and immobilisation initially with above elbow backslab.
- *Undisplaced* – immobilise in approximately 90° of flexion. Reassess that no displacement at 1 week and mobilise around 4 weeks.
- *Non-operative* treatment can also be applied to displaced fractures in the elderly, low-demand, high surgical-risk patient – here the aim of treatment is pain-free fibrous union or even pseudarthrosis and therefore mobilisation should be as early as possible to prevent joint stiffness.
- *Displaced* – requires ORIF with k-wires and tension band or reconstruction plate for the multi-fragmentary fracture. Early mobilisation if possible.
- *Avulsion fractures* – if the proximal fragment is small, excision and reattachment of the triceps with suture anchors allows early mobilisation, maintains reasonable joint congruence and stability.



Olecranon process fracture.



Olecranon tension band wiring. The position of the k-wires is less than ideal; however, this may be projectional.

Ulna fracture – shaft fractures

Characteristics

- Traditionally described as a nightstick fracture, as the ulnar shaft is usually fractured by a direct blow.
- Potential for open injury as the ulna is a subcutaneous structure along most of its length.

Clinical features

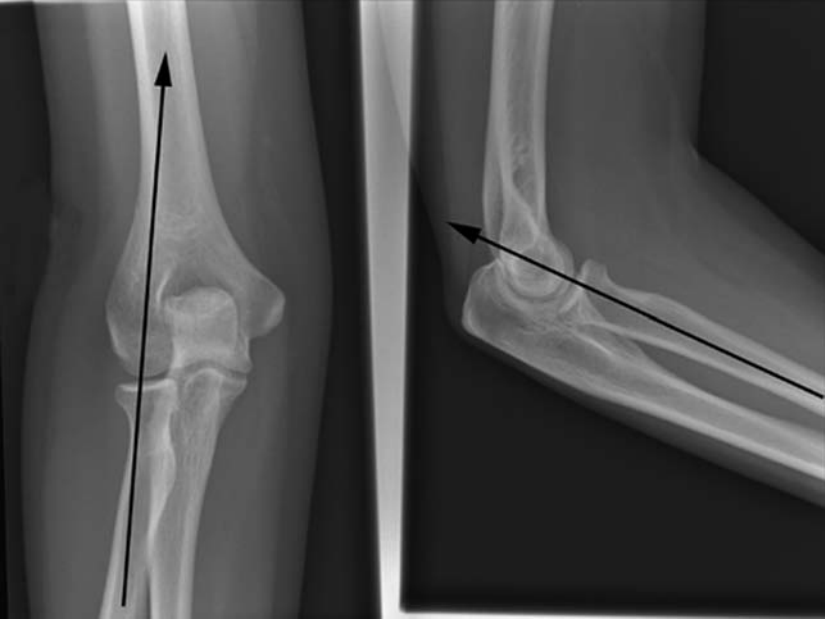
- Pain, swelling, bruising, fracture crepitus.
- Deformity and angulation depending on fracture displacement.
- Always suspect radio-capitellar dislocation – Monteggia pattern – see below.

Radiological features

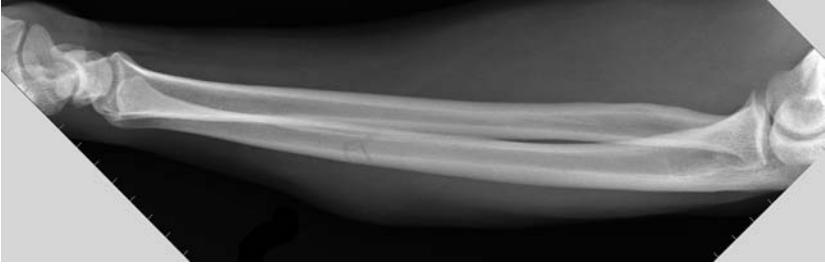- AP and lateral views of the forearm including elbow/wrist.
- Carefully examine the views of elbow for normal alignment. **A line drawn along the axis of the radius should pass through the centre of the capitellum on the lateral, AP and oblique views (see diagram below). This is known as the radiocapitellar line.**

Management

- Assess soft tissues, neurovascular status and immobilise with above elbow backslab initially.
- Undisplaced – Non-operative treatment with above elbow cast approximately 2 weeks, then short arm cast or functional brace until union.
- Displaced – $>10^\circ$ angulation or 50% shaft displacement should be treated with ORIF with compression plating, or flexible intramedullary nail/POP in children.
- Both bone forearm fractures should be treated with radial and ulna ORIF and early mobilisation in the adult and flexible intramedullary nail/above-elbow POP in children.



A line drawn along the axis of the radius should pass through the centre of the capitellum on all views.



Undisplaced fracture of the midshaft of ulna.

Monteggia fracture dislocation

Characteristics

- Originally described in 1814 by Monteggia.
- Mechanism – fall on outstretched hand with a degree of forced pronation. Can also result from a direct blow.
- Defined as a fracture of the ulna with dislocation of the radial head.
- Classified (Bado) according to direction of radial-head dislocation:
 - I Apex volar ulna fracture with volar dislocation of the radial head.
 - II Apex dorsal ulna fracture with dorsal dislocation of the radial head.
 - III Radial dislocation of the radial head.
 - IV Volar radial head dislocation with associated radial-shaft fracture.
- Uncommon fracture occurring in approximately 1 in 14 of forearm fractures.

Clinical features

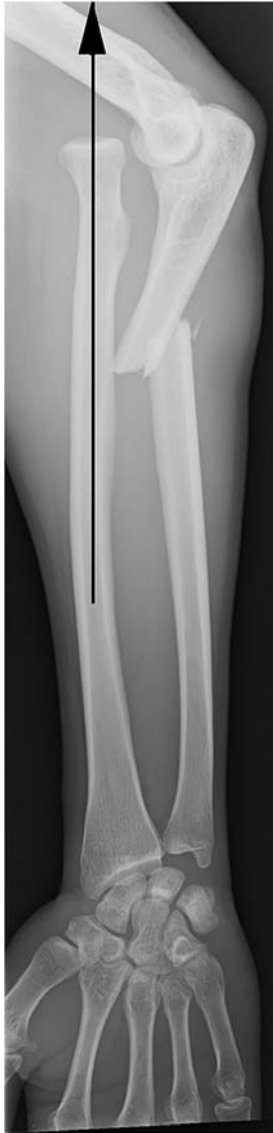- Pain, swelling, tenderness and crepitus with reduced range of movement.
- The forearm may appear shortened and deformity from the dislocated radial head may be apparent.
- Look for posterior interosseous nerve palsy.

Radiological features

- AP and true lateral views of the forearm including the elbow are necessary.
- Always suspect radial head dislocation with an isolated ulna fracture.
- Carefully examine the views of elbow for normal alignment; the radio-capitellar line should pass through the centre of the capitellum on all views (see diagram below).
- Beware in children as a subtle greenstick fracture may be missed. Always check the radial head position on all views and assess for subtle deformity of the ulna.
- A useful way of remembering this type of forearm fracture is with the acronym 'BUM' – Broken Ulna Monteggia

Management

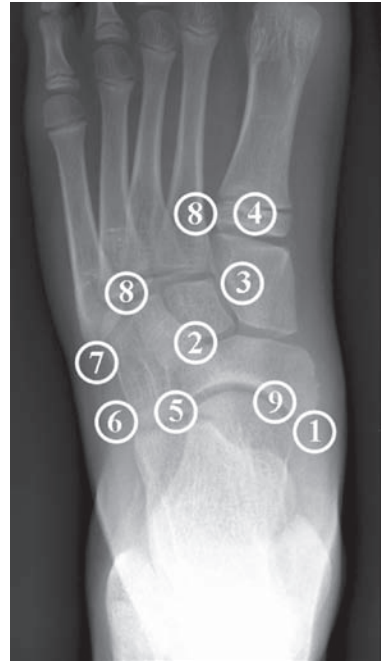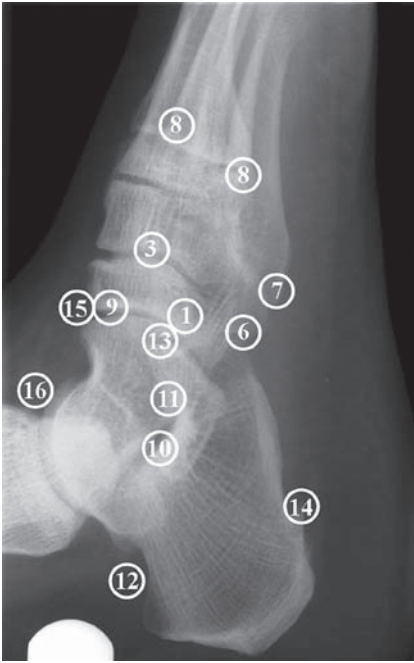- ABCs, assess soft tissues, neurovascular status and immobilise with a backslab.
- In children with greenstick fractures, correction of the angulation by closed reduction under GA is usually sufficient to reduce the radial head. Careful follow up with weekly radiographs is required. If any re-displacement and radial-head subluxation, a single radial flexible nail/POP should be used.
- In adults ORIF of the ulna will normally reduce the radial head, but occasionally separate open reduction of the radial head and soft-tissue reconstruction is required.



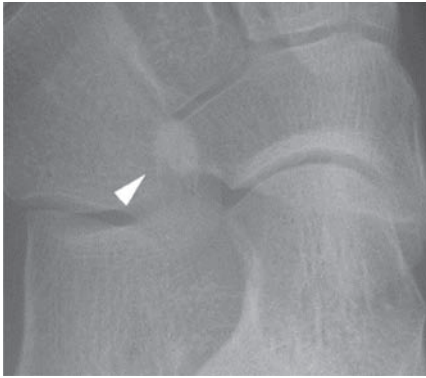Monteggia fracture. The radiocapitellar line does not pass through the capitellum due to radial-head dislocation.

Accessory ossicles of the foot

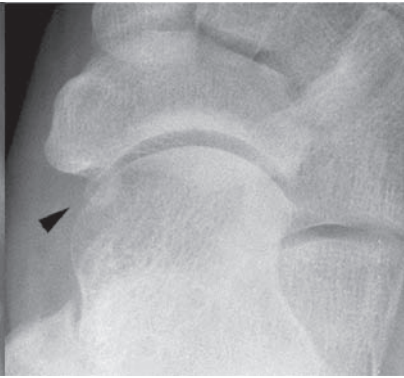- Commonly seen and queried on foot and ankle views.
- Suspect from their position and rounded corticated appearance.
- *The diagram below details the accessory ossicles around the foot.*



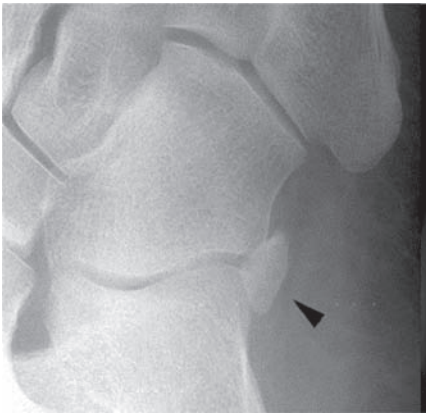- (1) Os tibiale externum
- (2) Processus uncinatus
- (3) Os intercuneiforme
- (4) Pars peronea metatarsalia
- (5) Cuboides secundarium
- (6) Os peroneum
- (7) Os vesalianum
- (8) Os intermetatarsium
- (9) Os supratalare
- (10) Talus accessorius
- (11) Os sustentaculum
- (12) Os trigonum
- (13) Calcaneus secundarius
- (14) Os subcalcis
- (15) Os supranaviculare
- (16) Os talotibiale.



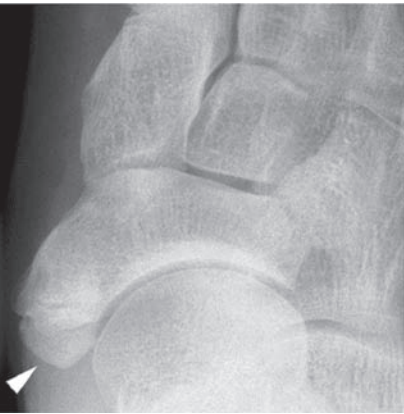Cuboides secundarium



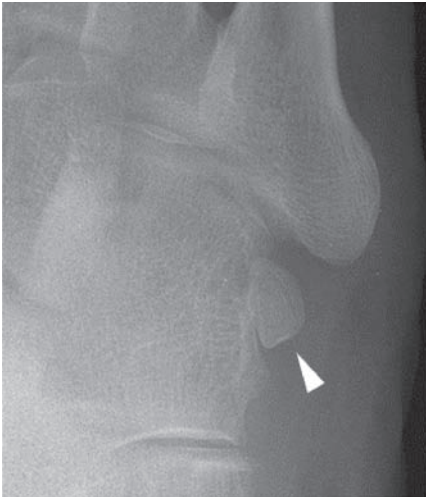Os supratalare



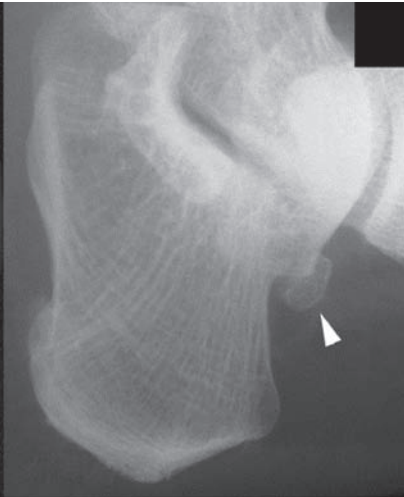
Os peroneum



Os tibiale externum



Os vesalianum



Os trigonum

Ankle fractures

Characteristics

- Very common injury in sport and daily activity with minor falls/twists etc.
- All ages affected.
- Classified by Danis–Weber, based on the level of the fibular fracture.
 - **Weber A** Fracture distal to the syndesmosis (i.e. below the mortice).
 - **Weber B** At the level of the syndesmosis; this may be disrupted.
 - **Weber C** Fracture proximal to the syndesmosis, which is usually disrupted.
- The above classification is simple but does not take into account injury to other structures such as the medial malleolus, or the posterior tibia (posterior malleolus).
- In addition it is useful to describe which malleoli are involved (lateral, medial, posterior) and to describe if mortice-joint disruption (i.e. talar shift) is present.
- When the talus does not lie underneath the tibial plafond, the ankle is subluxed (mild mal-alignment) or dislocated (frank mal-alignment).
- The talo-crural (ankle) joint is slightly bicondylar rather than planar, and thus small displacement equates significant mismatch. With large forces crossing this joint ($4 \times$ body weight) mal-alignment soon produces post-traumatic arthrosis.
- Beware the Maisonneuve injury – proximal fibular fracture and deltoid (medial) ligament injury with the line of force travelling through the mortice and syndesmosis, thus destabilising the ankle.

Clinical features

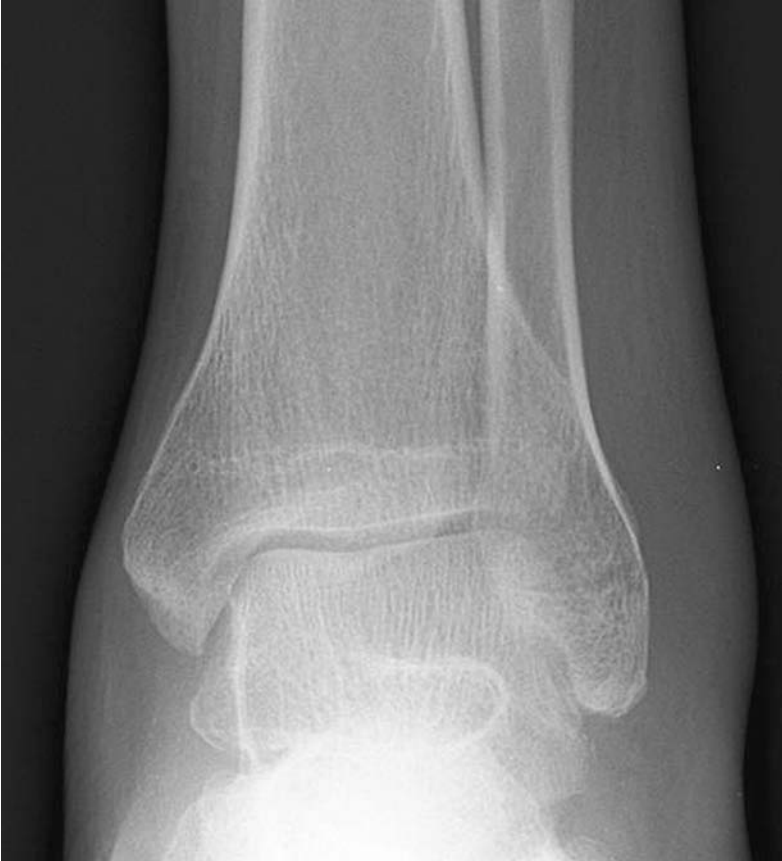- Pain around the ankle joint and usually inability to weight bear.
- Swelling, possible deformity, bruising and localised bony tenderness.
- The presence of gross deformity or neurovascular compromise should be treated as an emergency before X-ray confirmation, by manipulation and backslab.

Radiological features

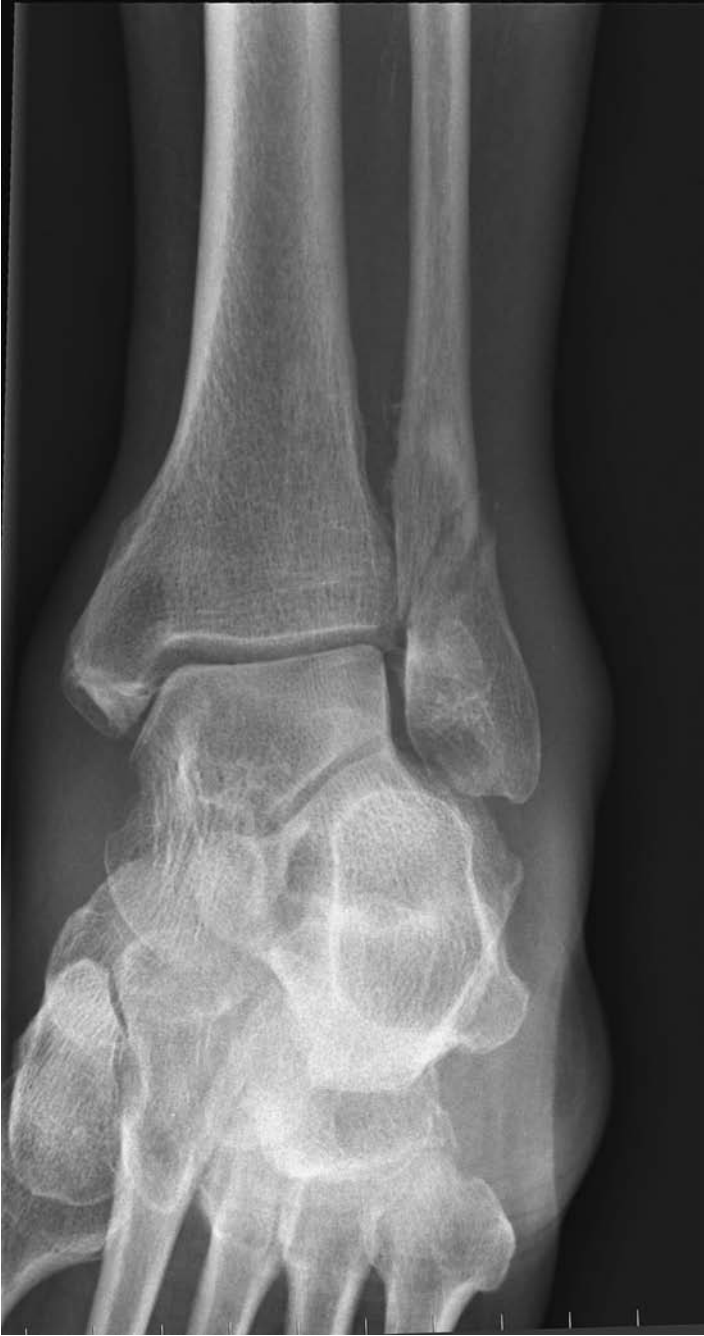- AP mortice and lateral radiographs are essential.
- If a fibular fracture is present assess the level, displacement and pattern.
- With proximal fibular fracture consider Maisonneuve injury and obtain ankle views if any tenderness or pain on talo-crural (ankle) movement.
- Assess the mortice joint for congruity. The space between the medial malleolus and the talus should be of similar size to that between the distal tibial surface and the talus.
- Assess the distal tibiofibular distance as a guide to syndesmosis/inferior tibiofibular ligament disruption.

Management

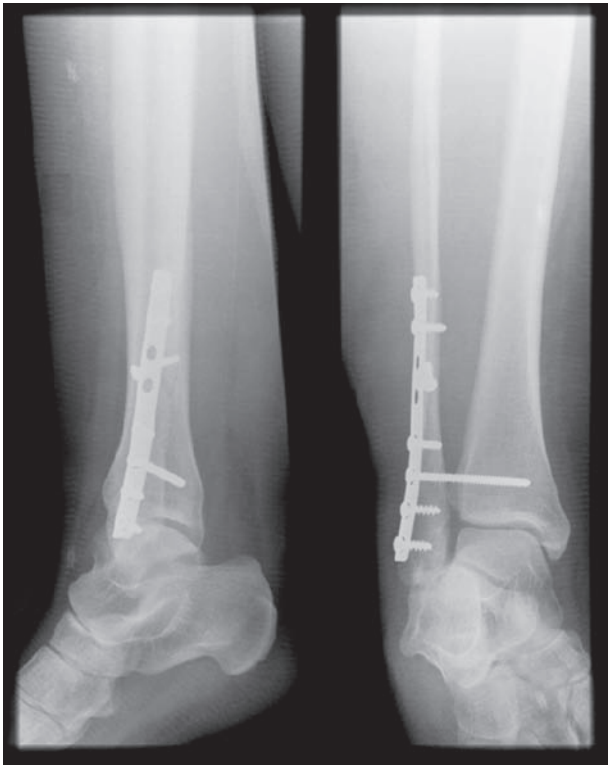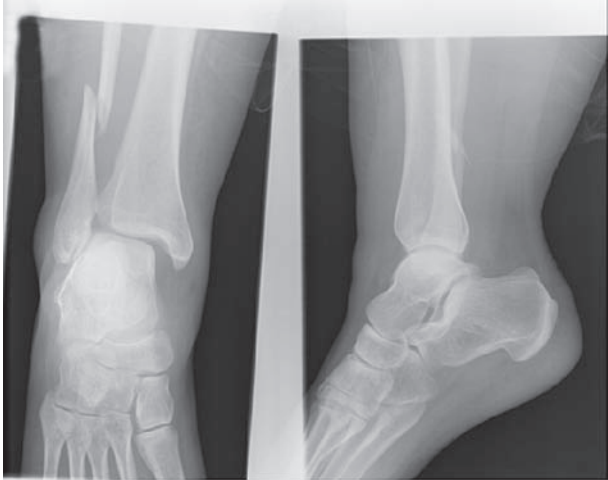
- Assess soft tissues, neurovascular status, reduce dislocations and immobilise initially with backslab.
- The principle of treatment is achieving and maintaining the accurate relationship of the talus beneath the tibial plafond.
- Elevation, ice and foot pumps are useful to decrease the swelling.
- Stable, undisplaced fractures can be treated with POP or even ankle supports (e.g. Aircast stirrups) and weight-bearing mobilisation.
- Displaced fractures require reduction; closed reduction and POP is usually all that is needed for paediatric fractures and this is also of use in low-demand elderly patients.
- Unstable fractures require ORIF – the majority of displaced ankle fractures in the adult population are currently treated operatively with plates/screws.
- It is difficult to assess stability – for example medial tenderness is unreliable to assess damage of the deltoid ligament – some authors suggest stress radiographs in external rotation and then only ORIF the truly unstable ankles.



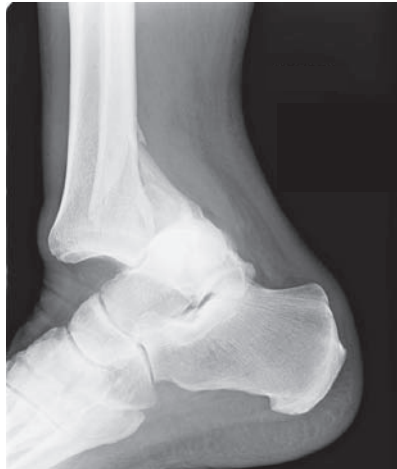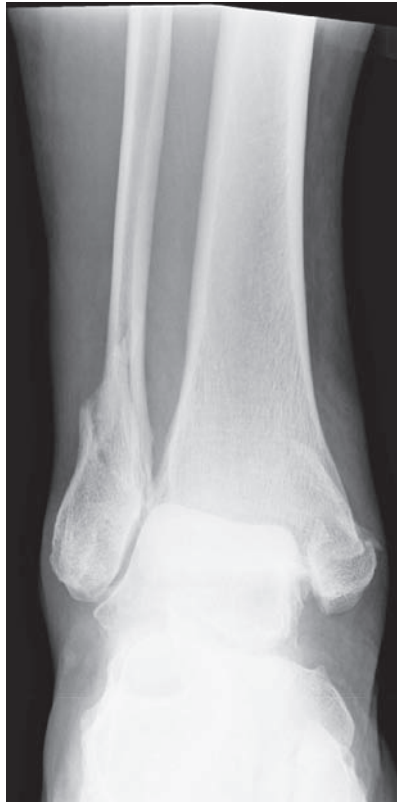Weber A: ankle fracture.



Weber B: ankle fracture.



Weber C: right ankle fracture treated with ORIF.



Fracture dislocation of the right ankle. Never send a patient with a significant deformity (suspected dislocation) or neurovascular compromise to the X-ray department. Reduce and then image.

Characteristics

- Common finding on MRI scans of post-traumatic joints – particularly the knee with ligament injury, e.g. in the lateral femoral condyle in ACL deficiency and posterolateral tibial plateau bruising is a marker of joint derangement at the time of ACL injury.
- Also known as marrow oedema syndrome and microfracture syndrome.
- Numerous patterns of bruising identified.
- Most commonly affects the lateral femoral condyle.
- May represent damage to the articular cartilage at the time of injury – hence the use of the term ‘microfracture’.

Clinical features

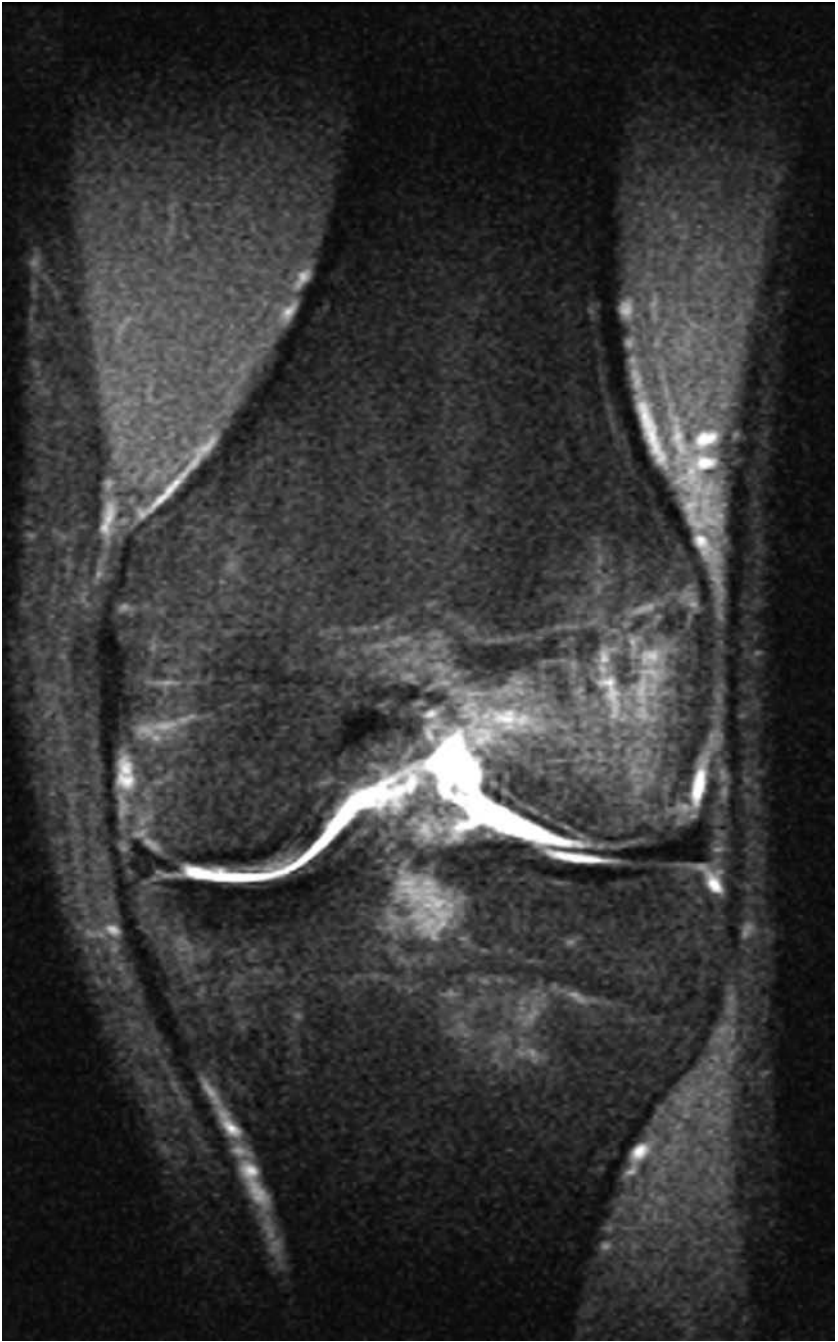- Symptoms often related to the underlying ligamentous disruption – *see* ‘Knee injuries’.
- Bony pain and tenderness often related to the underlying bone bruising.
- Lasts up to 12 months frequently becoming more pronounced at 6–12 weeks following injury.
- Long-term outcome is unknown.

Radiological features

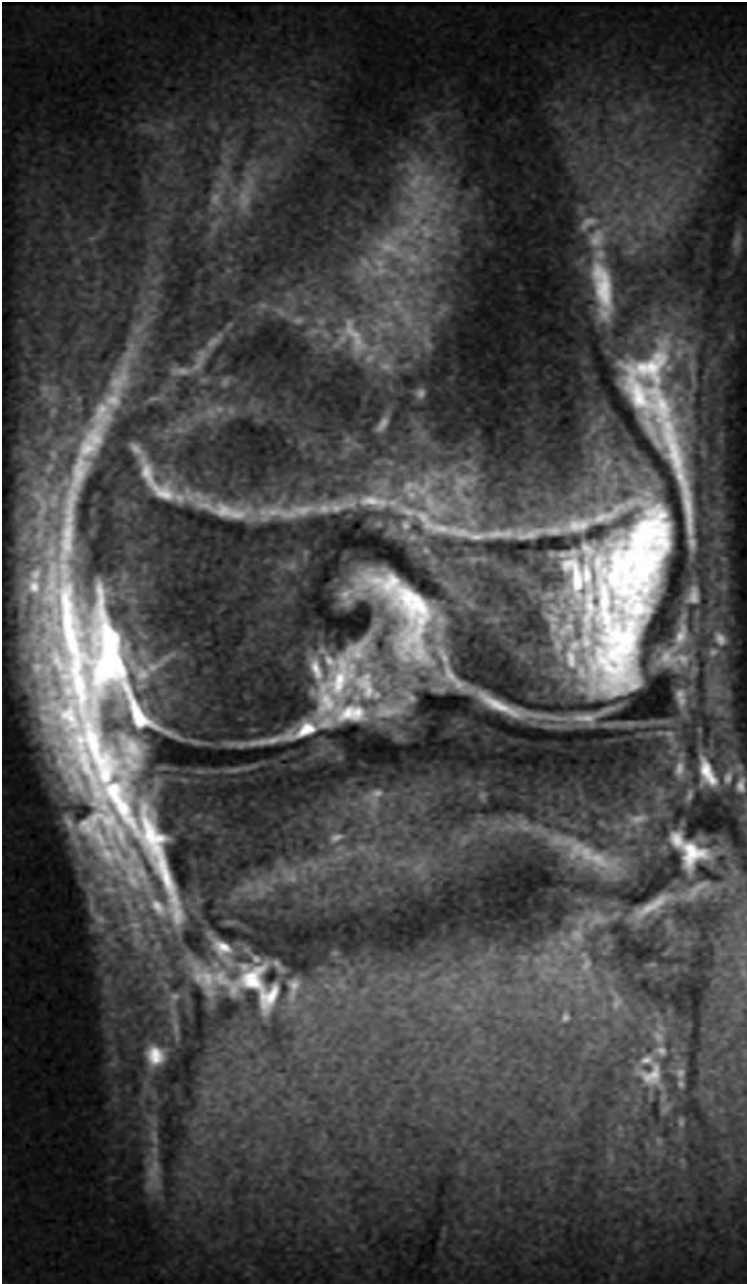- Usually normal AP and lateral knee X-ray – occasionally an avulsion fracture of the lateral tibial plateau, at the site of attachment of the lateral capsular ligament, is seen; this is known as a Segond fracture and is frequently associated with an ACL injury.
- Bone bruising is manifest as high signal intensity on T2 weighting and STIR MRI.
- MRI: assess for ligamentous and meniscal pathology.

Management

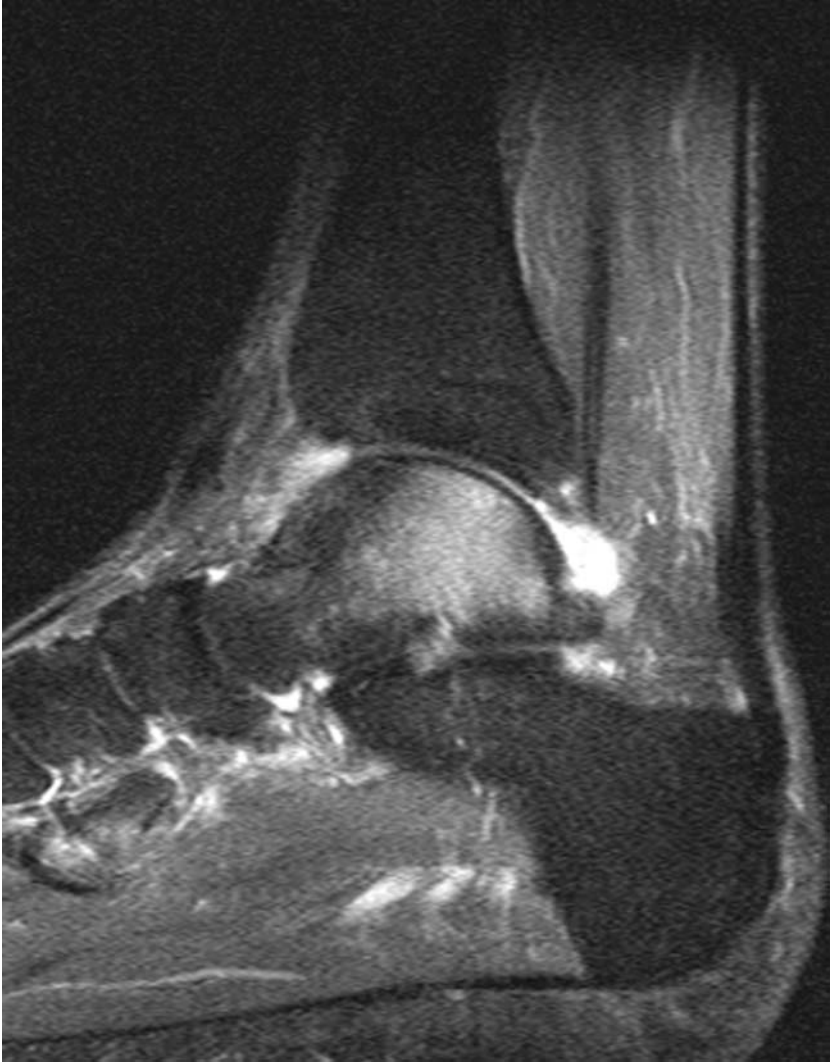- Treat as per the underlying ligamentous injury.
- Possibly restrict weight bearing.
- Persistent pain may require analgesia, e.g. after an MCL injury has settled down.



Bone bruising: increased bone-marrow signal seen within the lateral femoral condyle secondary to an ACL rupture. In this example the medial collateral ligament (MCL) appears normal.



Another example of bone bruising within the lateral femoral condyle due to ACL rupture. Note the increased signal in relation to both sides of the MCL, indicating a ligament strain.



Sagittal STIR MRI of the ankle, demonstrating increased signal within the body of talus, consistent with bone-marrow oedema.

Calcaneal (Os calcis) fractures

Characteristics

- Commonest (and largest) of the tarsal bones to fracture.
- 95% occur in adults and are often bilateral.
- Axial loading force, e.g. fall from height, is the commonest mechanism of injury.
- Due to the mechanism of injury there are often multiple associated injuries e.g. contralateral os calcis, ipsilateral femoral neck, acetabular, tibial plateau fractures as well as compression fractures of the spine.
- Classified as intra (75%) or extra-articular (25%) fractures by Essex-Lopresti, with intra-articular subdivided:
 - Undisplaced.
 - Tongue type.
 - Joint depression type.
 - Comminuted.

Clinical features

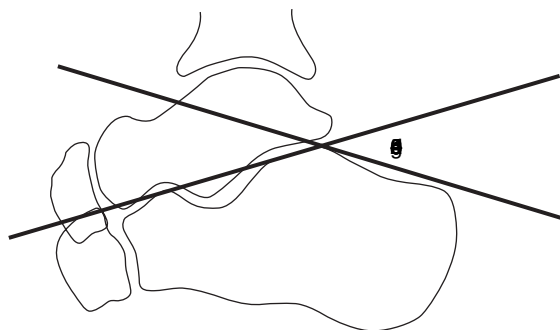
- Careful history – be vigilant in the unconscious patient.
- Pain and swelling are usually associated with inability to weight bear.
- The heel may appear shortened and widened when viewed from behind.
- Bruising extending along the sole tends to differentiate from an ankle fracture.
- Beware of compartment syndrome.
- Extensive fracture blisters are common.

Radiological features

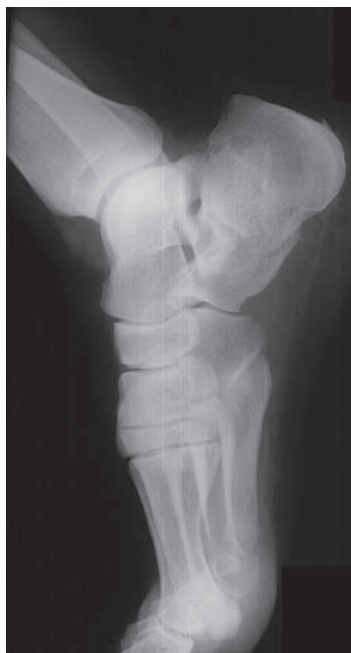- AP and lateral views of the ankle, and an axial heel view should be performed. The AP view allows visualisation of the calcaneo-cuboid joint and the anterosuperior calcaneus. The lateral X-ray best visualises the posterior facet.
- Subtle compression fractures can be suspected by assessing Bohler's angle (see diagram). If decreased below 25° – 40° , a fracture should be suspected. Comparison with the unaffected side (if not fractured!) can be helpful.
- Similarly, an increase in the Crucial Angle of Gissane (angle between a line drawn along the lateral border of the posterior facet and the anterior process) usually indicates posterior facet depression.
- An axial view of the calcaneum, if tolerated, can help visualise the fracture.
- Because of the complex nature of calcaneal fractures, plain radiographs often underestimate the degree of damage. CT is extremely useful both to assess injury but also in assessing/planning surgical reconstruction with ORIF particularly looking at the posterior facet.
- Sanders classified intra-articular os calcis fractures by CT.

Management

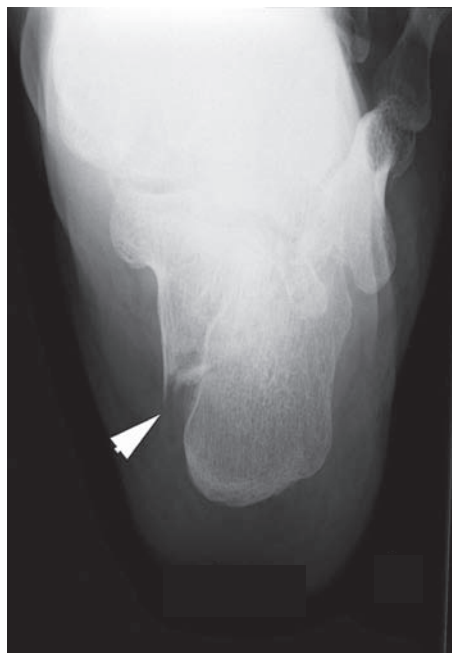- ABCs, assess soft tissues, neurovascular status, reduce dislocations and immobilise initially with backslab. Analgesia, elevation and foot pumps.
- Surgical vs. non-operative management is still controversial.
- Good physiotherapy is essential following either form of management.
- Displaced intra-articular fractures, amenable to ORIF, in relatively young patients with good soft tissues should be considered for reconstruction with a lateral plate.
- The major complication of ORIF is wound breakdown/infection.
- ORIF improves shoe wear (reduced width), but does little for subtalar movement.



Diagrammatic representation of Boehler's angle.



Lateral view of a calcaneal fracture.



Dedicated calcaneal view. Arrow: fracture.

Characteristics

- Very common injury in the elderly, with minimal trauma, due to reduced bone density.
- In the young, significant trauma required – usually road-traffic accident.
- More common in elderly females; below the age of 60, men are affected more frequently (usually extracapsular fractures).
- More common in patients with multiple comorbidity, common medications including corticosteroids, thyroxine, phenytoin and frusemide.
- Classified as intracapsular (femoral-head vascularity at risk) and extracapsular fractures, with further subdivision according to anatomical level of the injury:
 - *Intracapsular* – subcapital, transcervical and basicervical.
 - *Extracapsular* – pertrochanteric (or intertrochanteric) and subtrochanteric.
- Intracapsular fractures are classified according to Garden – I–IV:
 - I *Incomplete*. Medial cortex not broken. Valgus impaction.
 - II *Complete*. Medial cortex broken. Trabeculae interrupted but not angulated.
I and II are **undisplaced**.
 - III *Incomplete displacement* – angulated trabecular pattern.
 - IV *Fully displaced*. No bony continuity – head trabeculae align with acetabulum.
III and IV are **displaced**.

Clinical features

- Inability to weight bear most commonly, but beware as occasionally the patient can mobilise.
- Classically the leg is shortened and externally rotated.
- Pain on hip rotation and tenderness in the groin and greater trochanter.

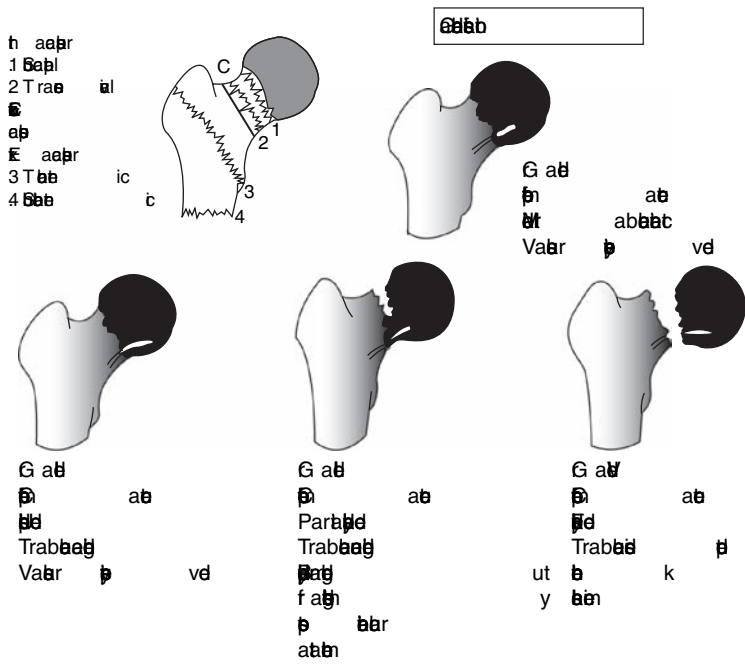
Radiological features

- AP and lateral radiographs will usually visualise the fracture line.
- Look for asymmetry. Compare Shenton's lines on the AP. On the lateral, check for angulation of the head in respect to the neck.
- Subtle fractures may only be recognised by trabecular pattern disruption.
- If suspicious, but no fracture is seen, CT, MRI or bone scan at 48 hrs or delayed repeat coned plain films can be of benefit.

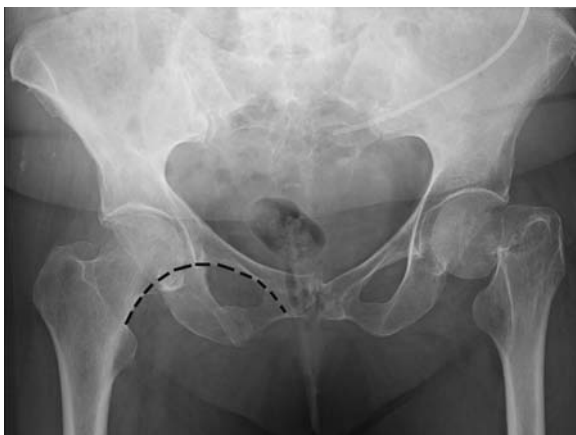
Management

- ABCs, assess soft tissues, neurovascular status and immobilise for comfort with skin traction if possible or gutter splints otherwise.
- Analgesia – perhaps intravenous opiates combined with a femoral nerve block.
- Majority managed operatively to allow early mobility and thus decreasing mortality, pressure sores etc.

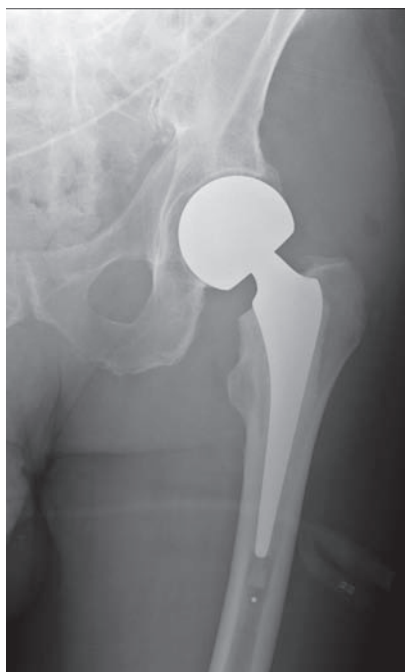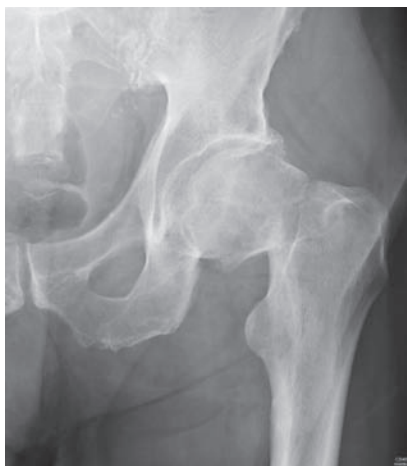- *Intracapsular*
 - Undisplaced fractures – biologically young patients are fixed with MUA and cannulated screws, consider hemiarthroplasty in frail population needing one operation.
 - Displaced fractures – still a role for percutaneous screw fixation in the young patient, but considerable non-union and AVN requiring conversion to THR in the future. Fixation should be as soon as safely possible. In an elderly population total hip replacement or hemiarthroplasty are the two major treatments used.
- *Extracapsular*
 - Pterochantheric – dynamic hip screw/intramedullary hip screw type fixation.
 - Subtrochantheric – long DHS (if not reverse oblique), DCS (dynamic condylar screw) blade plate, or reconstruction nail.
 - Optimisation of the patient prior to surgery and good-quality post-operative rehabilitation are essential.
 - Early operative management and early mobilisation are associated with a reduction in complications.



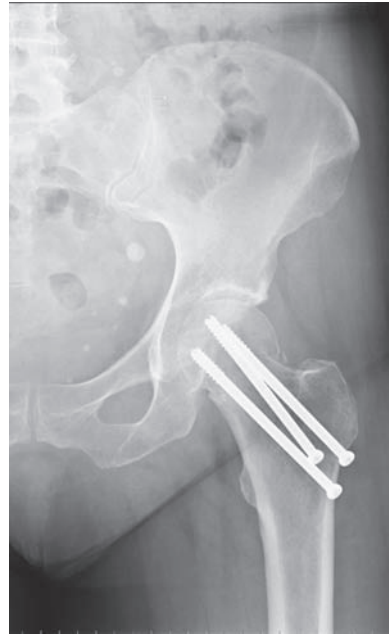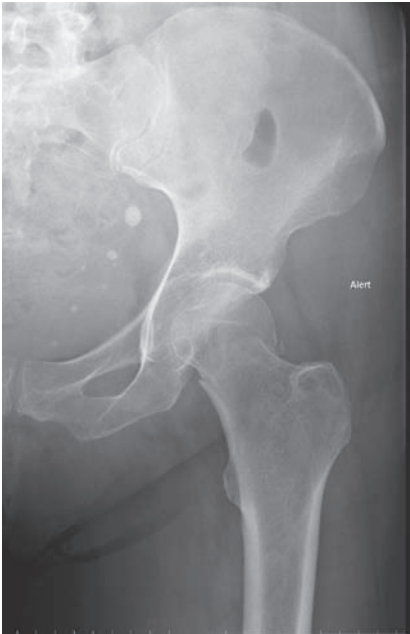Types and grading of proximal femoral fractures. Note: in Garden Classification grades III and IV, the blood supply is interrupted. From: *Surgery Facts and Figures*; Greenwich Medical Media, 200: page 353.



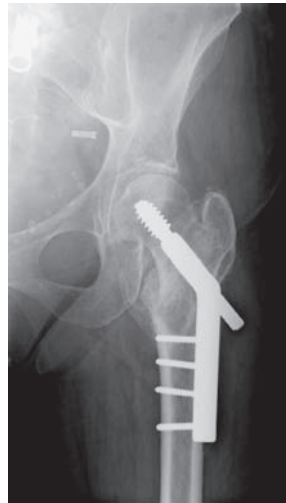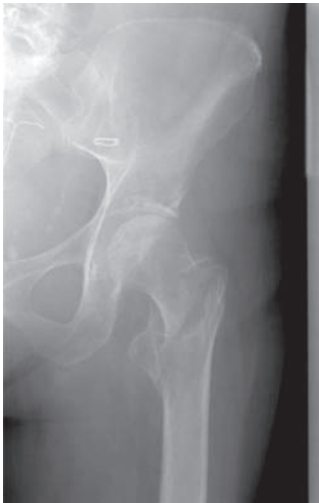Left fractured NOF. Note the disruption of Shenton's line.



Intracapsular displaced left neck of femur fracture treated by monopolar, modular cemented hemiarthroplasty (JRI-Furlong).



Transcervical neck of femur fracture treated with cannulated hip screw in this 57-year-old patient. The screws should ideally be parallel.



Extracapsular (intertrochanteric) neck of femur fracture and post-fracture healing by controlled collapse over a Dynamic Hip Screw – note how the barrel of the screw has backed out through the plate.

Femoral shaft fracture

Characteristics

- Large forces required, e.g. road-traffic accident, crushing injury or fall from height.
- Divided into proximal, middle and distal third fractures.
- Pathological fractures seen in relation to, metabolic bone disease and malignant deposits – particularly important in low-energy injuries.
- Haemorrhage is considerable – between 1 and 3 litres depending if open or closed and degree of soft tissue/bony damage.
- Fat embolism is more likely to become symptomatic with increasing numbers of long-bone fractures.

Clinical features

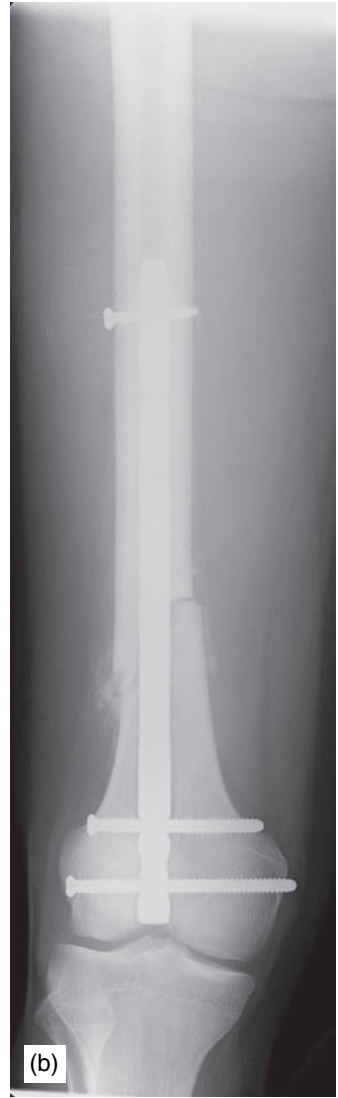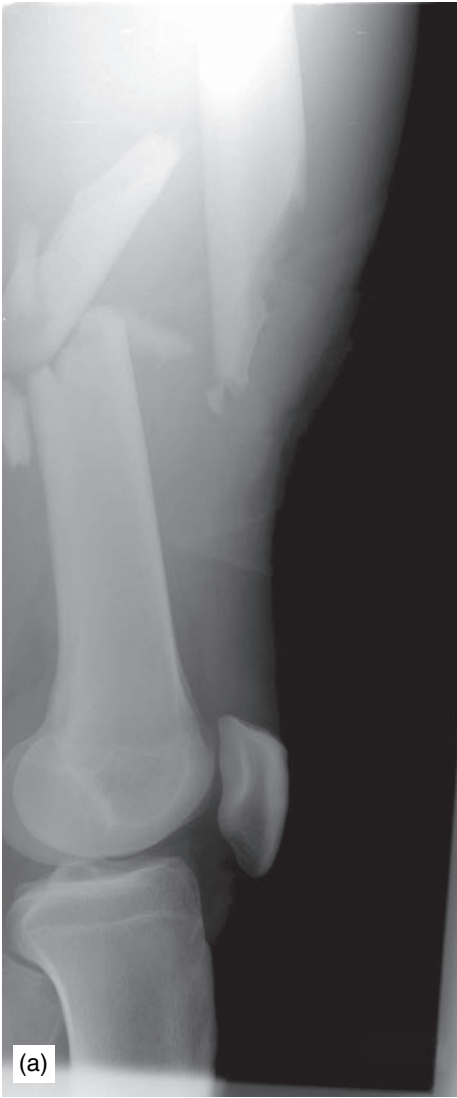- Pain, swelling, tenderness, deformity and open fracture common presentations.
- Deformity will vary depending on the level of the fracture (related to muscular attachments and their action) and the degree of soft-tissues stripping.
- A rapidly expanding thigh suggests a large, expanding haematoma.
- Beware associated injuries such as ligamentous knee injuries, fractured NOF/hip dislocation and supracondylar fractures all of which can be difficult to assess.
- Neuro-vascular damage is thankfully uncommon.

Radiological features

- AP and lateral of hip, fracture site and knee – e.g. to detect neck-shaft fracture.
- Numerous patterns classified by AO/OTA as:
 - A = Simple: spiral (A1), oblique (A2) and transverse (A3)
 - B = Wedge: spiral (B1), bending (B2) and fragmented (B3)
 - C = Complex: spiral (C1), segmental (C2) and irregular (C3)
- Carefully assess for intra-articular extension into the knee.

Management

- ABCs, assess soft tissues, neurovascular status and immobilise with pneumatic or Thomas splint, in the short term.
- Analgesia – traction will decrease pain by reducing spasm and crepitus.
- Non-operative treatment – reserved for children and elderly declining operation – includes skin or skeletal traction.
- Operative management usually involves intramedullary nailing in the skeletally mature and flexible nails or plates in the paediatric patient.
- Recent advances in plate technology (e.g. LISS[®] = less invasive stabilisation system), have led to a resurgence of plating with the right indication.
- External fixation is generally reserved for highly contaminated open fractures or temporary stabilisation.



(a) Multifragmentary mid-femoral-shaft fracture, (b) Femoral-shaft fracture with retrograde nail. Ideally, the nail should be longer.

Femoral supracondylar fracture



Characteristics

- Not an uncommon injury in the elderly with relatively low-energy trauma.
- Following high-energy trauma, e.g. motor vehicle, in any age.

Clinical features

- Pain, swelling, tenderness, deformity and open fracture common presentations.
- Beware associated injuries, e.g. ligamentous knee injuries, fractured NOF/hip dislocation and supracondylar fractures all of which can be difficult to assess.
- Significant risk of neuro-vascular damage because of proximity to the popliteal fossa.
- ‘What was the pre-injury level of function?’ – particularly important in the elderly non-ambulant patient when considering treatment.

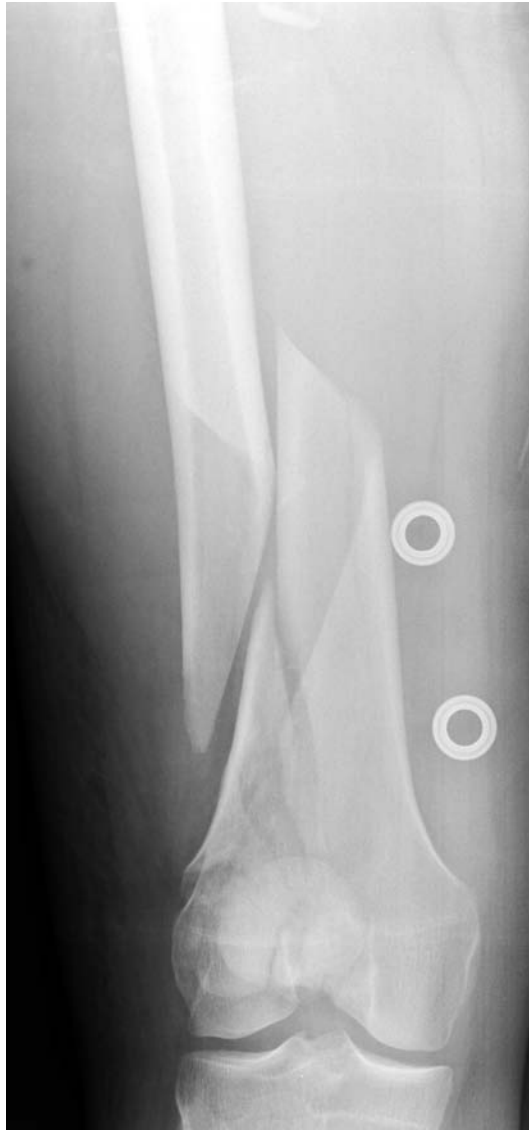Radiological features

- AP and lateral of hip, fracture site and knee, e.g. to detect neck-shaft fracture.
- Carefully assess for intra-articular extension into the knee and patellar fractures – best seen on the lateral knee X-ray.
- CT is helpful to assess/plan ORIF.
- Numerous patterns classified by AO/OTA as:
 - A = extra-articular: oblique (A1), wedge (A2) and comminuted (A3).
 - B = partially articular: lateral condyle (B1), medial condyle (B2) and posterior condyles – Hoffa fracture(B3).
 - C = complex articular: intercondylar split (C1), multi-fragmentary metaphysis (C2) and comminuted articular surface(C3).

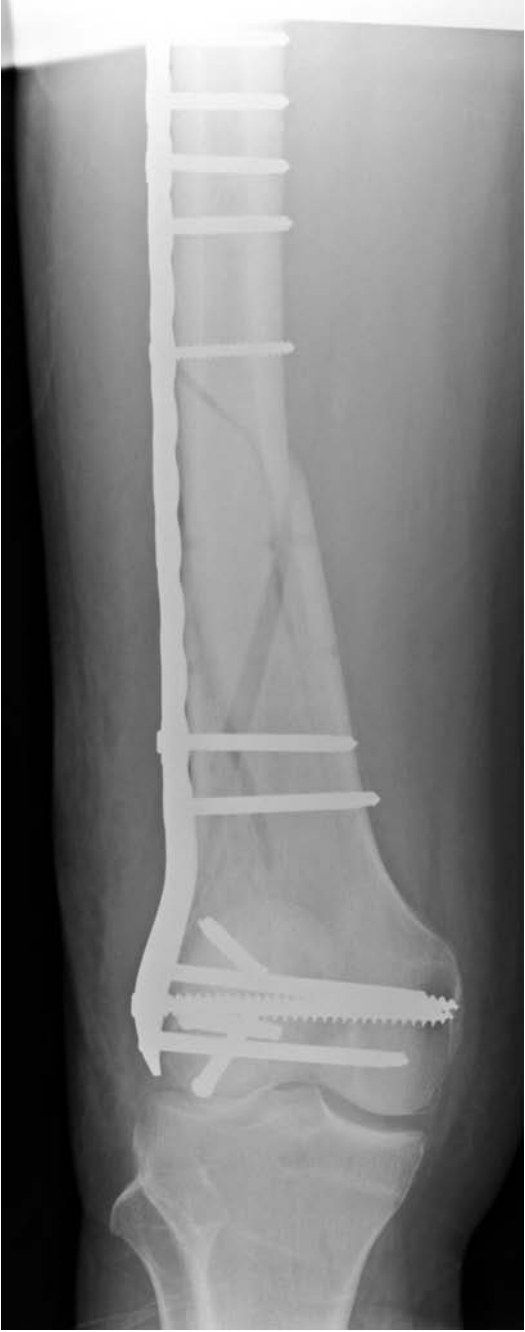Management

- ABCs, assess soft tissues, neurovascular status and immobilise with skin traction or gutter splints.
- If pulses not present on Doppler – vascular referral for revascularisation (possibly temporary stent pending ORIF of the bony injury). Important to keep checking pulses as intimal tears can present as delayed vascular compromise.
- The vast majority are managed operatively.
- The principles of treatment are:
 - Operate when and if the soft tissues allow.
 - Restore the joint congruence.
 - Provide stability to allow knee flexion–extension.

- Methods of fixation:
 - Intra-articular buried screws/lag screws if possible.
 - Extramedullary devices:
 - DCS = Dynamic condylar screw.
 - Blade plate.
 - Liss[®] = Less invasive stabilisation system.
 - Intramedullary devices:
 - Supracondylar nail ± lag screws.
 - External fixation, e.g. temporary bridging of the knee.



Intra-articular fracture of the distal femur.



Distal femoral intra-articular fracture (same case as previous page) treated with locking plate and intra-articular screw (AXOS plate).

Hip dislocation – traumatic

Characteristics

- Mechanism of injury usually involves massive force transmitted along the femoral shaft, e.g. a dashboard injury in a road-traffic accident.
- Posterior dislocation (80%) tends to occur with the hip flexed and adducted at time of impact. With abduction, anterior dislocation can occur.
- Central dislocation occurs with medial displacement of the femoral head through or partially through a fragmented acetabulum.
- Often associated with other injuries such as a patellar fracture, PCL injury or posterior acetabular-wall fracture.

Clinical features

- Posterior dislocations – leg is flexed, adducted and internally rotated – unless an associated femoral neck or shaft fracture mask the deformity.
- Pain tends to be excruciating.
- With an acetabular (e.g. posterior wall) fracture, spontaneous reduction possible.
- Sciatic nerve injuries are common – up to 20% – test preferentially the peroneal (test foot eversion) rather than tibial branch (foot plantar flexion) of the sciatic nerve.

Radiological features

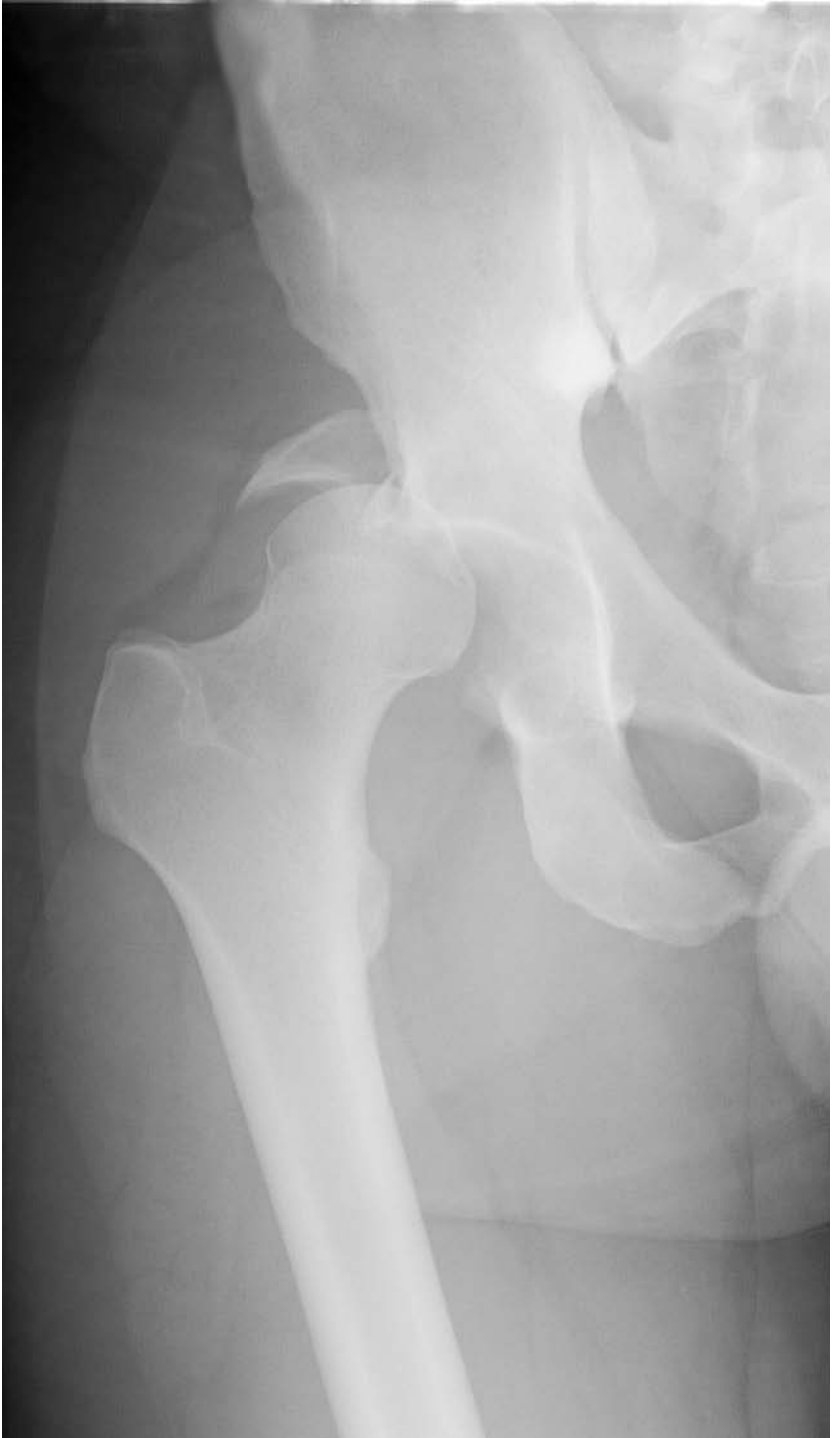- Abnormality usually obvious on the AP view. Lateral view recommended in all cases to aid in determining direction of dislocation and associated fractures.
- With posterior dislocations the femoral head appears smaller than the unaffected side on the AP view and conversely with anterior it appears larger.
- Look for the lesser trochanter – overlies the femoral shaft in posterior dislocation (due to internal rotation), whereas it is seen in profile in anterior (due to external rotation).
- Look for acetabular involvement as this affects likelihood of sciatic-nerve damage, stability and long-term functional outcome.
- Always assess the pelvic ring fully as associated fractures/disruption are common – *see* ‘Pelvic and acetabular fractures’.

Management

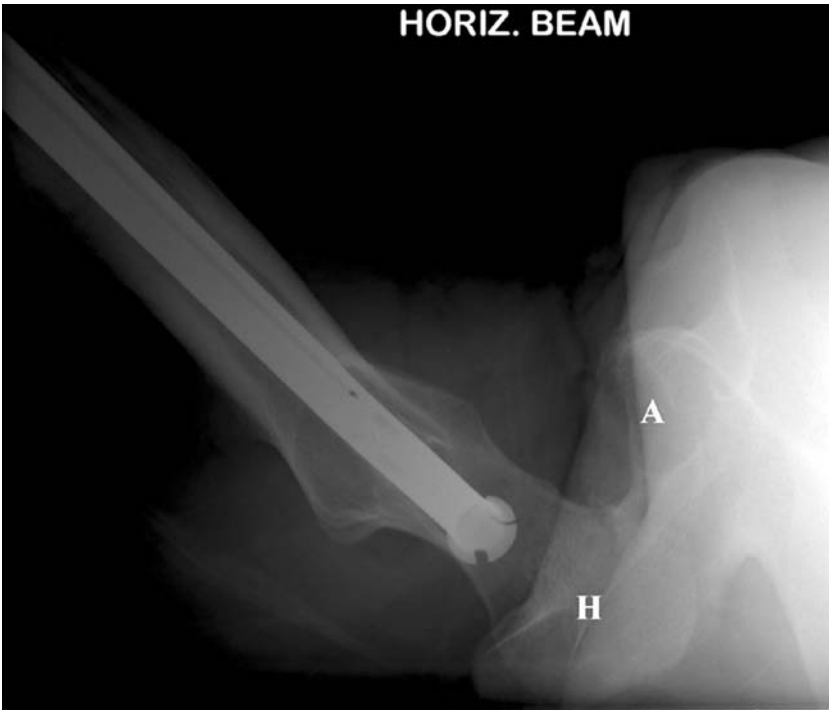
- ABCs, assess soft tissues, neurovascular status, reduce and immobilise.
- Early reduction is the definitive treatment. Complete muscle relaxation is desirable and thus reduction under general anaesthetic with screening is optimal to decrease femoral head trauma.
- If a delay is envisaged, one attempt at closed reduction in the emergency department can be performed with sedation – the lesser evil is to reduce the head and protect its vascularity.

- Bigelow reduction technique is flexing the knee to 90°, flexing the hip at or beyond 90°, initially adducting and internally rotating, sustained femoral traction and then correcting the deformity with external rotation and abduction. This is best done standing above the patient with an assistant to stabilise the pelvis.
- Post-reduction – skin traction in abduction, check AP/lateral and Judet views.
- If closed reduction fails, a CT should be obtained ideally prior to open reduction. Loose intra-articular bodies should be retrieved at open reduction.
- Posterior-wall fragments should be treated with ORIF.





Posterior dislocation of the right hip. Note the posterior column fracture of the acetabulum.



Lateral view demonstrating posterior dislocation. A = acetabulum, H = femoral head.

Knee soft-tissue injury

Characteristics

- Usually following discrete episode of trauma, e.g. twisting, side-stepping, tackled in sport or higher-energy trauma such as motor vehicle injury or skiing.
- Specific mechanisms of injury should be sought, e.g. rapid deceleration injury or posterior force on the proximal tibia gives clues for a PCL injury.
- Knee dislocation is a serious injury indicating multi-ligament trauma, although this is not *de facto* a bicruciate injury.
- Knee dislocation classified by the direction of dislocation of the tibia and the ligaments involved.
- Significant risk of neurovascular injury with knee dislocation:
 - 33% of cases have popliteal arterial damage.

Clinical features

- History is helpful depending on the speed and severity of the injury, e.g. unlikely to remember exactly what happened to the leg or whether there was a 'pop' in a high-speed accident!
- Pain, swelling, site of maximal tenderness, effusion.
- Ability to weight bear initially and at the time of examination.
- Ability to straight leg raise, e.g. is there a mechanical block to extension (10° – 15°) indicative of bucket handle meniscal tear.
- Range of movement.
- Stability:
 - ACL laxity – Lachmann – pivot shift test useful after the acute event.
 - PCL injury – loss of medial step-off – similar to a posterior sag.
 - Posterolateral corner laxity – dial test – comparative prone external foot rotation with 30° of knee flexion.
 - Collaterals – varo-valgus opening in extension and 30° flexion.
- Record findings as:
 - Grade I Mild laxity.
 - Grade II Moderate laxity, but solid end point.
 - Grade III No end point.

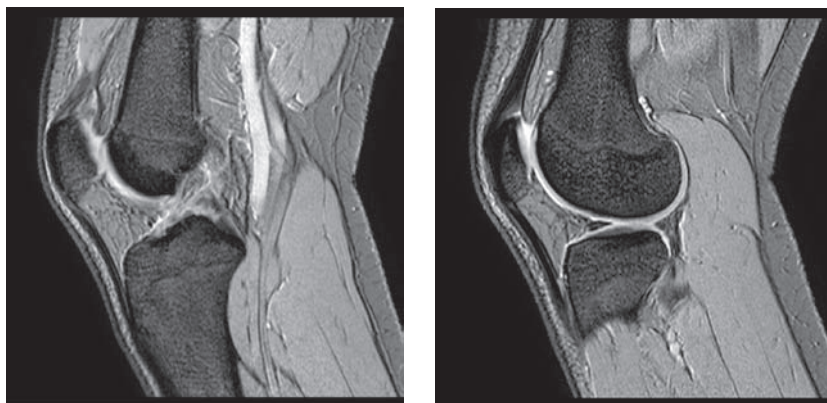
Radiological features

- AP and lateral may demonstrate associated fractures, e.g:
 - Segond fracture = mid capsular avulsion from the lateral tibial plateau associated with anterior cruciate injury.
 - Tibial spine avulsion of ACL – graded I–III by Meyers–McKeevor.
 - Avulsion of Gerdy's tubercle at the insertion of the ilio-tibial band.
 - Haemarthrosis.

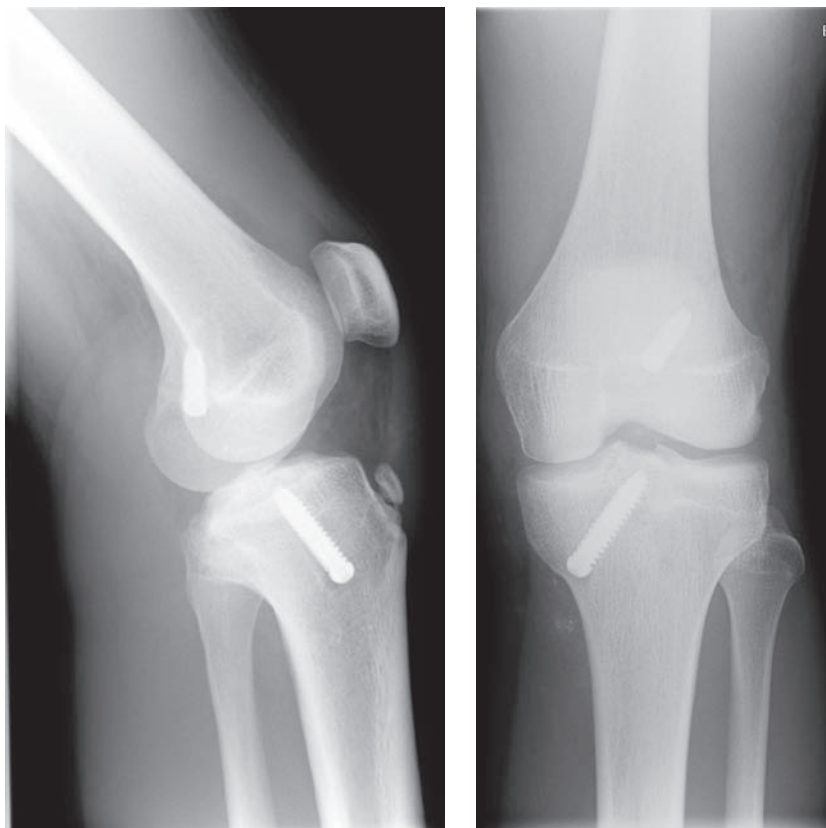
- MRI is the current gold standard imaging modality, but is less sensitive than a skilled examiner in the detection of acute ACL lesions. MRI detects:
 - *ACL avulsion/mid-substance tear* – better for sub-acute ACL lesions.
 - Discontinuity in the fibres of the ACL.
 - Associated anterior tibial translation.
 - Bone bruising within the lateral femoral condyle.
 - Medial collateral ligament injury.
 - *PCL avulsion/mid-substance tear*.
 - Discontinuity in the fibres of the PCL
 - Associated posterior tibial translation
 - *Collateral ligament damage*.
 - Increased signal on both sides of a collateral ligament indicates ligamentous injury. Distinguish between intact and disrupted fibres.
 - *Meniscal injury*.
 - Increased signal with a meniscus extending to an articular surface indicates a tear; this may be horizontal or vertical.
 - *Extensor mechanism injury*.
 - Assess for altered signal and/or discontinuity within the quadriceps or patellar tendons.
 - *Bone bruising*. See previously.

Management

- *General*
 - ABCs, assess soft tissues, neurovascular status and immobilise initially.
 - Obtain MRI to confirm diagnosis.
 - Mobilise as soon as possible.

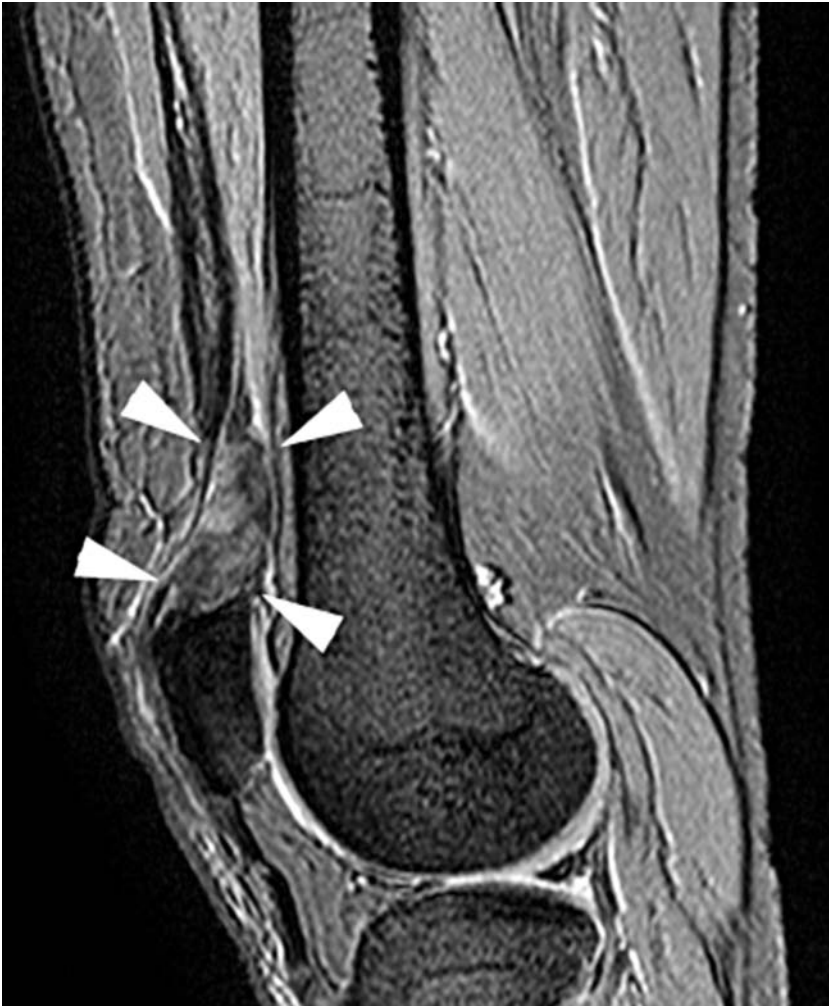

Sagittal gradient T2 MRI. Note the discontinuity of, and increased signal within, the fibres of the ACL. There is associated anterior tibial translation (a vertical line drawn from the posterior border of the femoral condyle should lie within 5 mm of the posterior cortex of the adjacent tibia).

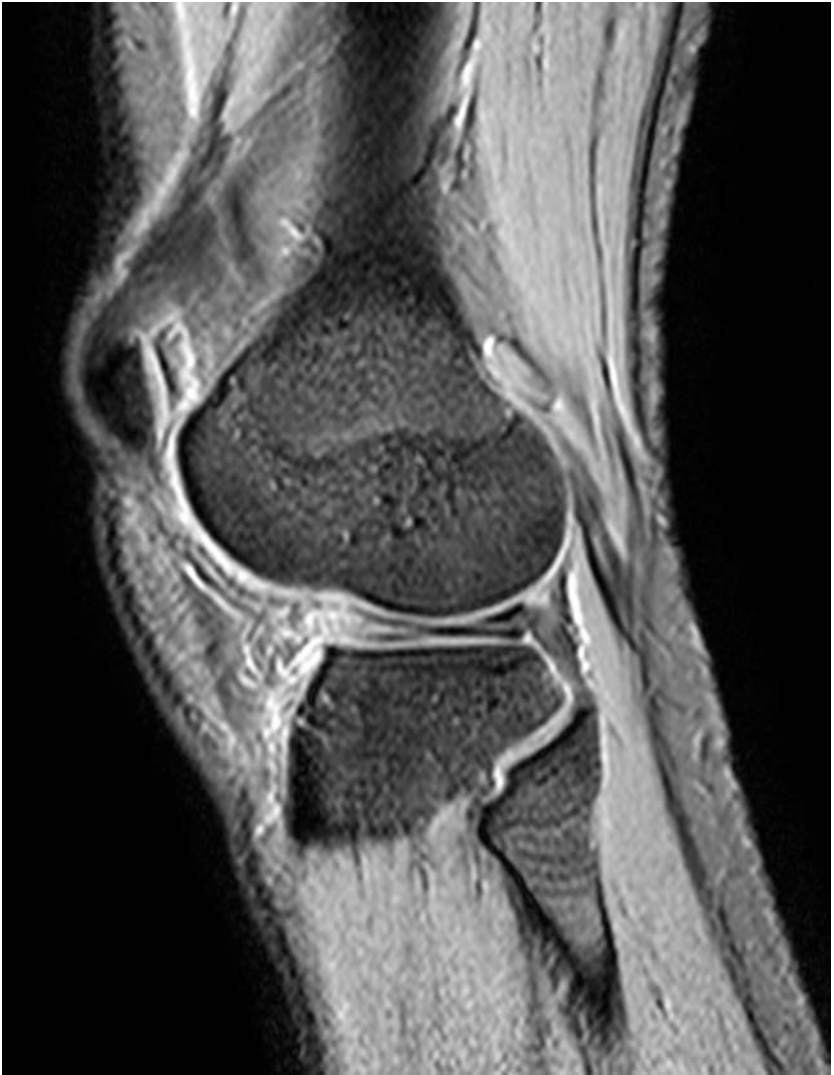

Post-ACL reconstruction. Note the tunnelled screws *in situ*.

- *Knee dislocation*
 - Doppler pulse assessment, reduce as soon as possible.
- *ACL*
 - Traditionally attempt rehabilitation – only reconstructing persistently unstable knees.
 - Majority now being reconstructed – to protect the meniscus and hopefully therefore the articular surface.
 - The earlier the reconstruction, the less the intra-articular damage.
- *PCL*
 - Most treated with rehabilitation alone.
 - Reconstruction for persistent instability.
- *MCL/LCL*
 - Grade I and II – hinged brace and physiotherapy.
 - Grade III – most are repaired early.
- *Meniscal injury*
 - Ideally locked knees require semi-urgent arthroscopy and repair of the meniscus if possible.
 - Chronic meniscal tears require non-urgent arthroscopic partial meniscectomy.



Sagittal gradient T2 MRI: quadriceps tendon rupture (arrows).



Sagittal gradient T2 MRI: horizontal cleavage tear of the lateral meniscus. Linear increased signal is seen within the posterior aspect of the lateral meniscus, extending to the superior articular surface. Note that there is also abnormal signal seen within the anterior aspect.

Metatarsal fractures – commonly fifth MT base

Characteristics

- Common fracture of the lower limb usually after direct trauma or repetitive stress.
- Metatarsal fractures occur at the head, neck, shaft and base
- The majority are managed non-operatively, with POP, hard-soled shoe orthoses, or purely with analgesia and mobilisation.
- Significantly displaced, or angled fractures require MUA ± k-wire and POP, or ORIF
- Fifth MT base fractures fall into two groups – in mechanism, treatment and prognosis. These warrant discussion because of their frequency.
 - *Avulsion fractures* – the commonest form. Secondary to an inversion injury in the plantar flexed foot. Originally thought to be an avulsion fracture at the site of insertion of peroneus brevis, although more recently the lateral band of the plantar aponeurosis has been implicated. The types of injury ranges from a small avulsion to fracture of the entire tuberosity.
 - *Jones' fracture* – Metaphyso-diaphyseal fracture occurring greater than 1.5 cm from the base. More serious than tuberosity fractures. Usually caused by combination of repetitive forces produced during running or jumping.

Clinical features

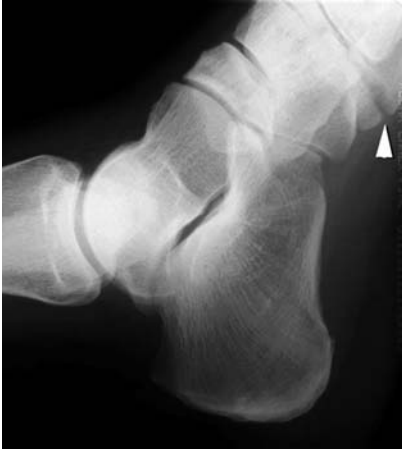- Pain, tenderness and bruising at the fracture site, with painful passive inversion.
- Often presents as an ankle sprain.

Radiological features

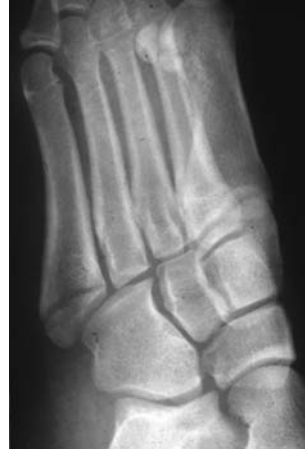- Always look at the base of fifth metatarsal in an ankle view.
- The fracture line is usually transverse.
- Fragment separation may be evident.
- A Jones' fracture occurs distal to the inter-metatarsal joint.
- Do not confuse with the physeal plate in children. The physis has usually closed by age 15.

Management

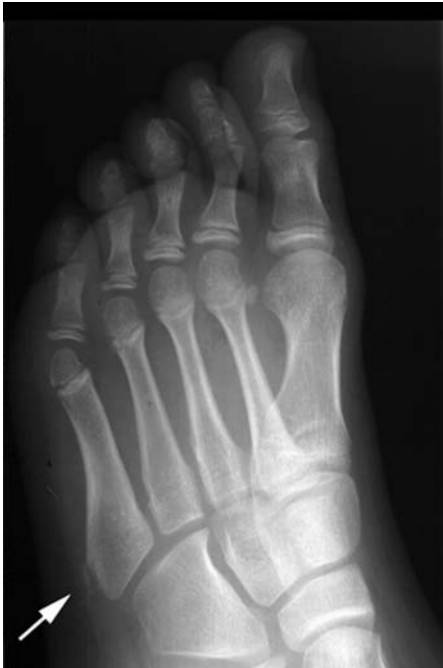- ABCs, assess soft tissues, neurovascular status immobilise with bandage or backslab for a short period to allow pain and swelling to subside, prior to active mobilisation.
- *Avulsion fractures* – treat symptomatically. If pain is slight the patient can usually be discharged with a compression support and advice. If marked pain, a walking plaster is advised for 2 to 3 weeks.



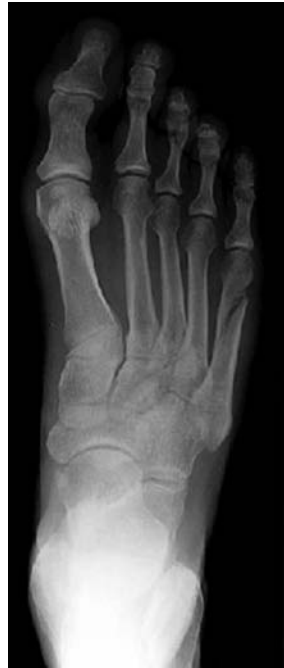Always remember to examine the base of the 5th metatarsal on an ankle X-ray.



Base of 5th metatarsal fracture.



Partial avulsion of the apophysis at the base of 5th metatarsal.



Spiral fracture of the fifth metatarsal.

- *Jones' fracture* – Due to risk of non-union and avascular necrosis, a non-weight-bearing cast for 6 to 8 weeks is usually recommended. In athletes early ORIF is advised because of high recurrence rates and the prolonged rest from training needed.

Lisfranc injury

Characteristics

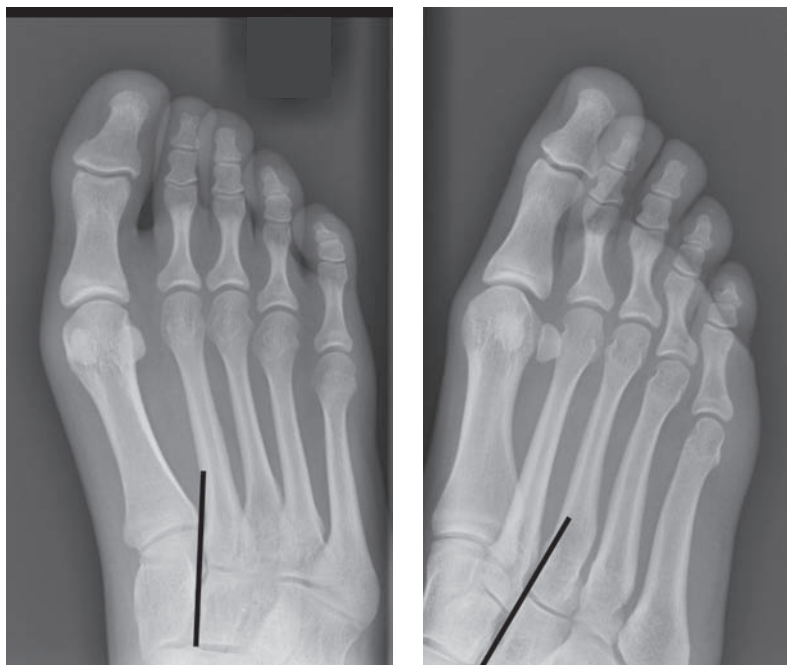- Lisfranc's joint (and historically amputation level) is made up of the tarsometatarsal joints and thus a dislocation or fracture-dislocation of this region is termed a Lisfranc injury.
- **The second metatarsal base acts as a keystone in a mortice between the medial, middle and lateral cuneiforms.**
- The second MT base is held by the strong Lisfranc ligament = plantar oblique ligament between the medial cuneiform and the second MT base. This is ruptured in a Lisfranc injury.
- Mechanism of injury tends to involve a rotational force with a fixed forefoot, axial loading or a crush injury. The force is usually fairly significant
- The majority of injuries are closed.
- Classified as homolateral or divergent
 - *Homolateral* – either total or partial incongruity:
 - the metatarsals are laterally or medially displaced in the same direction
 - in partial incongruous lesions either the great toe MT or the 2–5 MTs are maintained in congruity.
 - *Divergent* – lateral dislocation of two to five with medial dislocation of the first metatarsal.

Clinical features

- Suspect from the history. Beware a patient who complains of a sprained ankle with forefoot tenderness.
- Severe pain ± deformity in the forefoot, with an inability to weight bear.
- Swelling will develop with time.
- Paraesthesia may be present, and with severe soft-tissue injuries, suspect compartment syndrome.

Radiological features

- Methodical assessment of alignment, soft tissues and bony contours are essential.
 - AP view: the medial margin of the base of the second metatarsal should be in line with the lateral margin of the medial cuneiform.
 - Oblique view: the medial margin of the base of the third metatarsal should be in line with the medial margin of the lateral cuneiform.
- AP, oblique and lateral views are useful. The AP view shows alignment and associated fractures (commonly base of second) whereas the lateral is useful to assess dorsal or plantar shift. The oblique view is useful to check tarso-metatarsal alignment.

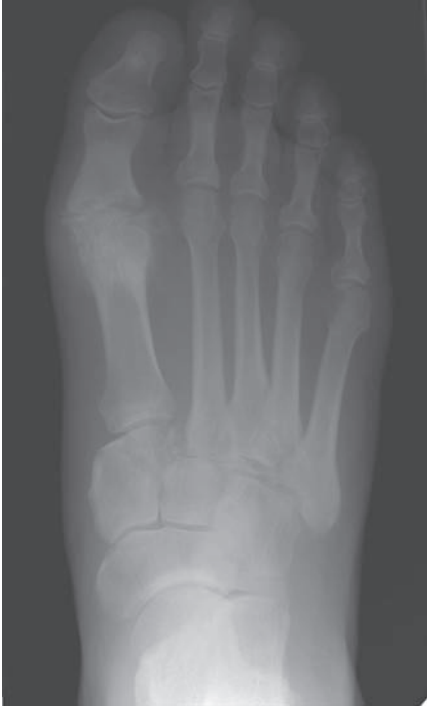

Methodical assessment of alignment is essential. Note the relationship of the second and third metatarsals with the medial and lateral cuneiforms, respectively (see text).

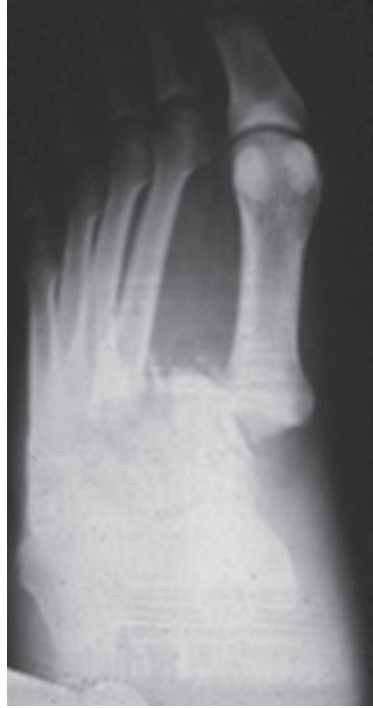- If a fracture is present and alignment appears normal, a spontaneously reduced dislocation may have occurred and stress views should be considered (often under GA).
- If all radiographs are normal and the history and examination are suggestive, a sprain of the Lisfranc ligamentous complex is likely.

Management

- ABCs, assess soft tissues, neurovascular status and immobilise initially.
- Most (>1 mm displacement) require reduction and internal fixation or k-wires.
- Lisfranc ligamentous sprains require a below-knee non-weight-bearing cast and careful follow-up.
- Careful assessment of the foot in the polytrauma patient – frequently missed.



Homolateral Lisfranc's fracture.



Divergent Lisfranc's fracture.

Patella fracture

Characteristics

- Largest sesamoid bone in the body. Forms part of the extensor mechanism of the knee and is held in place by the patellar tendon, quadriceps tendon and the adjacent retinaculæ.
- Classified according to site and appearance – longitudinal, transverse, stellate, marginal, polar or osteochondral fractures.
- Look for ‘sleeve fractures’ in the paediatric population with distal pole injury on lateral radiograph often indicating a significant articular avulsion.
- Usually due to direct force, such as the knee striking the dashboard in a road-traffic accident or a heavy object falling on the knee.
- May also be caused by an indirect force, such as severe muscular contraction. This can also cause patellar tendon rupture, quadriceps tears or avulsion of the tibial tuberosity.
- The commonest fracture is the transverse type resulting from a powerful muscular contraction transmitted to the patella. This type is commonly displaced.

Clinical features

- Suspect from mechanism of injury history.
- Most cases show an inability to extend the knee although this may be preserved by the intact retinaculum.
- Bruising or abrasions, a palpable step at the site of tenderness, or proximal displacement of the patella.
- Beware of associated injuries such as a femoral neck/shaft fracture, femoral-head dislocation and PCL injury.

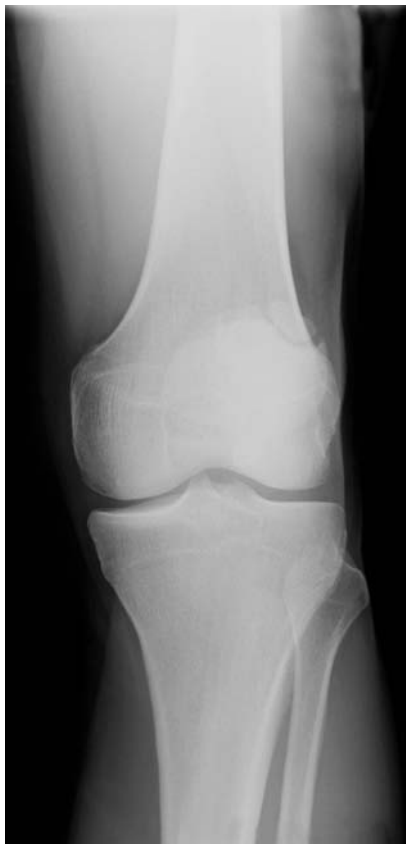Radiological features

- AP and lateral are essential. The skyline view is inappropriate in the acute stage but can be helpful for delayed follow-up.
- The fracture is usually obvious. Look for an associated lipohaemarthrosis on the horizontal-beam lateral.
- Beware the congenital bipartite and multipartite patella; usually occur at the superolateral aspect of the patella. In these the fragments tend to be rounded and corticated as compared to the sharp non-sclerotic margins in a fracture.
- MRI may be useful in subtle cases.

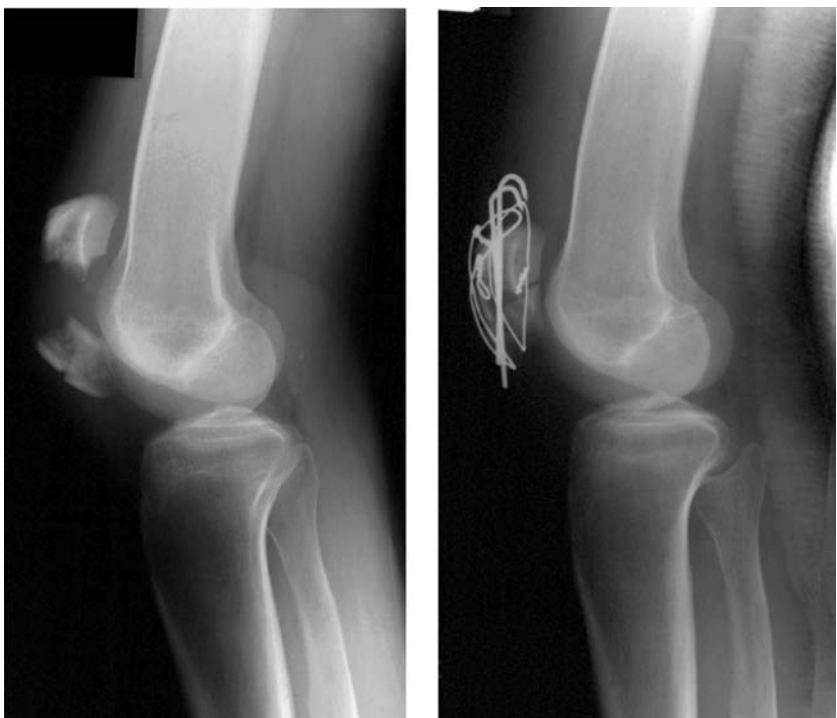
Management

- ABCs, assess soft tissues, neurovascular status and immobilise with backslab.
- *Vertical fractures* – usually undisplaced and stable. Treat with a cylinder cast/locked brace for 4 weeks. There is a trend towards splintage and earlier mobilization.

- *Undisplaced horizontal fractures* – Cylinder cast/locked brace for 6 weeks but follow-up to assess for displacement.
- *Displaced horizontal fractures* – ORIF with tension band technique.
- Partial excision of small avulsion fractures and re-attachment of the extensor tendon with suture anchors.



Congenital bipartite patella at the superolateral aspect of the patella.



Transverse patella fracture pre- and post-internal fixation. Ideally, the figure of '8' wire should be thicker.

Tibial-plateau fracture

Characteristics

- Increasingly seen in the elderly (approx 10% of fractures seen in the elderly).
- Intra-articular injury and thus result in loss of joint congruity.
- Lateral tibial-plateau fractures are most common.
- Beware avulsion fracture of the lateral tibial plateau (Segond fracture) as this is often associated with anterior cruciate injury – *see* soft tissue knee.
- Medial plateau fractures are uncommon and may be associated with lateral ligament ruptures and common peroneal nerve palsy.
- Classified according to Schatzker – types I–VI (see table).
- 50% have a meniscal injury and 30% have an associated ligamentous injury.

Clinical features

- Suspect in a non-weight-bearing patient with history of fall or RTA.
- Bruising, joint effusion, deformity (usually valgus) of the knee.
- The clinical effusion is due to a lipohaemarthrosis and is often tense.
- Always examine and document the neurovascular status as the relatively immobile popliteal vasculature and peroneal nerve can be damaged, especially in bicondylar and medial plateau fractures respectively.
- Further examination under GA (after bony ORIF) to assess ligament damage.

Radiological features

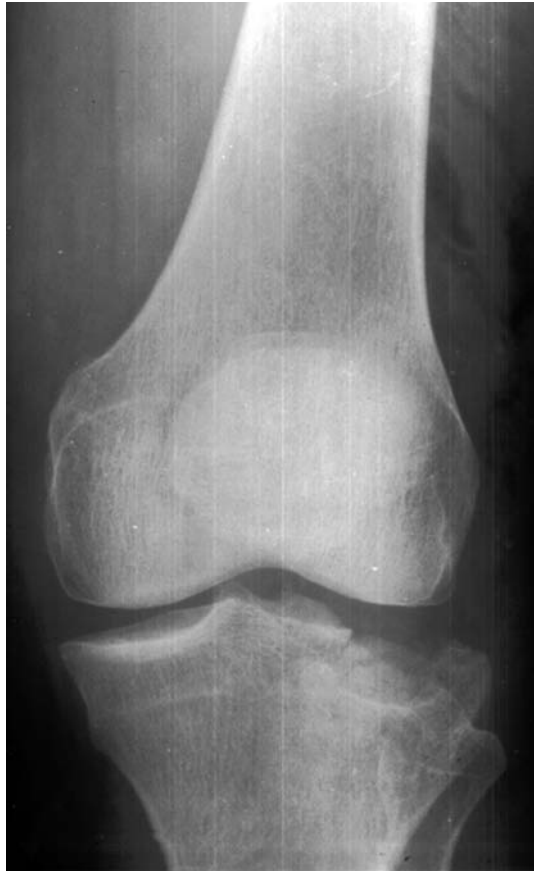- AP and horizontal lateral are usually enough, although a subtle fracture may be revealed on an oblique film.
- Look for a lipohaemarthrosis on the horizontal-beam lateral X-ray.
- Look closely for bony avulsion fragments and widening of the joint space in the unaffected compartment as these are suggestive of associated ligamentous injury.
- CT is useful in planning surgery.
- MRI is useful for soft-tissue information – menisci and ligaments particularly.

Management

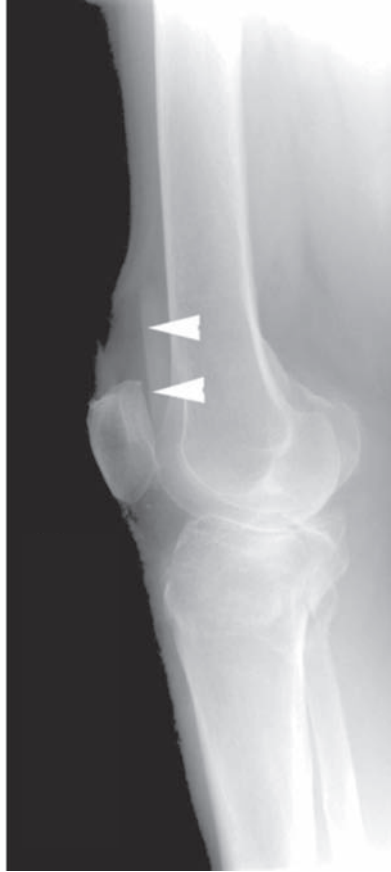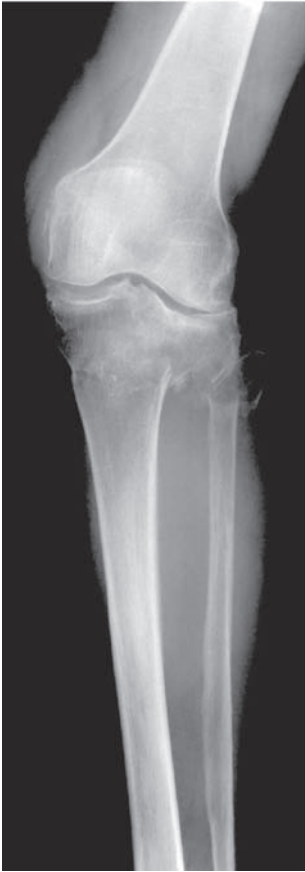- ABCs, assess soft tissues, neurovascular status and immobilise with backslab.
- Non-operative treatment includes immobilisation in plaster followed by hinged cast and rehabilitation – suitable for minimal articular damage particularly in the elderly patient.
- For the majority of displaced fractures, open reduction and internal fixation possibly with arthroscopic assistance is required.
- The aim is to have a congruent joint surface, a stable fracture, and early mobilisation to prevent stiffness.

Schatzker classification of tibial-plateau fractures

Type 1	A simple split involving the lateral tibial plateau
Type 2	Mixed depression and split of the lateral tibial plateau
Type 3	Pure depression of the lateral tibial plateau
Type 4	Any injury purely involving the medial tibial plateau
Type 5	The fracture extends to involve both tibial plateau often in an inverted Y configuration
Type 6	A type 5 fracture with dissociation of the metaphysis and diaphysis



Schatzker type 2 tibial-plateau fracture.



Fracture of the lateral tibial plateau extending into the proximal diaphysis. Note that the second X-ray has been taken as a horizontal beam lateral. This should be viewed as such (turn the page horizontally) so as to avoid missing the lipohaemarthrosis (arrowheads).



Tibial-shaft fractures

Characteristics

- Common long-bone fracture. Often associated with fibular fracture.
- Usually secondary to direct trauma, often high impact.
- Indirect forces (rotation/compression) tend to result in spiral or oblique fractures.
- A toddler's fracture occurs in ambulatory children under the age of three – classically a distal oblique fracture following un-witnessed trauma.
- Midshaft fractures in children raise the suspicion of, but do not always indicate, NAI.
- Associated vascular injuries are rare, but beware compartment syndrome within the initial 24 hours and after subsequent treatments, e.g. nailing or plaster change.

Clinical features

- Pain, swelling and deformity are common – the foot is often rotated.
- Open injury relatively common in tibial-shaft fracture.
- Although vascular injuries are rare, it is important to assess distal pulses.
- 'Foot drop' occurs with common peroneal-nerve damage. Assess sensation in the first dorsal web space of the foot (deep peroneal nerve).
- Ligamentous knee disruption is not uncommon and may be missed.

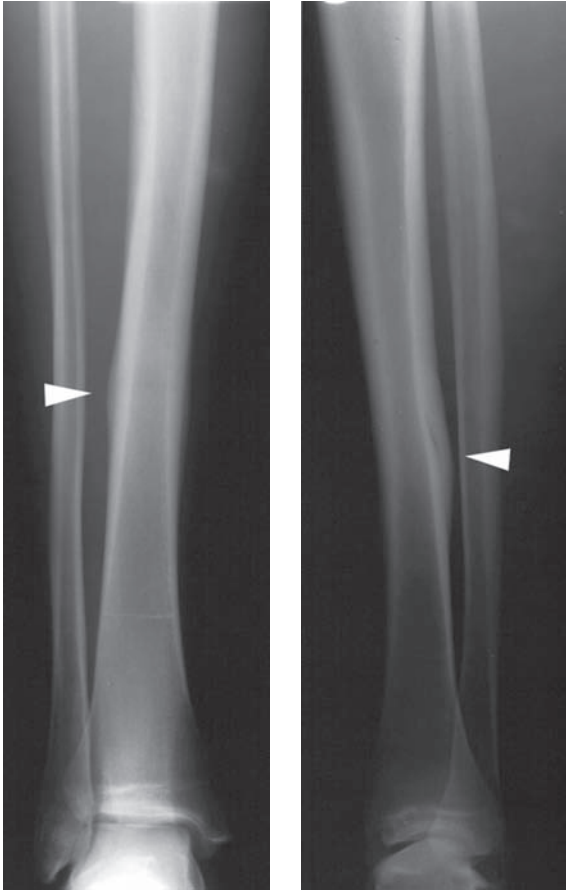
Radiological features

- AP and lateral radiographs should be obtained. Both the knee and ankle should be x-rayed to assess alignment and intra-articular fracture extension.
- Similarly, inclusion of both joints is mandatory post reduction.
- Subtle fractures (e.g. stress fractures) may only be identified at a later time from the periosteal reaction. MRI can be helpful in such cases to make the diagnosis.

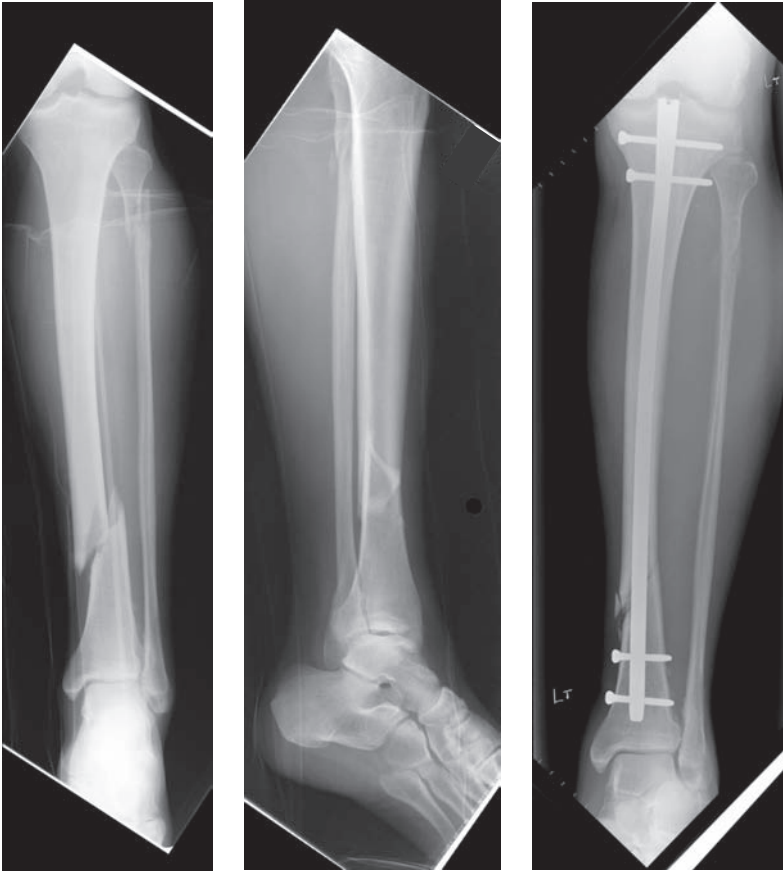Management

- ABCs, assess soft tissues, neurovascular status and immobilise with backslab.
- Analgesia, elevation and observation for compartment syndrome.
- Closed treatment:
 - MUA and split above knee POP:
 - Mainstay of treatment in children and uncomplicated fractures in adults prepared to undergo casting.
 - Conversion to operative treatment if position lost despite wedging techniques with the plaster cast.
 - Sarmiento patellar tendon casting from approximately 3 weeks.
- Operative treatment
 - Intramedullary interlocked nail – allows early mobilisation and weight bearing – particularly for diaphyseal, including open, fractures.

- Flexible intramedullary nails/POP – useful for unstable paediatric fractures.
- ORIF – particularly useful in the metaphyses.
- External fixation – including Ilizarov circular frames – useful in complex cases and poor soft tissues – allows early weight bearing.



Healing stress fracture (arrowheads).



Spiral fracture of the distal third of the left tibia, pre- and post-internal fixation. Note the fibular-neck fracture (associated with common peroneal-nerve injury).

Tibial-plafond (Pilon) fractures

Characteristics

- These are fractures of the distal tibia – close to or involving the articular surface.
- Relatively uncommon injury caused by axial compression (usually high energy falls from a height) or rotational forces (usually lower energy).
- Classified:
 - Ruedi and Allgower:
 - I Pure split fracture – undisplaced.
 - II Displaced but not comminuted.
 - III Comminuted and impacted.
 - AO/OTA:
 - 43A Extra-articular.
 - 43B Partially articular.
 - 43C Complete articular.
- Look for associated injury to head, thorax and abdomen and exclude fractures of vertebrae, os calcis and tibial plateau.

Clinical features

- Pain, swelling and deformity with foot mal-rotation commonplace.
- Sometimes open but almost always with significant soft-tissue injury.

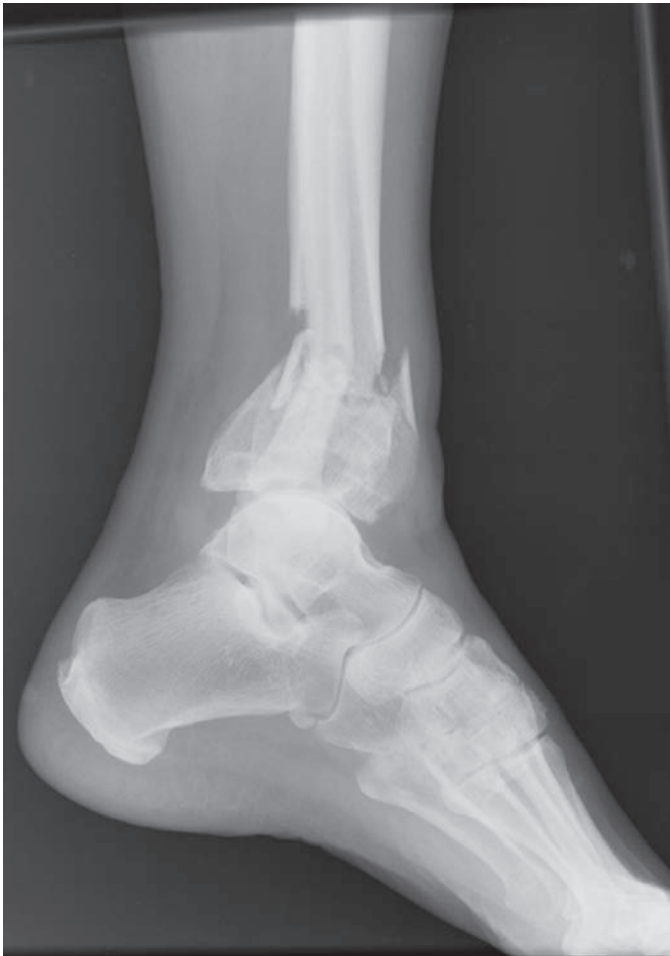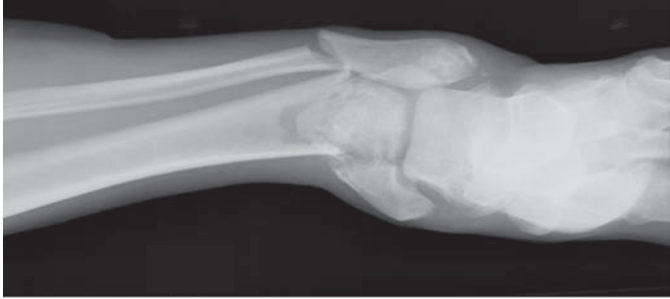Radiological features

- AP mortice of the ankle and lateral radiographs mandatory, and assess proximal extent with AP and lateral X-ray of the tibia.
- Assess the degree of comminution and depression of the distal tibial plafond to classify as above.
- *CT scanning*
 - is useful in the management of these injuries, but is usually more beneficial after the application of a temporary external fixator to bridge the ankle.
 - is the most accurate way of assessing the extent of comminution of the articular surface and orientating the fracture fragments; this aids surgical planning and consideration for ORIF.

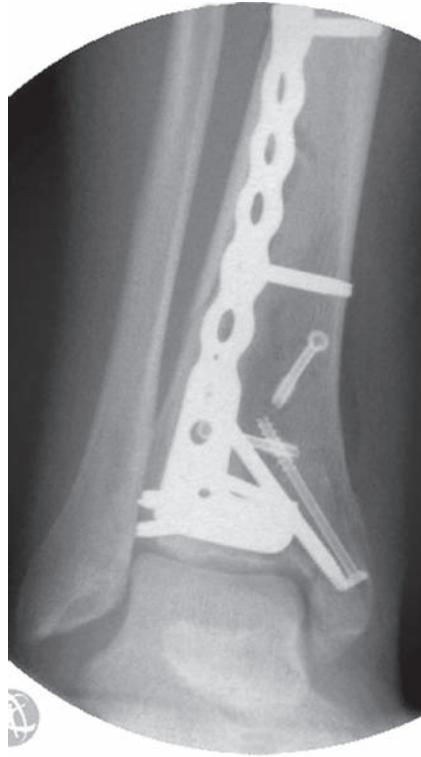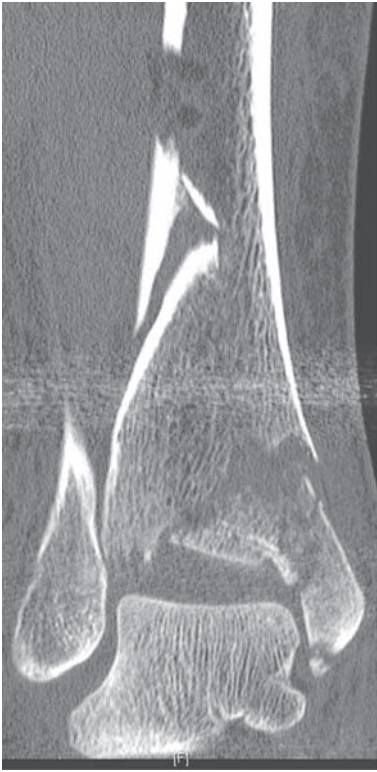
Management

- ABCs, assess soft tissues, neurovascular status, reduce fractures obviously threatening the skin and immobilise with backslab \pm temporary external fixator.
- The majority of these fractures are highly unstable and a backslab will not provide sufficient immobilisation to protect the soft-tissue sleeve from further damage.
- Frequently require a bridging external fixator to cross the ankle providing stability.

- Analgesia, elevation and observation for compartment syndrome, and CT scan.
- Operative treatment – reconstruction when and if the soft tissues permit with ORIF, or in severe cases utilising the Ilizarov technique (usually regional centres).



Left tibial-plafond (pilon) fracture.



Left tibial plafond fracture treated with a bridging ankle external fixator (not shown). Follow-up coronal CT reformat, and subsequent ORIF with an anterolateral locking plate when the soft tissue allowed.

Talus fractures/dislocations

Characteristics

- Uncommon fracture, mostly associated with high energy trauma.
- Talar surface is 60% articular cartilage on account of the three adjacent joints – talar-crural, subtalar and talar-navicular joints.
- Divided anatomically into head, neck, body, lateral tubercle and process fractures.
- Dislocations may be total extrusions of the talus or isolated joint dislocation.
- Talar-neck fractures classified by Hawkins by progressive joint subluxation:
 - I Undisplaced fracture, no joint subluxation.
 - II Displaced – subtalar joint subluxation/dislocation.
 - III Displaced – talar-crural/subtalar joint subluxation/dislocation.
 - IV Displaced – subtalar/talar-crural and talar-navicular dislocation.
- Boyd and Knight classified body fractures:
 - I Vertical – undisplaced (A/B) or displaced (C/D).
 - II Horizontal.
- Significant risk of osteonecrosis (virtually 100% in Hawkins III and IV fractures) because of damaged vascularity – predominantly deltoid artery from the posterior tibial, but with dorsalis pedis contribution from anterior tibial artery.

Clinical features

- Pain, swelling and deformity with foot rotation/angulation commonplace.
- Often open but sometimes closed with significant soft-tissue injury.
- Look for associated injury to head, thorax and abdomen and exclude fractures of vertebrae, os calcis and tibial plateau.

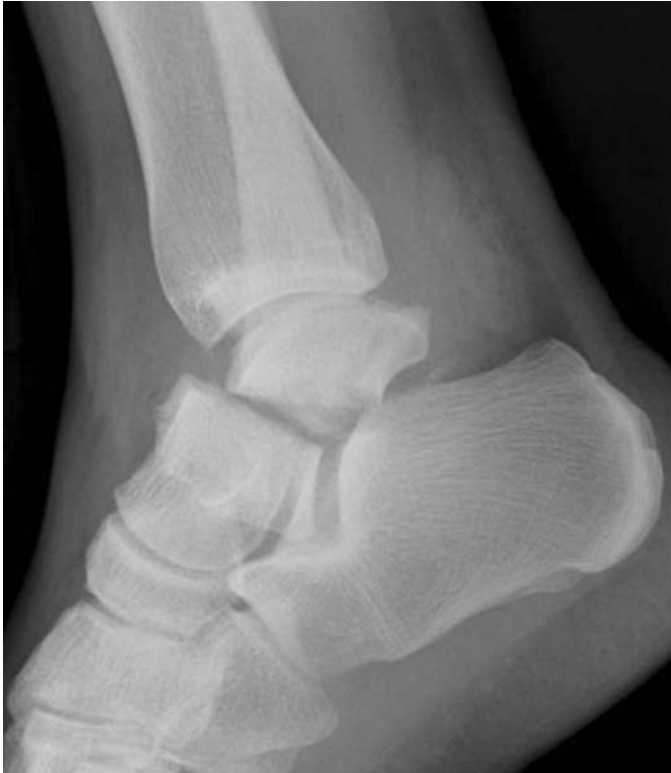Radiological features

- AP mortise and lateral of the ankle and Canale view (pronated, equinus foot with 15° cephalad tilt) to show the talar neck.
- CT once again is useful in the surgical planning of ORIF.
- Hawkins' sign – a good prognostic indicator of revascularization and talar viability – is seen as radiolucency at 6–8 weeks post-fracture, on the AP radiograph.

Management

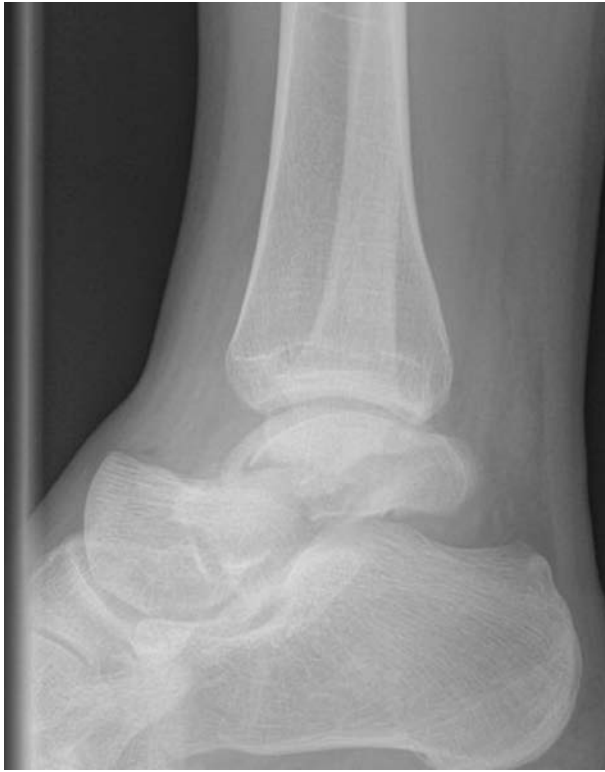- ABCs, assess soft tissues, neurovascular status, reduce fractures/dislocations obviously threatening the skin and immobilise with backslab.
- Hawkins I fractures are generally managed non-operatively – with 6 weeks POP.
- Hawkins II–IV requires emergency reduction and usually simultaneous ORIF.

- Watch for avascular necrosis and post-traumatic arthrosis (<50% in the subtalar joint).
- Body fractures generally require ORIF to allow early mobilisation.
- Process and tubercle fractures are usually managed non-operatively.

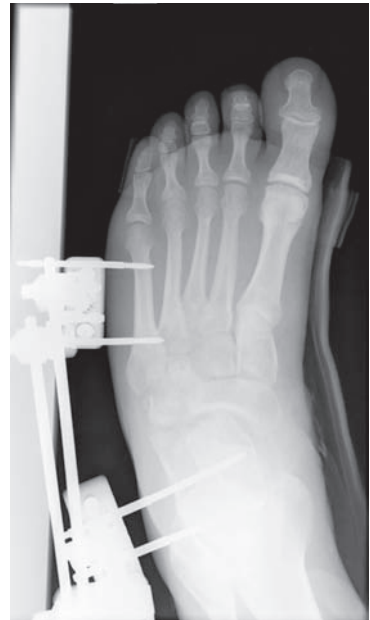
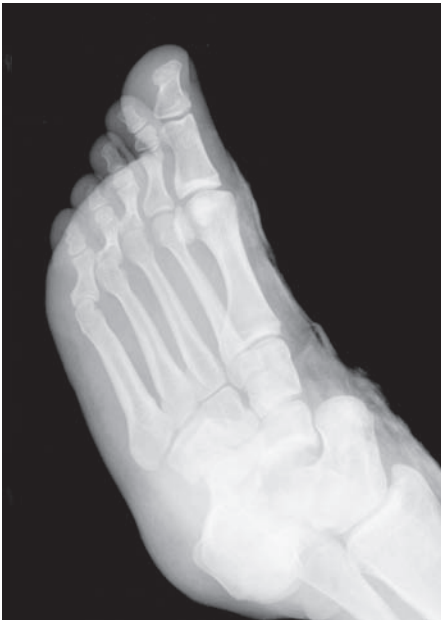
Vertical fracture of the body of talus.





Comminuted talar fracture.



Talonavicular dislocation: reduced and stabilised with an external fixator.

Tarsal fractures and toe phalangeal injury

Characteristics

- Diverse group of injuries – note metatarsal/Lisfranc section above.
- Navicular fractures are divided into four types – dorsal lip (avulsion), tuberosity, body and stress fractures.
- Cuboid injury is usually undisplaced fracture which responds well to hard-soled shoe orthoses. Beware of the ‘Nutcracker fracture’, a high energy abduction injury, crushing the cuboid, shortening the lateral column and potentially extruding the cuboid. This requires ORIF usually.
- Cuneiform injury is rarely isolated and responds to POP immobilisation unless significantly displaced when ORIF is the normal treatment.
- Most phalangeal fractures occur in the proximal phalanx of the fifth toe following indirect trauma – stubbing of the toe.
- Metatarsophalangeal and interphalangeal dislocations should be reduced as soon as possible but rarely require surgery unless open injuries.

Clinical features

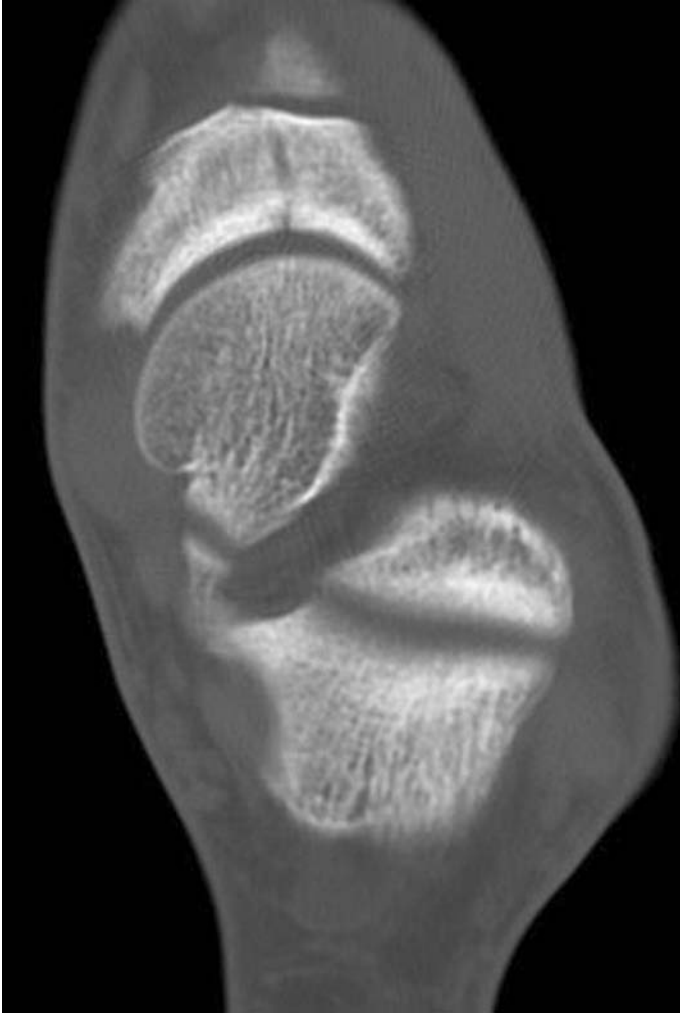
- Pain, swelling and sometimes deformity.
- Careful identification of the most tender area will be particularly beneficial when assessing the X-ray.
- Foot compartment syndrome must be suspected in a painful swollen foot and tested for by passively stretching the muscles of the relevant compartment.

Radiological features

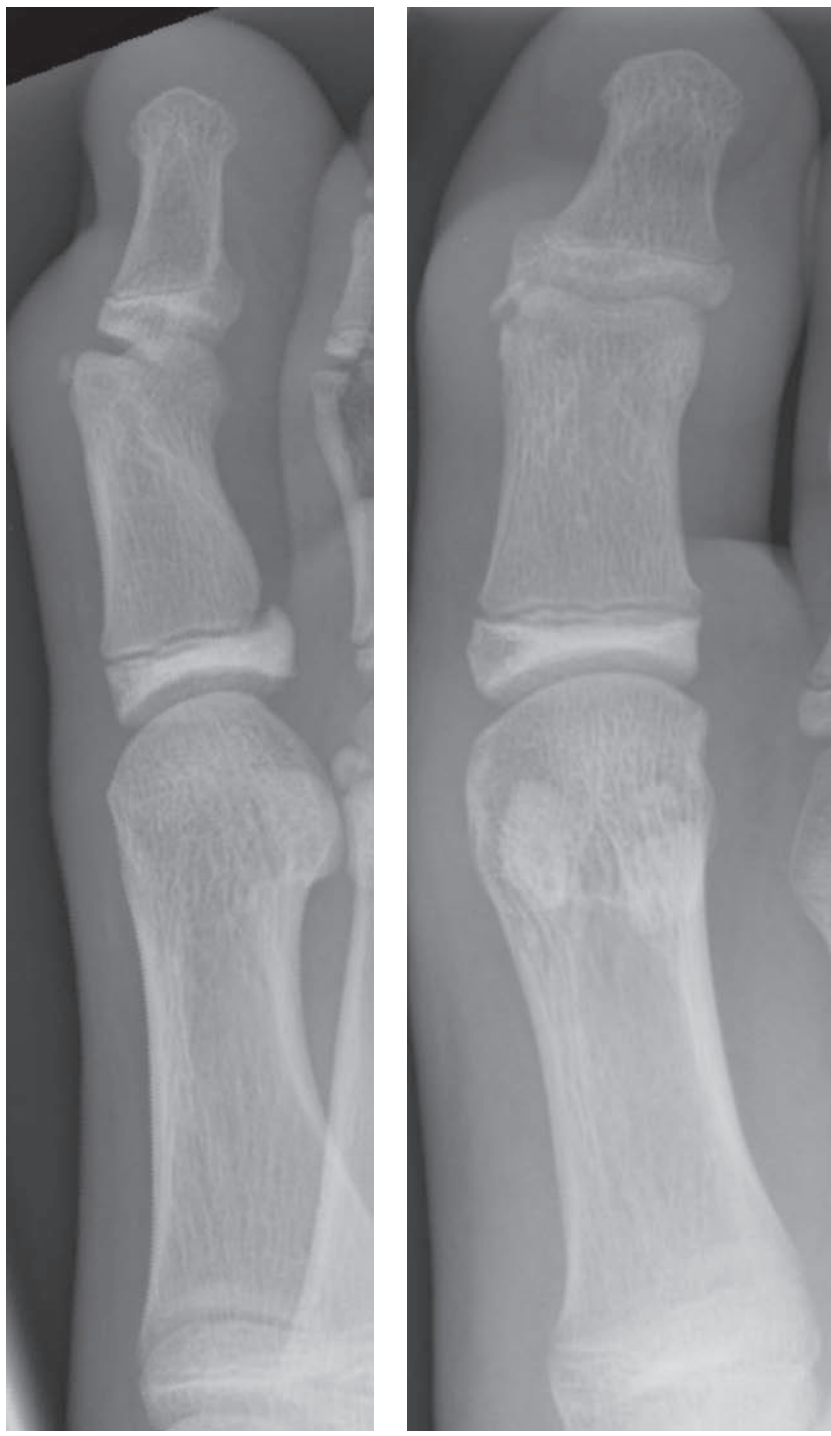- AP and lateral X-rays centred on the area of tenderness are essential.
- Look for significant angulation, intra-articular steps and joint subluxation.
- If there is doubt regarding fracture extent or joint congruity then CT scanning is extremely helpful.

Management

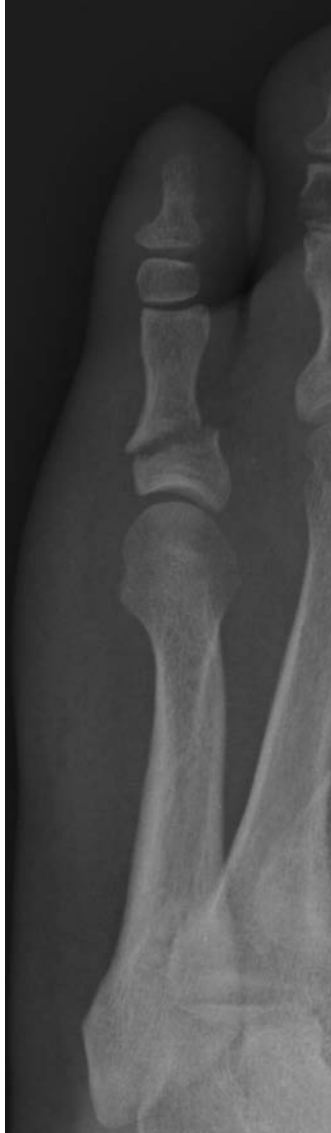- ABCs, assess soft tissues, neurovascular status, reduce fractures/dislocations obviously threatening the skin and immobilise with backslab.
- Admit, elevate and assess for compartment syndrome in the severely injured foot even without fractures.
- General trauma principles apply such that joint congruity must be restored, either following joint dislocation or in intra-articular fractures.
- Navicular body fractures usually require ORIF.
- Nutcracker cuboid fractures are normally treated with ORIF and bone graft.
- Most phalangeal fractures are managed with buddy strapping and mobilisation ± manipulation under ring block for significant angulation.



High-resolution CT of the tarsal bones demonstrating a stress fracture of the navicular.



Avulsion fracture of the head of the proximal phalanx of the great toe.



Fracture of the base of the proximal phalanx of the little toe.